

Platelet rich fibrin used in the regeneration of intraosseous defect in aggressive periodontitis patient – A case report

Nilofar Badshah Attar^{1*}, Mangesh B. Phadnaik², Shivani Sachdeva³, Shital Patil⁴, Smita Khadse⁵

^{1,3}PG Student, ²Associate Professor, Dept. of Periodontology, ^{4,5}PG Student, Dept. of Oral Pathology, Govt. Dental College & Hospital, Aurangabad, Maharashtra

***Corresponding Author:**
Email: nilo_attar@yahoo.com

Abstract

Introduction: Platelet rich fibrin (PRF) is a fibrin matrix made of platelets, cytokines and growth factors. It releases growth factors essential for regeneration for healing.

Case Report: PRF was obtained by a simple process from a generalized aggressive patient. PRF obtained was placed in the intraosseous defect during open flap debridement. This case presents regeneration of intraosseous defect by adjunctive use of along with PRF open flap debridement. A follow up of one year showed reduction in clinical probing depth, gain in clinical attachment and increase in radio density on post operative radiograph.

Conclusions: The healing of periodontal defect observed as there was gain of clinical attachment. The potential of PRF in periodontal surgery for regeneration of intraosseous defects in aggressive periodontitis patient should be further studied.

Keywords: Platelet rich fibrin, Intraosseous, Aggressive periodontitis

Introduction

Periodontal regeneration is the ultimate goal of periodontal therapy. Varied types of bone regenerative materials had been implanted into osseous defects for regeneration. Platelet concentrates such as platelet rich plasma and platelet rich fibrin which releases growth factors can be supplemented at the healing site for regeneration.

Platelet rich fibrin (PRF) is a new second generation of platelet concentrate. PRF is used to promote wound healing, graft stabilization and bone regeneration. The fibrin matrix of PRF directs stem cell migration and promotes healing.

The preparation of PRF is simple and does not require heavy cost. The patient own blood is used to prepare the PRF which is acceptable to many patients. The mechanism of PRF in regeneration of aggressive periodontitis is same as in chronic periodontitis. There is very scarce literature of use of PRF in regeneration of periodontal defects with aggressive periodontitis patients.

Aggressive periodontitis patients have classical intraosseous defect which is detected with radiographs. The regeneration of such intraosseous defect provides a huge challenge to the clinician. Hence, the following case report presents the successful use of PRF with open flap debridement in periodontal regeneration in a generalized aggressive periodontitis (GAgP) patient.

Case Report

A 29 year old male patient reported with complaint of discharge from lower anterior region. Detailed history of patient was taken. Patient had undergone root canal treatment in the 31 and 41 one year back. The tooth was asymptomatic with deep periodontal pocket. Clinical examination had revealed deep periodontal defect with minimal plaque. Orthopantomogram showed

vertical bone loss and arch shaped defect with incisors, premolars and molars. On the basis of clinical and radiographic examination diagnosis of generalized aggressive periodontitis was made. Clinically pocket depth of 10 mm was present in respect to 31 (Fig. 1) while intraoral radiograph showed an intraosseous defect. (Fig. 2)

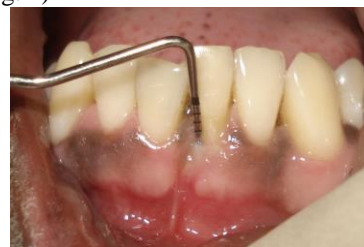

Fig. 1: Pre-operative photograph showing 10 mm periodontal pocket depth with 31

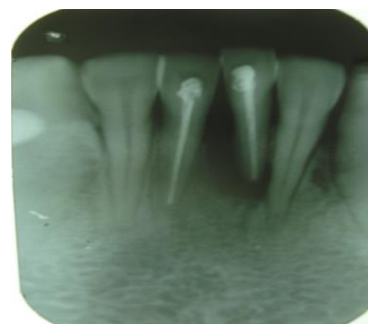


Fig. 2: Pre-operative radiograph showing extensive bone loss with 31 & 41

Patient informed consent was taken and treatment was initiated. The periodontal flap was elevated with respect to 31 and 41 region. A two walled defect was found in respect to 31 on surgical exploration. The defect was completely debrided (Fig. 3). Patient blood was derived and immediately transferred into test tube.

The test tube was placed into centrifugation machine and centrifuged at the 3000 revolutions per minute (rpm) for 10 min. The test tube showed supernatant plasma, platelet concentrate and red blood cells at the bottom. The platelet rich fibrin (PRF) obtained was then placed in the defect (Fig. 4). The healing was uneventful. A follow up of 6 months showed reduction in clinical probing depth and increase in radio density on the post operative radiograph suggestive of regeneration (Fig. 5, 6).

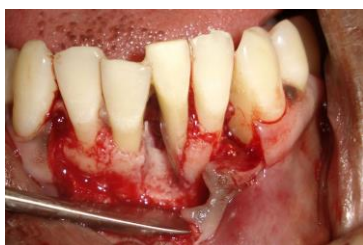

Fig. 3: The periodontal flap elevated & the intrabony defect debrided with 31 & 41

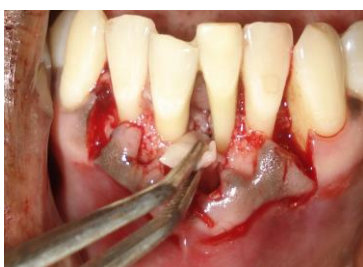

Fig. 4: PRF placed in the defect

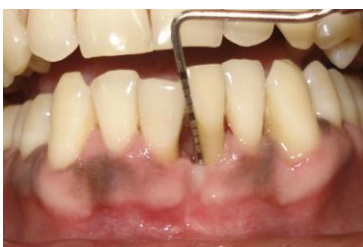

Fig. 5: One year post-operative photograph showing 3 mm healthy sulcus and gingival recession

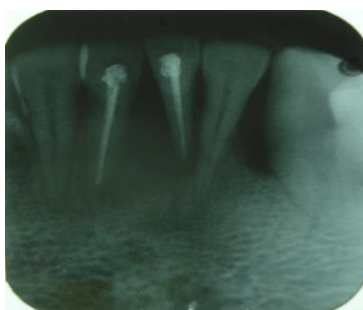

Fig. 6: One year post-operative radiograph with increase radioopacity with 31 suggestive of regeneration

Discussion

The ultimate goal of periodontal therapy is the regeneration of periodontal hard and soft tissues, i.e. the bone, cementum & gingiva, periodontal ligament. The use of biologically active regenerative materials such as enamel matrix derivative (EMD), platelet derived growth factor (PDGF), P-15, platelet rich plasma for periodontal regeneration had been documented in the past.⁽¹⁾ Platelet rich plasma when used along with bone graft obtained significant bone filling in the periodontal defect. It requires mixing with calcium chloride and thrombin and then transferred into the intraosseous defect.⁽²⁾

PDGF and Transforming growth factor (TGF- α) promote periodontal regeneration by cell growth and differentiation. These platelets are a natural source of PGFs and are involved in the wound-healing process. A simplest method to obtain autologous PDGF and TGF- α is the use of PRF that can be easily prepared from patient's own blood by centrifugation.⁽³⁾

Dohan D.M. et al.⁽⁴⁾ and his associates were the pioneers for using platelet rich fibrin (PRF) in oral and maxillofacial surgery to improve bone healing in implant dentistry. Platelet rich fibrin (PRF) is a fibrin matrix in which platelet cytokines, growth factors and cells are trapped which is later released at the healing site. Dohan D.M.⁽⁵⁾ proved a slower release of growth factors from PRF than PRP and observed better healing properties with PRF. The procedure to obtain platelet rich plasma is more complex than preparation of PRF. Thus, there are definite advantages of PRF over PRP.

Anilkumar K. et al.⁽⁶⁾ have reported successful coverage of gingival recession in mandibular anterior teeth with combined laterally positioned flap technique and PRF membrane.

Sharma A. et al.⁽⁷⁾ in randomized controlled clinical trial of three wall intrabony defects in patients with chronic periodontitis obtained greater bone fill at sites treated with PRF and conventional open-flap debridement compared to conventional open-flap debridement alone.

Pradeep A.R.⁽⁸⁾ in patients with chronic periodontitis concluded that the treatment of three wall intrabony defects with PRF resulted in significant improvements in clinical parameters. PRF when combined with hydroxyapatite significantly increased the regenerative effects in the intraosseous defects.

Management of intraosseous defect in aggressive periodontitis patients provides a huge challenge to the clinician. The presence of residual pockets after the conventional periodontal therapy leaves behind a susceptible area for attachment loss. Thus there is ongoing research in the field of regeneration to achieve the desired goal of complete regeneration.

Desarda H.M. et al.⁽⁹⁾ reported two cases of surgical reconstructive therapy with placement of PRF in angular defects of GAgP patients. These cases showed that PRF with periodontal surgery in angular

defect of aggressive periodontitis patient can be an effective approach to enhance the periodontal regeneration.

Nanditha S. et al.⁽¹⁰⁾ has successfully shown regeneration with PRF and bone graft in two walled and three walled defect with respect to 31 and 46 of localized aggressive periodontitis patient.

In this case report, PRF was placed in the intrabony defect of generalized aggressive periodontitis patient. The successful regeneration of bone was seen clinically as gain in clinical attachment and increased radiodensity on one year radiograph. This case report highlights the utilization of PRF as a potential agent with open flap debridement in regeneration of periodontal defect. PRF played an essential role in regeneration of the intrabony defect in this case. The benefit of utilization of PRF for regeneration of defects in aggressive periodontitis patients is pivotal. These may help us solve the age-old problem of tackling the critical condition and compromised situation in many aggressive patients. Thus, PRF should be further studied for its wider application in the field of regeneration.

Conclusion

PRF can be easily derived with the simple uncomplicated procedure. It aids in regeneration of bone. This case report highlights the successful regeneration of bone in intrabony defect in generalized aggressive periodontitis patient. Thus, PRF use in regeneration of periodontal defects should be advocated. The use of PRF in regeneration of periodontal defects in aggressive periodontitis patients is a judicious effort for maintenance of periodontal health.

However, the successful regeneration was not confirmed histologically. Further clinical studies needs to be carried out to establish the potential of use of PRF in regeneration of periodontal defects in aggressive periodontitis patient.

Conflict of Interest

“No potential conflict of interest relevant to this article was reported”.

Acknowledgements

No Financial support was taken from any institutions, pharmaceutical and device manufacturers, private companies, and intramural departmental sources.

References

1. Ivanovski S. Periodontal regeneration. *Australian Dent J* 2009; 54: 118–28.
2. Jeong KI, Kim SG. Use of platelet-rich fibrin in oral and maxillofacial surgery. *Maxillofacial Plastic and Reconstructive Surg.* 2012; 34:155-61.

3. Giannobile WV, Somerman MJ. Growth and amelogenin-like factors in periodontal wound healing: a systematic review. *Ann Periodontol* 2003;8:193-204.
4. Dohan, DM and Choukroun J. PRP, cPRP, PRF, PRG, PRGF, FC. How to find your way in the jungle of platelet concentrates? *Oral Surg Oral Med Oral Path Oral Radio and Endodontology* 2007;103:305-06.
5. Dohan E, Peppo DM, Doglioli P, Sammartino G. Slow release of growth factors and thrombospondin-1 in Choukroun's platelet-rich fibrin (PRF): a gold standard to achieve for all surgical platelet concentrates technologies. *Growth Factors* 2009;27:63-69.
6. Anilkumar K, Geetha A, Umasudhakar TR, Vijayalakshmi R, Pameela E. Platelet-rich-fibrin: A novel root coverage approach. *J Indian Society Periodontol* 2009;13:50-54.
7. Sharma A and Pradeep A. Treatment of 3-wall intrabony defects in patients with chronic periodontitis with autologous platelet-rich fibrin: a randomized controlled clinical trial. *J Periodontol* 2011;82:1705-12.
8. Pradeep AR, Bajaj P, Rao NS, Agarwal E, Naik SB. Platelet-rich fibrin combined with a porous hydroxyapatite graft for the treatment of three-wall intrabony defects in chronic periodontitis: a randomized controlled clinical trial. *J Periodontol* 2012;61:1-8.
9. Desarda HM, Gurav AN, Gaikwad SP and Inamdar, SP. Platelet rich fibrin: a new hope for regeneration in aggressive periodontitis patients: report of two cases. *Indian J Dent Res* 2013;24:627-30.
10. Nanditha S, Muthusamy S, Chandrasekaran S, Kannan S. A Judicious Treatment Approach for the Management of Localized Aggressive Periodontitis: A Case Report. *J Interdiscipl Med Dent Sci* 2015;3:172-74.