

Autogenous chin graft and guided bone regeneration (GBR) in localized ridge augmentation - A case report

Deepa D^{1*}, Mrinalini Agarwal Bhatnagar², KV Arunkumar³, Pratik Bhatnagar⁴

¹Professor, ²PG Student, Dept. of Periodontology, ³Professor, Dept. of Oral & Maxillofacial Surgery, ⁴Senior Lecturer, Dept. of Prosthodontics, Subharti Dental College, Meerut, Uttar Pradesh

***Corresponding Author:**

Email: deepa_arun@rediffmail.com

Abstract

Introduction: Alveolar ridge defects resulting from tooth extraction, trauma, or periodontal disease often require surgical correction prior to prosthetic reconstruction. Posterior ridge deficiencies are challenging defects to treat. Therefore, augmentation of deficient alveolar ridges is an important aspect regardless of whether implants or conventional fixed prosthetic treatment is being planned. Several techniques have been used to augment the bone volume, including bone grafts from extra oral and intraoral sites, guided bone regeneration with bio-resorbable or non-resorbable membrane and alveolar distraction osteogenesis.

Materials and Method: This case report describes the management of a localized maxillary posterior alveolar ridge defect. The deficient site was augmented using autogenous particulate chin graft along with placement of bio-resorbable membrane-Sybograf-GBR (Guided bone regeneration). Pre-operative radiograph was taken to assess ridge deficiencies in the edentulous areas.

Results and Conclusion: Six months post-operative clinical and radiographic examination revealed a significant increase in height and width of alveolar ridge in the edentulous area.

The results showed that combined treatment modalities using autogenous chin graft and GBR membrane is beneficial for the treatment of localized posterior alveolar ridge defects.

Keywords: Autogenous graft, Collagen membrane, Guided bone regeneration, Guided tissue regeneration, Ridge augmentation.

Introduction

The alveolar ridge undergoes accelerated bone loss within six months of tooth loss.⁽¹⁾ Tooth loss due to extraction, periodontal disease or trauma result in unavoidable loss of bone height and width and may compromise the outcomes of any prosthetic reconstructions. Resorption of buccal bone occurs at a faster rate when compared to lingual and palatal plates because of loss of bundle bone.⁽²⁾ Success of implant surgery does not merely depend upon achieving osseointegration but also on the establishment of an ideal base for implant supported prosthetic restorations. Inadequate bone volume is a major contraindication for dental implant placement. Based on clinical experience, the minimum dimensions in the maxilla to insert a dental implant are an alveolar ridge width of 5 mm and a bone height of 10 mm. Any deficit in these dimensions predisposes the risk of placement in anatomically unfavorable positions and thus leading to implant failure.⁽³⁾ Therefore, various surgical techniques have been employed to augment the bone volume. Ridge augmentation techniques include the use of bone grafts, guided bone regeneration with bio-resorbable or non-resorbable membrane, alveolar distraction osteogenesis and ridge splitting.⁽⁴⁾

Owing to its osteogenic, osteoconductive and osteoinductive properties, the autograft is considered as the gold standard of bone transplantation. Autografts could be taken from either extraoral (iliac crest) or intraoral (ramus, mandibular symphysis, edentulous ridge) sites. Due to patient morbidity and discomfort,

intraoral autograft is the choice of treatment for ridge augmentation.⁽⁵⁾

Guided bone regeneration is based on the concept of guided tissue regeneration by Nymann et al. This procedure utilizes resorbable or non-resorbable barrier membrane for space creation and maintenance.⁽⁶⁾ Non-resorbable expanded polytetrafluoroethylene membranes (e-PTFE) have been used extensively since the 1980s for GBR. However, this material exhibited various shortcomings like frequent exposure of the membranes, need for an additional surgery, and the exposure of the newly regenerated bone to resorptive conditions after removal of membrane.⁽⁷⁾ To overcome these drawbacks, resorbable collagen membranes were introduced which are advantageous, as they permit one-step surgical placement, are well accepted by host and have a reasonably good manipulative consistency.⁽⁸⁾ These membranes, however, lack rigidity of e-PTFE membranes resulting in collapse and thus limiting regeneration. Therefore GBR membranes are commonly used along with bone grafts that provide support to the membrane.⁽⁹⁾

This article presents a case report of localized alveolar ridge augmentation in maxillary posterior edentulous region using particulate autografts harvested from the mandibular symphysis in conjunction with sterile hydroxyapatite resorbable membrane, Sybograf™-GBR.

Case Report

A 55 year old male reported to the outpatient department (OPD), department of Periodontology, Subharti Dental College and Hospital, Meerut, Uttar Pradesh seeking replacement for his missing teeth in maxillary left posterior tooth region. The patient gave history of extraction of grossly decayed left maxillary first molar one year back and had been using removable partial denture since then. The patient was in good health with non-contributory medical history.

Clinical and radiographic examination revealed severe horizontal and vertical ridge resorption of the edentulous site (Fig. 1, 2). Bone height & width i.r.t 26 was 4mm and 3mm respectively, which was inadequate for prosthetic reconstruction. Hence, vertical and horizontal ridge augmentation using autogenous particulate chin graft alongwith GBR (Sybograft™ - GBR, Eucare Pharmaceuticals Pvt. Ltd., Chennai, India) was planned. The complete treatment plan was discussed with the patient and a duly signed consent form was obtained.

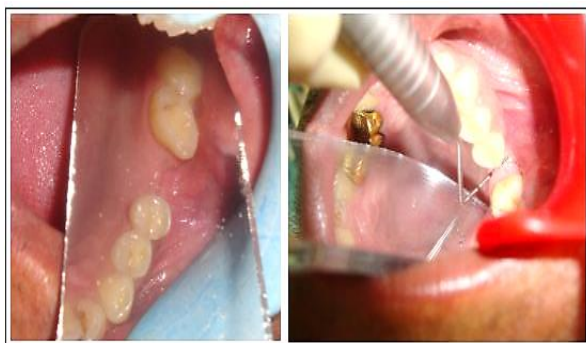

Fig. 1: Pre-operative clinical view of localized alveolar ridge deficiency #26

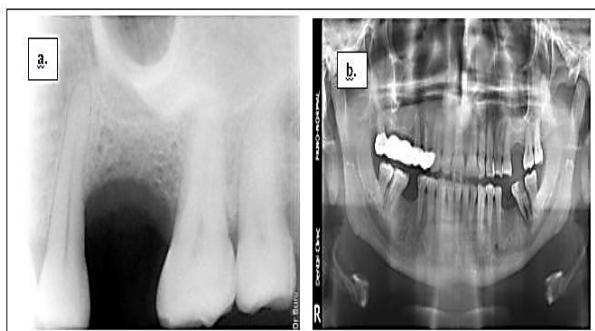


Fig. 2: Pre-operative radiographic examination (a) Pre-operative RVG #26, (b) Pre-operative OPG

Pre-Surgical preparation: The patient underwent phase I therapy which included scaling and root planning, followed by oral hygiene instructions. After the phase I therapy, patient was recalled for surgery.

Surgical procedure: Surgical procedure was performed under proper aseptic precautions to keep the surgical site clean. Pre-operative decontamination of

oral cavity with 0.2% chlorhexidine mouth rinse for 1 minute and perioral skin disinfection with 5% povidone iodine solution was done. The surgical procedure was performed under local anesthesia (2% Xylocaine® Dental with 1:80,000 adrenaline). Surgical access was through mid crestal incision, and an intrasulcular buccal incision at the adjacent teeth including vestibular divergent releasing incisions. Full thickness flap was reflected to expose the alveolar bone (Fig. 3). All fibrous tissue was removed from the recipient site and perforations were made into the marrow spaces using surgical burs to improve vascularization and incorporation of the graft.

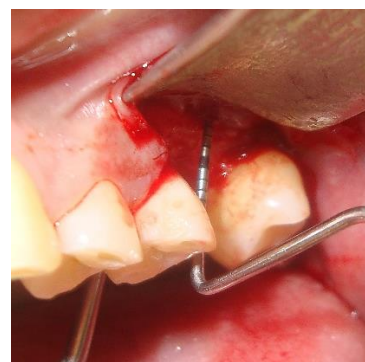


Fig. 3: Incision & flap reflection at recipient site

Harvesting of chin graft: The donor site selected was the mandibular symphysis region. Autogenous bone graft was harvested, using a trephine bur #5 in the form of small cylindrical blocks, and then particulate using bone miller (Fig. 4, 5). The particulate graft mixed with patient's blood was condensed on the deficient edentulous site and the area was covered with GBR membrane, Sybograft™ - GBR (Eucare Pharmaceuticals Pvt. Ltd., Chennai, India) (Fig. 6). Sutures were placed at recipient and donor site to obtain a tension free closure of the soft tissues (Fig. 7).

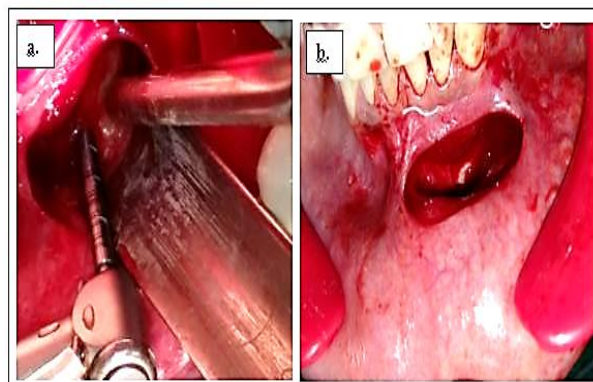


Fig. 4: Mandibular symphysis (donor site) (a) Graft harvesting using trephine (b) After graft harvesting

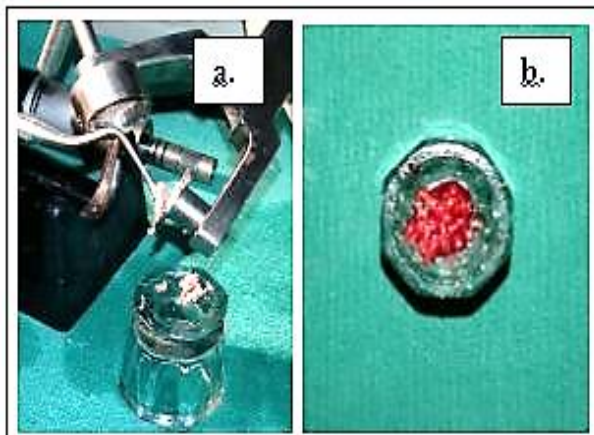


Fig. 5: (a) Particulate bone graft using bone miller, (b) Autogenous particulate graft mixed with patient's blood

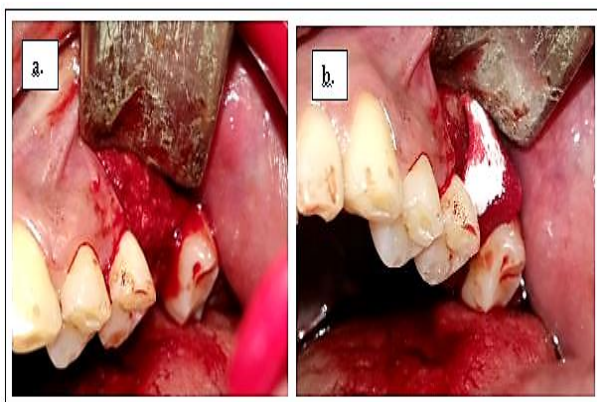

Fig. 6: (a) Placement of particulate graft at recipient site, (b) Placement of GBR membrane over the graft

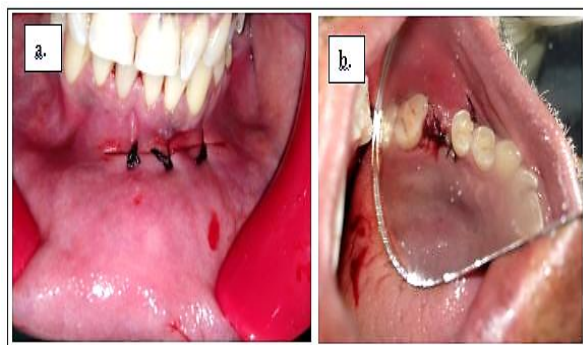


Fig. 7: (a) Sutures placed at donor site, (b) Suture placed at recipient site

Amoxicillin plus clavulanic acid 625 mg b.d. for 5 days, ibuprofen 400 mg t.d.s for 5 days and 0.2% chlorhexidine mouth rinse b.d. for 1 week was prescribed postoperatively. The patient was instructed to avoid brushing and trauma to the surgical site and to avoid smoking for a few days post surgery. Patient was recalled for suture removal after 15 days. The post-operative follow up at 15 days, 3 months and 6 months

showed uneventful healing at both the recipient and donor sites. The clinical and radiographic examination at 6 months showed a gain of 2 mm and 3 mm in vertical and horizontal ridge dimension respectively. (Fig. 8)

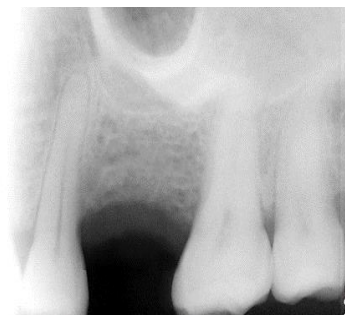

Fig. 8: Six month post-operative RVG (radiovisuography) demonstrating improvement in ridge dimensions #26

Discussion

Ridge augmentation procedures are indicated in case of inadequate height and width of alveolar ridge prior to conventional fixed prosthodontics or implant therapy. Alveolar ridge deformities are classified according to morphology and severity.^(10,11) Various techniques depending upon the extent of defect have been employed for predictable bone augmentation. These techniques include; grafting procedures, distraction osteogenesis, bone splitting and guided bone regeneration.⁽⁴⁾ The present case had severe ridge resorption due to loss of left maxillary molar and long term wear of removable partial dentures. Therefore, ridge augmentation using particulate chin graft in conjunction with guided bone regeneration was planned.

Bone grafting procedures for ridge augmentation utilize either autografts, allografts, xenografts and alloplasts alone or in combination.⁽¹²⁾ Autogenous graft is considered as the gold standard for bone transplantation and various studies have shown the efficacy for the same. They have demonstrated osteogenic, osteoinductive and osteoconductive potential and possess no risk of rejection or adverse immunological reaction.⁽¹³⁾ Autogenous grafts from both extra and intraoral sources have been used in periodontal therapy however, intraoral sites are preferred especially for the treatment of localized bone defects in partially edentulous jaws. In the present case report autogenous graft from mandibular symphysis region was harvested. Some advantages of this area for bone grafting procedures over other intraoral and extraoral sites are minimal resorption of the harvested bone graft, proximity to recipient site, no hospitalization, convenient surgical access and no cutaneous scar formation.⁽¹⁴⁾ The symphysis region has been reported to provide sufficient bone to augment a deficient ridge by 4-6mm in horizontal dimension and

up to 4mm in vertical dimension, covering a length up to a 3 tooth defect.⁽¹⁵⁾

The autogenous graft can be obtained in block or particulate form. The particulate autograft provides a rich source of bone and marrow cells that have osteogenic potential and a large osteoconductive surface area but lack rigidity and support. Therefore, corticocancellous blocks are preferred as they possess enhanced revascularization of cancellous portion, and mechanical support and rigidity of the cortical portion, which ensures optimal ridge augmentation.⁽¹⁶⁾ Autografts have certain limitations, such as second surgical site, potential resorption, size mismatch and inadequate volume of graft material.⁽¹⁷⁾ In the present case, any of these potential complications were not encountered. Uneventful healing was observed during the follow-up period.

GBR is based on the same principle as of GTR (Guided tissue regeneration), and utilizes resorbable or non-resorbable barrier membrane for space maintenance over the defect, resulting in compartmentalization and allows osteoblasts to populate the wound before epithelial and connective tissue cells, thus regenerating bone. Resorbable membranes have the advantage of eliminating the need for a second surgery for removal and thus reducing patient discomfort and maintaining tissue integrity.⁽¹⁸⁾

In this case report resorbable Sybograf™ - GBR prepared out of nano hydroxyapatite material in a matrix form has been used. The combination approach of particulate autogenous chin graft in conjunction with GBR membrane demonstrated improvement in the horizontal and vertical ridge dimensions at 6 months follow-up.

Conclusion

Ridge augmentation of an edentulous ridge deficient area is a challenging procedure. Various techniques and materials for ridge augmentation are available, but it is most appropriate to use an evidence-based approach for treatment planning. Since individual approaches may not aid to achieve the desired results we utilized a combination of autogenous particulate chin graft along with GBR membrane to achieve sufficient ridge height and width, thus facilitating further rehabilitation.

References

- Schropp L, Wenzel A, Kostopoulos L, Karring T. Bone healing and soft tissue contour changes following single-tooth extraction: a clinical and radiographic 12-month prospective study. *Int J Periodontics Restorative Dent* 2003;23(4):313-23.
- Araujo MG, Lindhe J. Dimensional ridge alterations following tooth extraction. An experimental study in dog. *J Clin Periodontol* 2005;32:212-18.
- Misch CE, Dietsh F. Autogenous bone grafts for endosteal implants- Indications and failures. *Int J Oral Implantol* 1991;8:13-20.
- McAllister BS, Haghghat K. Bone augmentation techniques. *J Periodontol* 2007;78:377-96.
- Rosenberg E, Rose LF. Biologic and clinical considerations for autografts and allografts in periodontal regeneration therapy. *Dent Clin North Am* 1998;42:467-90.
- Nyman S, Lindhe J, Karring T, Rylander H. New attachment following surgical treatment of human periodontal disease. *J Clin Periodontol* 1982;9:290-96.
- Machtei EE. The effect of membrane exposure on the outcome of regenerative procedures in humans: A meta-analysis. *J Periodontol* 2001;72:21-219.
- Bunyatravej P, Wang HL. Collagen membranes: A review. *J Periodontol* 2001;72:215-29.
- Oh TJ, Meraw SJ, Lee EJ, Giannobile WV, Wang HL. Comparative analysis of collagen membranes for the treatment of implant dehiscence defects. *Clin Oral Implants Res* 2003;14:80-90.
- Seibert JS. Reconstruction of deformed, partially edentulous ridges, using full thickness onlay grafts. Part I. Technique and wound healing. *Compend Contin Educ Dent* 1983;4:437-53.
- Allen EP, Gainza CS, Farthing GG, Newbold DA. Improved technique for localized ridge augmentation. A report of 21 cases. *J Periodontol* 1985;56:195-99.
- Hollinger JO, Brekke J, Gruskin E, Lee D. Role of bone substitutes. *Clin Orthop* 1996;324:55-65.
- Schlegel KA, Fichtner G, Schultze- Mosgau S, Wiltfang J. Histologic findings in sinus augmentation with autogenous bone chip versus a bovine bone substitute. *Int J Oral Maxillofac Implants* 2003;18:53-58.
- Schuler R, Verardi S, Ham BD. A new incision design for mandibular symphysis bone grafting procedures. *J Periodontol* 2005;76:846-9.
- Pikos MA. Mandibularblock autografts for alveolar ridge augmentation. *Atlas Oral Maxillofac Surg Clin North Am* 2005;13(2):91-109.
- Rosenberg E, Rose LF. Biologic and clinical considerations for autografts and allografts in periodontal regeneration therapy. *Dent Clin North Am* 1998;42:467-90.
- Fu JH, Wang HL. Horizontal Bone Augmentation: The decision tree. *Int J Periodontics Restorative Dent* 2011;31:429-36.
- Quinones CR, Caffesse RG. Current status of guided periodontal tissue regeneration. *Periodontol* 2000 1995;9:55-68.