

Free gingival graft – a versatile treatment modality

Vineeta Singal^{1,*}, Ritika Arora², Anamika Sharma³

¹PG Student, ²Senior Lecturer, ³Professor & HOD, Dept. of Periodontology, Subharti Dental College & Hospital, Meerut, Uttar Pradesh

***Corresponding Author:**

Email: vineetankit@gmail.com

Abstract

Introduction: Attached gingiva is the part of gingiva which is firm, resilient and tightly bound to the underlying periosteum of alveolar bone or to the root surface. The width of the attached gingiva is genetically predetermined, varies in different areas of the dentition, and its dimensions can change throughout life. Presence of an “adequate” amount of gingiva has been considered as a keystone for the maintenance of periodontal health. Free gingival graft (FGG) is a versatile treatment modality to create an adequate zone of attached gingiva.

Objective: Evaluating FGG procured from different anatomical sites to increase the width of attached gingiva.

Materials and Method: Three cases were selected with inadequate width of attached gingiva and treated with FGG obtained from different sites like palate, edentulous ridge and buccal attached gingiva. Cases were evaluated for gain in width of attached gingiva, colour matching of grafted soft tissue to adjacent areas and post-operative pain evaluation through visual analog scale.

Result: There was an increase in width of attached gingiva with some coronal migration. FGG obtained from buccal attached gingiva and edentulous region had least pain post operatively with satisfactory colour matching as compared to FGG obtained from palate.

Conclusion: FGG is a viable and effective modality for increasing the width of attached gingiva and can be procured from sites other than palate.

Keywords: Free gingival graft, Attached gingiva, Visual analog scale

Introduction

The attached gingiva is defined as the tissue between the mucogingival junction and the projection on the external gingival surface of the most apical portion of the gingival sulcus or the periodontal pocket.⁽¹⁾ The width of the attached gingiva is genetically predetermined, varies in different areas of the dentition, and its dimensions can change throughout life. Presence of an “adequate” amount of gingiva has been considered as a keystone for the maintenance of periodontal health.⁽²⁾

Inadequate zone of attached gingiva facilitate subgingival plaque formation, increases movability of the marginal tissue, favours attachment loss and soft tissue recession and impedes proper oral hygiene.

According to **Friedman**, Surgical procedures are designed to preserve gingiva, remove aberrant frenulum or muscle attachments, and increase the depth of the vestibule.⁽³⁾ Vestibular extension operations given by **Bohannon** were aimed at extending the depth of the vestibular sulcus.⁽⁴⁾ It can be done by Denudation technique with the risk of exposure of alveolar bone and severe bone resorption.⁽⁵⁾ Split flap procedure/ periosteal retention procedure showed less severe bone resorption but loss of crestal bone height was observed.⁽⁶⁾ Apically repositioned flap showed predictable increase in the width of the attached gingiva with the risk for extensive bone resorption.⁽⁷⁾

FGG from the palate has been used most commonly for gingival augmentation. Gingival and palatal soft tissue grafts have the property of maintaining their

original characteristics after transplantation to the recipient site.⁽⁸⁾

Materials and Method

Three cases were selected from the Out Patient Department of Department of Periodontology, Subharti Dental College and Hospital, Meerut having problem in maintaining a good oral hygiene or gingival recession. On examination inadequate width of attached gingiva was observed with respect to lower anterior teeth. They were treated with FGG obtained from different sites like palate, edentulous ridge and buccal attached gingiva. Cases were evaluated after 21 days for gain in width of attached gingiva, colour matching of grafted soft tissue with adjacent areas and post-operative pain evaluation using visual analog scale.

Case 1

After administering local anaesthesia recipient site in relation to 31, 41 was prepared by giving a horizontal incision along the mucogingival junction using no.15 blade. The keratinized tissue was de-epithelialized to expose the underlying connective tissue and create a trapezoidal recipient bed (Fig. 1a). FGG of appropriate size (1.5 x 16 x 7 mm) was harvested from the palate extending from the distal aspect of first premolar to the mesial aspect of first molar (Fig. 1b, 1c). FGG was contoured, adapted, and sutured on to the recipient bed (Fig. 1d). After suturing pressure was exerted against the graft for 5 minutes in order to eliminate the blood and exudate from between the graft and the recipient bed.

The palatal wound was protected with a periodontal dressing retained with the help of stent. Sutures were removed after 10 days and the healing was uneventful

(Fig. 1e). Patients were recalled after 21 days and was re-evaluated for increase in the width of attached gingiva (Fig. 1f).

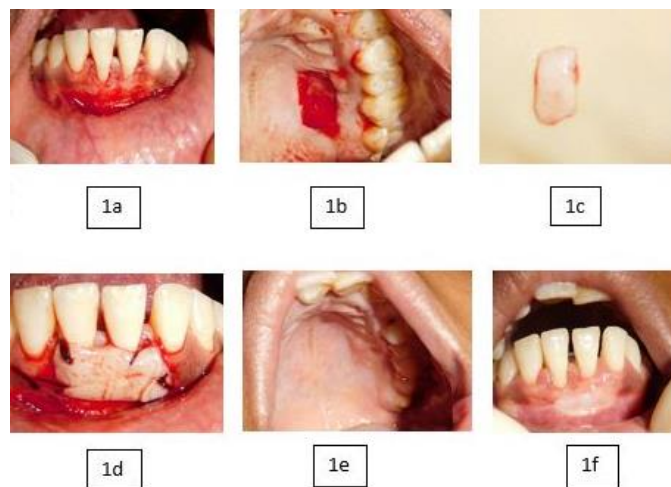

Fig. 1

Case 2

Same protocol was used to prepare the recipient site and FGG was obtained from edentulous site in relation to premolar and molar area in mandibular left posterior region (Fig. 2a). FGG obtained was 10x7x1.5 mm in dimensions (Fig. 2b). FGG was contoured, adapted, and sutured on to the recipient bed (Fig. 2c). The donor site was covered with moist gauge and patient was asked to compress the gauge. No periodontal dressing was given. Sutures were removed after 10 days and the healing was uneventful (Fig. 2d). Patients were recalled after 21 days and was re-evaluated for increase in the width of attached gingiva (Fig. 2e).

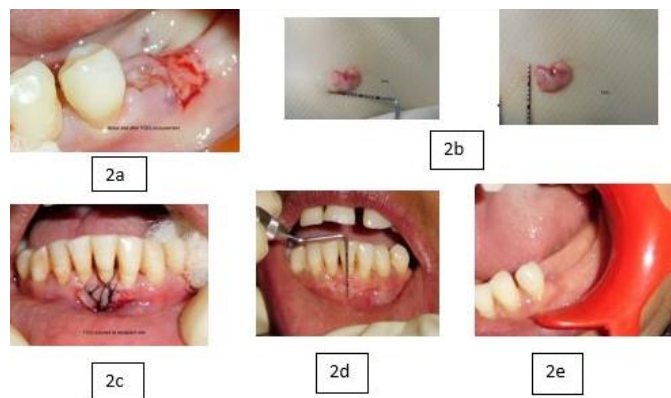


Fig. 2

Case 3

Same protocol was used to prepare the recipient site and FGG was obtained from attached buccal gingival in relation to premolar and molar area of maxillary right region (Fig. 3a). FGG obtained was 10x5x1.5 mm in dimension (Fig. 3b). FGG was contoured, adapted, and sutured on to the recipient bed (Fig. 3c). The donor site was covered with periodontal dressing and no stent was required as the dressing got the retention by interlocking in interdental areas. Sutures were removed after 10 days and the healing was uneventful (Fig. 3d). Patients were recalled after 21 days and was re-evaluated for increase in the width of attached gingiva (Fig. 3e).

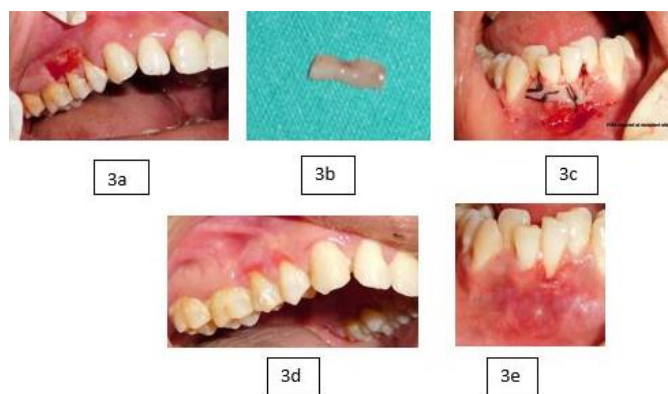


Fig. 3

Results

Increase in width of attached gingiva was seen with some coronal migration of the gingiva (Table 1). FGG obtained from buccal attached gingiva and edentulous region had least pain post operatively and in case where FGG was obtained from palate there was moderate pain (Table 2). The duration of surgical procedures was highly correlated with pain or swelling post-surgically. Colour matching was satisfactory for all three cases. However, the tissue blend and colour match obtained, in modified cases, were superior to that of conventional FGG. Complete root coverage was not obtained. But, no postoperative recession was noted at the donor site. Cases are still under follow up.

Table 1: Width of attached gingiva

	Width of attached gingiva (pre-op)	Width of attached gingiva (after 21 days)	Gain in width of attached gingiva
Case 1 (FGG from palate)	3mm	8mm	5mm
Case 2 (FGG from edentulous ridge)	3mm	7mm	4mm
Case 3 (FGG from buccal attached gingiva)	4mm	8mm	4mm

Table 2: Pain evaluation through visual analog scale

Case 1 (FGG from palate)	5 (moderate)
Case 2 (FGG from edentulous ridge)	2 (mild)
Case 3 (FGG from buccal attached gingiva)	3 (mild)

Discussion

Presence of wide band of keratinized and attached mucosa around the tooth is critical for maintain gingival health and preventing attachment loss and soft tissue recession.⁽⁹⁾ Adequate amount of gingiva is any dimension that is compatible with gingival health and prevents retraction of the gingival margin during movements of alveolar mucosa.⁽⁷⁾

Gingival augmentation should be considered if patient experiences discomfort during tooth brushing or chewing and there is progressive recession of gingival tissue. FGG have been most commonly used for gingival augmentation. However, allogenic graft material and human fibroblast derived dermal substitutes may also be used. But the increase in width of keratinised tissue is not predictable as with the use autogenous grafts.⁽¹⁰⁾

Combination of FGG with vestibuloplasty significantly increases the width of attached gingiva. Vascular part of gingiva when included in the graft gives superior tissue integration with recipient bed along with

a more esthetic coverage and favourable tissue blend.⁽¹¹⁾ This was in accordance with the present cases in which significant increase in the width of attached gingiva was observed with increase in thickness of gingival biotype. The esthetic results were also satisfactory with uneventful healing.

Connective tissue graft obtained from the edentulous area and used for soft tissue augmentation in esthetic region have reported satisfactory results.⁽¹²⁾ This was also observed in the present case in which FGG was procured from edentulous sites and gave esthetic results superior to that of conventional FGG.

FGG have been used in periodontal procedures to augment attached gingiva and cover denuded root surfaces. However, there are few limitations of the same such as esthetic mismatch, malalignment of mucogingival junction formation and bulky appearance.⁽¹³⁾

Conclusion

FGG is a viable and effective modality for increasing the width of attached gingiva and can be procured from sites other than palate. However, proper case selection and careful tissue management are the key to the success of the application of these modifications of FGG. More studies with a larger sample size would give more conclusive evidence.

References

1. Camargo PM, Melnick P & Kenney EB. The use of free gingival grafts for aesthetic purposes. *Periodontology* 2000 2001;27:72–96.
2. Carranza FA, Carraro JJ. Mucogingival techniques in periodontal surgery. *J Periodontol* 1970;41:294-299.
3. Friedman N. Mucogingival surgery. *Texas Dental Journal* 1975;75:358-362.
4. Bohannon HM. Studies in the alteration of vestibular depth. II. Periosteum retention. *Journal of Periodontology* 1962;33:354-359.
5. Ochsenein C. Newer concept of mucogingival surgery. *Journal of Periodontology* 1960;31:175-185.
6. Staffileno H, Wentz F, Orban B. Histologic study of healing of split thickness flap surgery in dogs. *Journal of Periodontology* 1962;33:56-69.
7. Friedman N. Mucogingival surgery: The apically repositioned flap. *Journal of Periodontology* 1962;33:328-340.
8. Sullivan HC and Atkins JH. Free autogenous gingival grafts. III. Utilization of grafts in the treatment of gingival recession. *Periodontics* 1968;6:152-160.
9. Nabers CL. Repositioning the attached gingiva. *Journal of Periodontology* 1954;25:38-39.
10. Harris RJ. Clinical evaluation of 3 techniques to augment keratinised tissue without root coverage. *Journal of Periodontology* 2001;77:932-938.
11. Thoma DS, Benic GI, Zwahlen M, Hammerele CH and Jung RE. A systematic review assessing soft tissue augmentation techniques. *Clinical oral implants research* 2009;20:146-165.
12. Meltzer JA. Edentulous Area Tissue Graft Correction of an Esthetic Defect: A case report. *J Periodontol* 1979;50:320-322.
13. Cohen ES. Ridge augmentation utilizing the subepithelial connective tissue graft: case reports. *Practical Periodontics and Esthetic Dentistry* 1994;6:47-53.