

Immediate implant and provisionalisation of an upper lateral incisor with an autogenous bone graft associated with a laterally positioned flap and connective tissue graft

Carmen Lucia Mueller Storrer^{1,*}, Emanuelle Cunha DDS², João C. Zielak³, Felipe Rychuv Santos⁴, Tatiana Miranda Deliberador⁵

¹Professor ²Student, Graduate Program in Dentistry, Universidade Positivo, Curitiba, PR, Brazil,

***Corresponding Author:**

Email: carmen.storrer@gmail.com

Abstract

Implant placement, followed by the extraction of a single tooth, is a common practice in implantology. Nevertheless, with the increase in the use of implants, the demand for satisfactory aesthetic results also increased. This case report demonstrated the aesthetic and functional resolution of the immediate implant and provisionalisation of an upper lateral incisor with an autogenous bone graft associated with a laterally positioned flap and a connective tissue graft. The present procedure, which is in the aesthetic zone, is made a challenge because of the marginal mucosal recession of tooth 22 and the periodontal tissue biotype. Sixty days after the surgery and provisional crown, the patient reported aesthetic satisfaction and excellent soft tissue healing in the dental implant region. It can be concluded that the aesthetic and functional resolution of this clinical case that success in replacing a tooth for implantation in the aesthetic zone requires perio-implantology planning and professional skill in tissue manipulation.

Keywords: Dental Implants, Dental Aesthetics, Graft Tissue, Provisionalisation

Introduction

The use of dental implants to improve the functional and aesthetic demands of dentition has increased significantly over the past two decades. Initially, implants were designed as a functional replacement for tooth loss. Nevertheless, with the increased use of implants, the demand for satisfactory aesthetic results also increased.⁽¹⁾

The use of implants following the extraction of a single tooth is frequently occurring in daily practice. This procedure is particularly challenging in the aesthetic zone, mainly because the patients often have the highest expectations of an attractive outcome for the treatment.⁽²⁾

In general, the patients who agreed to implant treatment would not only like a better dental prosthesis, but also improved functional aesthetics. The results depend on several factors, such as the characteristics of the material and the surface of the implant, the design of the implant, anatomic conditions, a correct surgical technique, an adequate treatment plan, patient motivation and cooperation, an appropriate prosthetic concept and the absence of inappropriate loads on the prosthesis.⁽³⁾

In addition, more than anything, treatments that involve implants in the maxillary anterior region require satisfactory aesthetic results. Recent studies reported that the recession of the marginal peri-implant mucosa might occur, which results in an adverse effect on the final aesthetic outcome. Several factors have been reported to influence the frequency and extent of marginal mucosal recession, including periodontal tissue biotype,^(4,5) The connection of a provisional

crown immediately following implant insertion, the condition and thickness of the facial bone,^(6,7) the orofacial position of the implant shoulder^(8,9) and grafting of the facial peri-implant marginal defect with bone or bone substitutes.⁽¹⁰⁾

If the gingival and osseous architecture of the failing tooth is acceptable, then the therapeutic goal is to maintain the existing morphological condition. The immediate provisional crown helps to maintain soft tissue contours and papillary height.⁽¹¹⁾ The challenge, however, happens when there is a marginal recession and the absence of the bone wall in the region where the tooth would be extracted. Thus, tissue and bone graft must be considered.⁽¹²⁾

The major indication for soft tissue augmentation of the edentulous ridge is aesthetics. Bone grafts are indicated, not only to correct the position of the implant, but also to fill the area between the alveolar bone and implant (gap). Soft tissue grafts such as connective tissue aim to increase the amount of keratinised gingival and thickness. A lack of appropriate donor tissue with respect to the amount and/or quality is a contraindication for tissue augmentation.⁽¹³⁾

The laterally positioned flap (LPF) could be an alternative in order to prevent mid-facial mucosal recession following immediate implant placement when there is not enough width of keratinised mucosa. The LPF was introduced by Grupe and Warren in 1956. It was the first predictable method for covering root surfaces by maintaining the vascular connections through the base and the body of the transposed tissue. To reduce the potential risk for dehiscence at the donor

tooth to the denudation of the bone plate, the use of a split-thickness flap was proposed.⁽¹⁴⁾

This case report aimed to present a single case of an immediate placement and non-functional loaded implant after tooth extraction, followed by the LPF associated with connective tissue graft (CTG) technique.

Case Report

A healthy 56-year-old Caucasian man who is an ex-smoker presented at Positivo University's Dental Clinic. His major complaint was the aesthetics of his upper maxillary left lateral incisor #22 (Fig. 1). In the clinical exam, the presence of deep probing depth, bleeding on probing, grade II tooth mobility, and a loss of clinical attachment (CAL) (≥ 6 mm in the buccal side) were noted. A computed tomography scan made it possible to observe severe bone loss on the buccal surface of tooth 12. The proposed treatment was extraction, immediate installation of an implant, and aesthetics with autogenous bone grafting and soft tissue manipulation. Once there was not enough gingiva to cover the implant, it was necessary to slide a lateral flap.

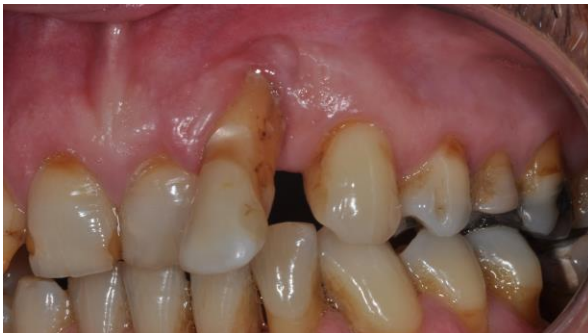

Fig. 1: Baseline. Buccal aspect of #22 with 6 mm of CAL. Small inclination compromising the aesthetics of the smile. Minimum amount of attached gingiva in region #22

The first appointment consisted of oral hygiene orientation and prophylaxis, in addition to molding the upper and lower teeth in order to create a surgical guide for the provisional non-function crown over the implant and to register the occlusion. The surgery was performed under local anesthesia (articaine + epinephrine 1:100.000). This case report turned out to be a challenging procedure once there was marginal gingival recession on tooth 22, which almost completely exposed the root. An LPF was performed before the tooth extraction in order to be sure that the gingival tissue would be able to cover the future implant. The tooth was carefully and atraumatic removed in order to preserve the integrity of the alveolar bone. The socket was curetted and decontaminated with tetracycline hydrochloride.⁽¹⁵⁾ A split-thickness flap was mobilised on the adjacent tooth.

The flap was then positioned laterally to cover the future implant and guarantee gingival augmentation (Fig. 2). To provide adequate accuracy for implant placement, a surgical guide was used in the surgery (Fig. 3). The implant site was prepared with standard drills by using the bony walls as a guide, under copious saline irrigation. Moreover, the implant was placed at the palatal level of the bone crest (i.e., 2 mm apical of the bone height at the mesial and distal level). Good primary stability was obtained, considering the lack of the buccal wall. A Frictional I implant with a standard platform (3,75mm x 11mm) (Koop Curitiba/PR, Brazil) was installed according to the manufacturer's instructions (Fig. 4). A torque of approximately 35 N was achieved, which was measured by a precisely calibrated ratchet. After the insertion of the implant, the buccal bone defect was filled with an autogenous bone graft from the tuberosity of the maxilla (Fig. 5A). Finally, in order to cover the buccal surface of the implant with gingiva and increase the volume of the buccal tissue, CTG was associated with LPF. The LPF was able to cover the bone and soft tissue graft completely with simple interrupted sutures (4-0 Vicryl, Ethicon), taking care to avoid excessive tension (Fig. 5C). Then a temporary crown was installed in the infra occlusion.

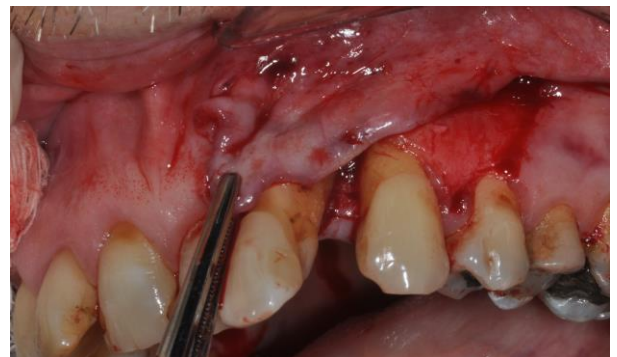

Fig. 2: Because of the lack of keratinised gingival tissue at tooth 22, a lateral positioned (split) flap (LPF) was realised from teeth 23 and 24. This technique has guaranteed optimal nutrition

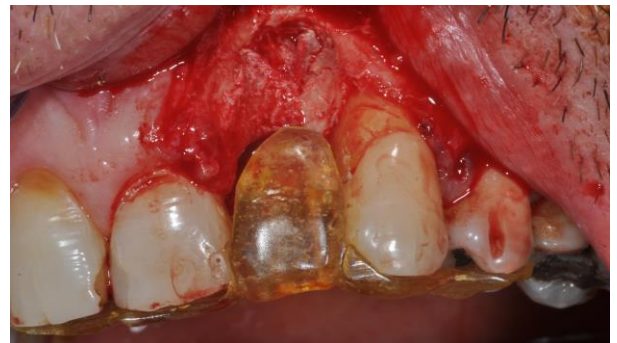

Fig. 3: A surgical guide was positioned in order to provide adequate accuracy for implant placement

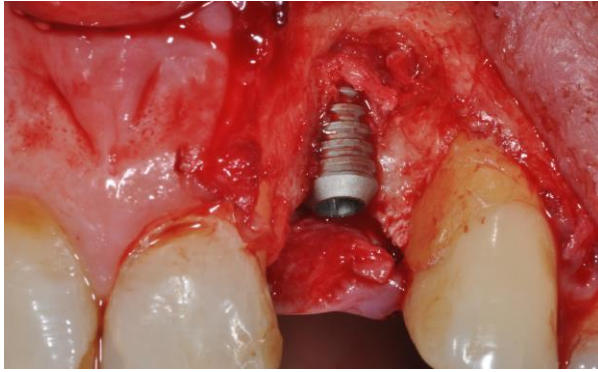


Fig. 4: An immediate non-functional loading implant placed with adequate primary stability following the extraction of tooth 22

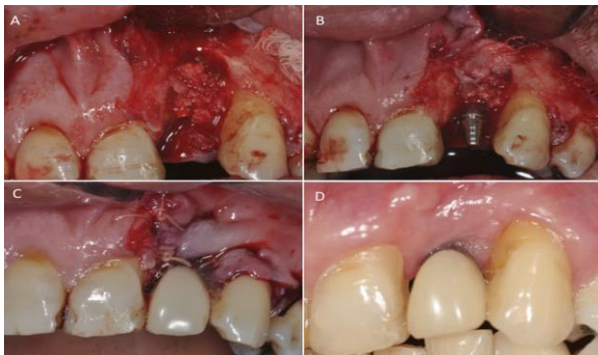


Fig. 5: (a) Implant threads covered by an autogenous bone graft; (b) a connective tissue graft increases the volume and serves as a gingival membrane to keep the graft in place (c) An abutment secured onto the implant. A sutured LPF covering the connective and bone graft, so it was possible to have keratinised gingiva in the region of the implant prosthesis (d) Provisional non-functional crown after 60 days

After surgery, the patient received a pain control medication (750 mg of paracetamol every 6 hours for 4 days), an antibiotic (500 mg of amoxicillin every 8 hours for 7 days), and chemical plaque control (a 0.12% chlorhexidine gluconate rinse every 12 hours for 14 days).

The patient was supervised for oral hygiene control. Clinical follow-up was performed at 10, 60, and 120 days postoperatively. The post-surgical healing phase was uneventful for the patient. Sixty days after the procedure, the patient reported being completely satisfied with the aesthetic outcome. (Fig. 5D)

Discussion

The ability to minimise hard- and soft-tissue changes is very important when performing immediate implant placement in the aesthetic zone.⁽¹⁶⁾ The advantages and approaches include fewer surgical procedures, atraumatic extraction, a shorter treatment timeframe, an immediate temporary prosthesis, and

preservation of both the crestal bone height and bone width.^(11,17)

The challenge, however, arises when there is not enough gingival tissue to cover the fixed implant in the newly extracted socket root, as demonstrated in this case report. Therefore, there is a need to perform some sort of soft-tissue grafting along with the installation of the implant associated with LPF. Even if no immediate implant had been installed, the absence of gum and buccal bone wall would require surgery and a gingival graft in this region with more than one intervention. However, the option of performing the technique in a single procedure is validated in literature, as well as by this clinical case.^(1,11,18)

In cases where an anterior tooth will be lost, the placement of a temporary crown that not loaded and is totally out of occlusion on an immediate implant not only preserves the crestal bone, but also supports the gingival contour and preserves the papillae. As a result, a natural-looking crown is achieved.⁽¹⁶⁾ On the other hand, different results were obtained in an animal model. It was observed that when an immediate implant is placed into fresh extraction sockets, it might jeopardise the vertical bone remodelling.⁽¹⁷⁾ Ultimately, the healing of an extraction socket does not result in 100% bone fill and major changes in the extraction site might occur during the first year.⁽¹⁸⁾ In this case report, our results – combining immediate implant placement, placement of a temporary crown that is not loaded and soft tissue manipulation such as, connective tissue graft, and a coronally positioned flap, provided esthetic success even in facial osseous defect situations. The same conclusion was observed recently where an immediate implant placement and provisionalization in the esthetic zone have been documented with success.⁽¹⁹⁾ Furthermore, the conclusion of a recent systematic review and meta-analysis confirmed that immediately and conventionally loaded single-implant crowns are equally successful in terms of implant survival and marginal bone loss.⁽²⁰⁾

This case report was intended to restore the patient's aesthetics and functionality in one session. The proposed treatment facility for the immediate implant placement associated with a non-functional crown reduced the number of surgical interventions and minimised the loss of the bone crest. Furthermore, the surgical technique of a bone graft associated with CTG and LPF enable the lining of the buccal wall implantation and clinical resolution of this complex case. It is very important to focus on marginal bone loss, implant survival and success, but it is mainly the immediate aesthetic result that concerns most patients.⁽¹⁾ Giving a patient a dental crown, even a temporary one, on the same day as the extraction brings him or her comfort and safety. In our clinical case, we could witness the improvement of the patient's quality of life when the upper maxillary left lateral incisor was

replaced by an immediately not loaded implant, especially as it is in an esthetic zone.

Conclusion

It can be concluded that the aesthetic and functional resolution of this clinical case that success in replacing a tooth for implantation in the aesthetic zone requires perio-implantology planning and professional skill in tissue manipulation.

References

1. Raes F, Cosyn J and De Bruyn H. Clinical. Aesthetic, and Patient-Related Outcome of Immediately Loaded Single Implants in the Anterior Maxilla: A Prospective Study in Extraction Sockets, Healed Ridges, and Grafted Sites. *Clin Implant Dent Relat Res* 2013;15:819-835.
2. Buser D, Halbritter S, Hart C, et al. Early Implant Placement with Simultaneous Guided Bone Regeneration Following Single-Tooth Extraction in the Esthetic Zone: 12 Month Results of a Prospective Study with 20 Consecutive Patients. *J Periodontol* 2009;80:152-162.
3. Khoury F and Hoppe A. Soft tissue management in oral implantology: A review of surgical techniques for shaping an esthetic and functional peri-implant soft tissue structure. *Quintessence Int* 2000;31:483-499.
4. Chen ST, Darby IB, Reynolds EC and Clement JG. Immediate Implant Placement Postextraction without Flap Elevation. *J Periodontol* 2009;80:163-172.
5. Brugnami F and Caiazzo A. Immediate Placement and Provisionalization with Buccal Plate Preservation: A Case Report of a New Technique. *J Oral Implantol* 2013;39:380-385.
6. Grunder U, Gracis S and Capelli M. Influence of the 3-D bone to implant relationship on esthetics. *Int J Periodontics Restorative Dent* 2005;25:113-119.
7. Malchiodi L, Cucchi A, Ghensi P and Nocini PF. Evaluation of the Esthetic Results of 64 Non-functional Immediately Loaded Postextraction Implants in the Maxilla: Correlation between Interproximal Alveolar Crest and Soft Tissues at 3 Years of Follow-Up. *Clin Implant Dent Relat Res* 2013;15:130-142.
8. Evans CD and Chen ST. Esthetic outcomes of immediate implant placements. *Clin Oral Implants Res* 2008;19:73-80.
9. Brown SDK and Payne AGT. Immediately restored single implants in the aesthetic zone of the maxilla using a novel design: 1-year report. *Clin Oral Implants Res* 2011;22:445-454.
10. Hof M, Pommer B, Strbac GD et al. Esthetic evaluation of single-tooth implants in the anterior maxilla following autologous bone augmentation. *Clin Oral Implants Res* 2013;24 (Suppl A100):88-93.
11. Turkyilmaz I and Shapiro V. Immediate provisional restoration of an implant placed in a fresh primary maxillary canine extraction socket: a case report. *Gen Dent* 2011;59:e105-109.
12. Deliberador TM, Vieira JS, Bonacin R, Storrer CL et al. Connective tissue graft combined with autogenous bone graft in the treatment of peri-implant soft and hard tissue defect. *Quintessence Int* 2015;46:139-144.
13. Grupe HE and Warren RF. Repair of gingival defects by a sliding flap operation. *J Periodontol* 1956;27:92-99.
14. Zucchelli G and Mounssif I. Periodontal plastic surgery. *Periodontol 2000*. 2015;68:333-368.
15. Nagata MJ, Bosco AF, Leite CM, Melo LG et al. Healing of dehiscence defects following root surface demineralization with tetracycline: a histologic study in monkeys. *J Periodontol* 2005;76:908-914.
16. Mandelaris GA and Vlk SD. Guided Implant Surgery with Placement of a Presurgical CAD/CAM Patient-Specific Abutment and Provisional in the Esthetic Zone. *Compend Contin Educ Dent* 2014;35:494-504.
17. Discepoli N, Vignoletti F, Laino L, de Sanctis M et al. Fresh extraction socket: spontaneous healing vs. immediate implant placement. *Clin Oral Implants Res* 2015;26:1250-1255.
18. Hämmerle CH, Chen ST and Wilson TG Jr. Consensus statements and recommended clinical procedures regarding the placement of implants in extraction sockets. *Int J Oral Maxillofac Implants* 2004;19 (Suppl):26-28.
19. Waki T and Kan JY. Immediate placement and provisionalization of maxillary anterior single implant with guided bone regeneration, connective tissue graft, and coronally positioned flap procedures. *Int J Esthet Dent* 2016;11:174-185.
20. Benic GI, Mir-Mari J and Hämmerle CH. Loading protocols for single-implant crowns: a systematic review and meta-analysis. *Int J Oral Maxillofac Implants* 2014;29 (Suppl):222-238.