

Management of grade II furcation defect in mandibular molar with alloplastic bone graft and bioresorbable guided tissue regeneration membrane: A case report

Mrinalini Ag. Bhatnagar^{1,*}, Deepa D²

¹PG Student, ²Professor, Dept. of Periodontology, Subharti Dental College & Hospital, Meerut

***Corresponding Author:**

Email: deepa_arun@rediffmail.com

Abstract

Background: Management of furcation represent one of the greatest challenges in periodontal therapy due to limited accessibility and complex anatomy of furcal areas. The main aim of regenerative therapy is regeneration of periodontal hard and soft-tissues, including formation of a new attachment apparatus. Various reconstructive procedures have been employed over years to achieve this goal.

Aim: To evaluate the efficacy of alloplastic bone graft along with GTR membrane in the management of mandibular grade II furcation defect.

Materials and method: Grade II mandibular furcation defect was treated using bone graft **Ostin™** along with bioresorbable collagen GTR membrane **Periocol®**. Evaluation of clinical parameters, probing depth (PD), clinical attachment level (CAL), radiovisuography was done preoperatively and at three and six months postoperatively.

Results and Conclusion: Six months postoperative measurements demonstrated reduction in probing depths and bone fill in the region of furcation defect. The results observed showed that combined treatment modalities using alloplastic bone graft and GTR membrane are beneficial for the treatment of mandibular grade II furcation defects.

Keywords: Bone graft, Collagen membrane, Furcation, Guided tissue regeneration.

Introduction

Periodontitis is a disease of multifactorial origin, “an inflammatory disease of the teeth caused by specific microorganisms or group of microorganisms, resulting in progressive destruction of the periodontal ligament and alveolar bone with pocket formation, recession or both”.⁽¹⁾ Progression of loss of attachment horizontally into the region between roots creates an additional problem of access and leads to furcation involvement. The management of furcation involvement presents one of the greatest challenges in periodontal therapy mainly due to complex anatomical features and limited accessibility of furcal areas. Proper diagnosis of furcation lesions and knowledge of furcal anatomy are critical for optimal therapy.⁽²⁾

Depending upon the severity of involvement furcation has been classified into grade I, grade II, grade III and grade IV. Grade II furcation lesion is a cul-de-sac with a definite horizontal component.⁽²⁾ Attempts to treat inaccessible furcation lesions have led to various therapies ranging from scaling, root planing, surgical flap debridement to root resection techniques. Surgical access significantly enhances removal of calculus from molars with furcation invasion. The primary objective of any furcation therapy is the elimination of the pocket by resective or regenerative procedures and making the area accessible for plaque control. More recently, techniques aimed at using bone grafts and / or barrier materials have been evaluated in regenerating furcation defects.⁽³⁾

Several calcium phosphate biomaterials have been tested since the mid 1970's. They have excellent tissue compatibility and do not elicit any inflammation or

foreign body response. Two types of calcium phosphate ceramics have been used, hydroxyapatite and tricalcium phosphate.⁽⁴⁾

Nyman et al (1986)⁽⁵⁾ first introduced the concept of GTR for treatment of periodontal defects. These investigators first reported that GTR could be favorably employed to regenerate lost periodontal tissues in grade II furcation involvement.

Bone grafts could be used with both resorbable and non-resorbable barriers. Also, reports have suggested added benefits of combined therapy in case of furcation defects. The present paper presents periodontal regeneration in mandibular grade II furcation defect with combined treatment modality using β -tricalcium phosphate bone graft (**Ostin™**, Basic Healthcare Pvt Ltd, Himachal Pradesh, India) with bioresorbable type I collagen GTR membrane (**Periocol®**, Eucare Pharmaceuticals Pvt. Ltd., Chennai, India).

Case Presentation

A 35 year old male reported to the outpatient department (OPD), department of Periodontology, Subharti Dental College and Hospital, Meerut, (Uttar Pradesh) with the chief complaint of food lodgement and bleeding gums in left lower back teeth region since 2 months. His past medical and personal history was non-contributory. Upon clinical examination, the site revealed signs of inflammation, increased vertical probing depth and buccal furcation involvement in #36. RVG was taken to confirm the presence and severity of furcation defect radiographically.

Pre-Surgical Procedure: The patient underwent phase I therapy which included scaling and root planing, followed by oral hygiene instructions. Four weeks after the phase I therapy, patient was recalled for surgery. Prior to the surgery a signed informed consent was obtained from the patient.

Pre-Operative Measurements: Probing pocket depth, PD = 4mm, Relative attachment level, RAL= 10 mm, Horizontal furcation defect, HFD= 4mm was recorded at baseline. A stent was fabricated with self-cured acrylic resin for insertion of the Naber's probe in the furcation defect.(Fig. 1) Clinical parameters were recorded at baseline, 3 months and 6 months interval. Radiographs of the site were recorded preoperatively(Fig. 2) and postoperatively at 3 and 6 months.

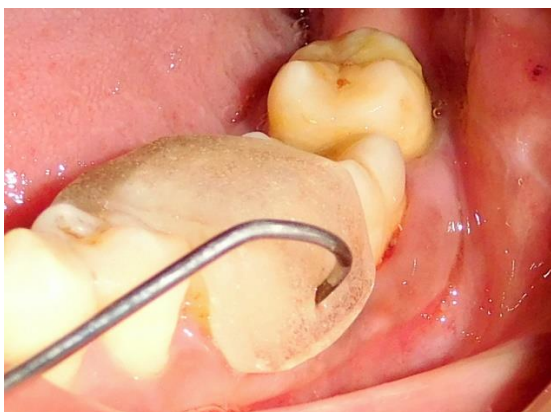

Fig. 1: Pre-operative horizontal furcation depth

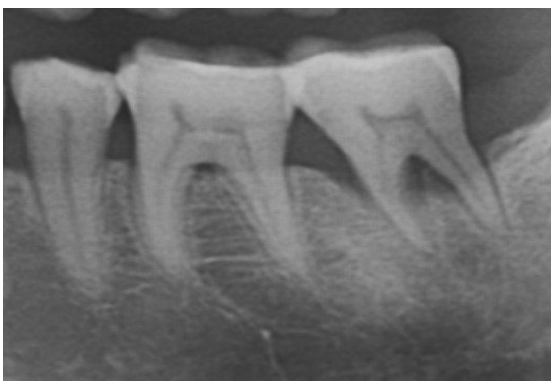

Fig. 2: Pre-operative RVG

Surgical Procedure: After phase-I therapy, surgical procedure was performed under proper aseptic precautions to keep the surgical site clean. After injecting local anesthesia (2% Xylocaine® Dental with 1:80,000 adrenaline, Novocol Pharmaceutical of Canada, Cambridge, ON, Canada), sulcular incisions were placed, a full thickness flap was elevated at the furcation site, extending at least one tooth mesial and distal to the affected tooth, and extended beyond mucogingival junction.(Fig. 3) The furcation area was thoroughly debrided and cleaned using furcation

curette, hand and ultrasonic scalers. After this, the defect area was condensed with the bone graft particles (**Ostin™**, Basic Healthcare Pvt Ltd, Himachal Pradesh, India) mixed with saline and covered by bioabsorbable GTR membrane (**Periocol®**, Eucare Pharmaceuticals Pvt. Ltd., Chennai, India)(Fig. 4 & 5). The membrane being hydrophilic in nature adapted well over the defect and no suturing was required. Flaps were then repositioned and sutured back (Mersilk®, Ethicon, Sommerville, NJ, USA) (Fig. 6). Periodontal dressing was applied over the site (Coe Pak®, GC America, Alsip, IL, USA). Postoperative regimen of amoxicillin 500 mg tds for 5 days, ibuprofen 400 mg tds for 5 days and postoperative instructions were given. Patient was recalled for periodontal dressing and suture removal after 1 week. Post-operative periodontal examination revealed reduction in vertical probing depth (VPD = 3mm) and horizontal furcation depth (HFD = 2mm) (Fig. 7) and radiographs revealed increased bone density (Fig. 8), thereby indicating successful resolution of inflammation and periodontal regeneration in the furcation defect area.

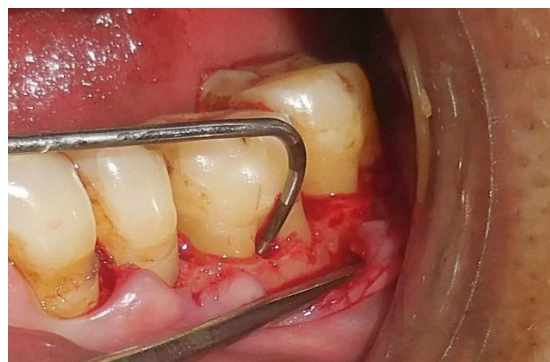

Fig. 3: Furcation defect upon flap reflection

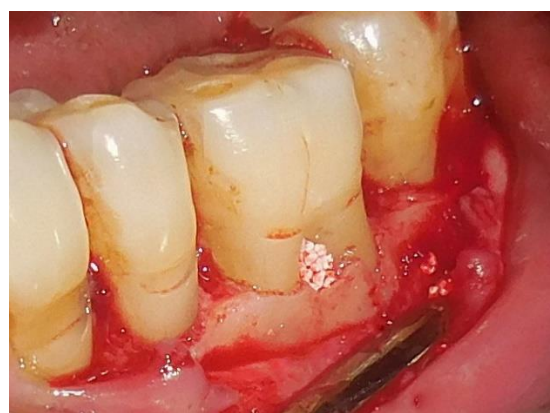

Fig. 4: Furcation defect with alloplastic bone graft

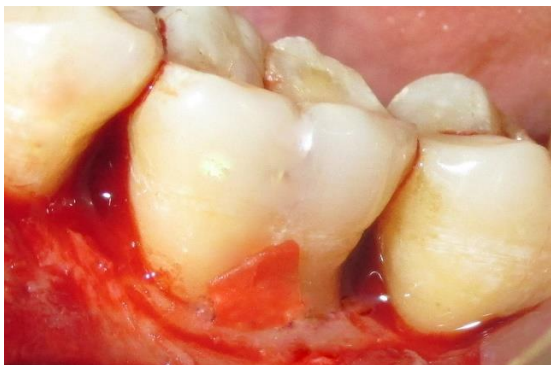

Fig. 5: Furcation defect with GTR membrane in place

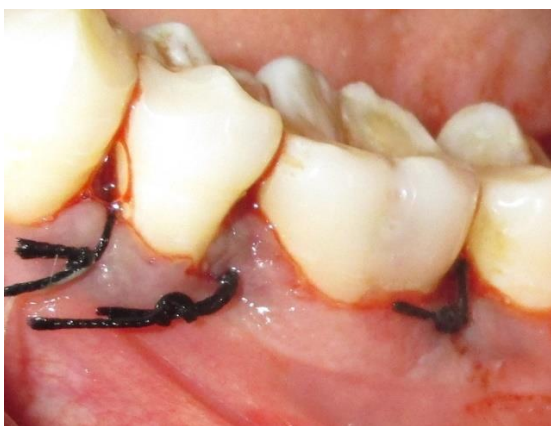

Fig. 6: Flap sutured at desired position

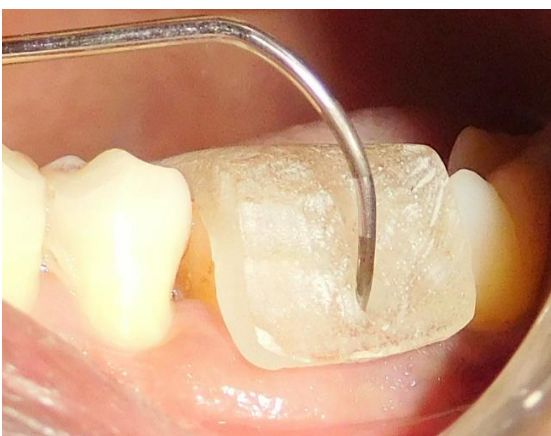


Fig. 7: Six-month horizontal furcation depth

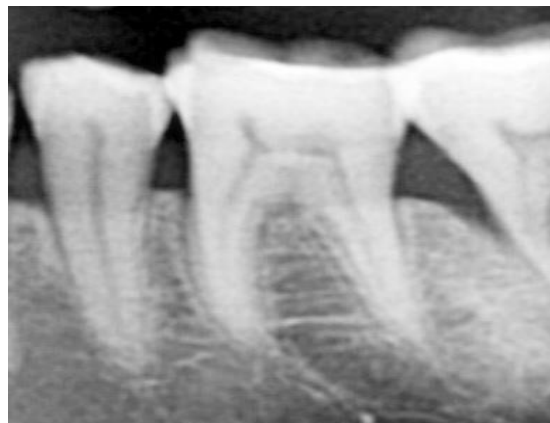

Fig. 8: Six-month postoperative RVG

Discussion

The main aim of regenerative therapy is regeneration of periodontal hard and soft-tissues, including formation of a new attachment apparatus, which would result in the closure of the furcation.⁽⁶⁾ The various regenerative approaches utilized in the management of class II furcation involvements include root surface biomodification, coronally positioned flaps, the use of various bone replacement grafts, and guided tissue regeneration procedures.

In the present case, combined treatment approach using bone graft and GTR membrane was used for treatment of mandibular grade II furcation defect. The bone graft material **OSTIN™** (Basic Healthcare Pvt Ltd, Himachal Pradesh, India) used, is a biphasic calcium phosphate consisting of hydroxyapatite and β -tricalcium phosphate in the weight-percentage ratio approximately 60:40 and crystalline structure similar to that of bone. . The use of resorbable membrane is advantageous over non-resorbable membrane in terms of avoidance of a second surgical intervention and therefore preventing the exposure of newly formed tissue below the membrane.⁽⁷⁾ Several commercially available resorbable membranes have been developed with type I collagen as their main component. Collagen membrane selection used in this case **Periocol®** (Eucare Pharmaceuticals Pvt. Ltd., Chennai, India), was based on the fact that type I collagen is the main constituent of periodontal connective tissue. Collagen materials also possess additional advantages such as hemostasis and chemotaxis for periodontal ligament fibroblasts and gingival fibroblasts, reduced immunogenicity, easy manipulation, and ability to augment tissue thickness.⁽⁸⁾ Hence, collagen membranes are ideal for resorbable GTR membranes.⁽⁹⁾

The bone graft and membrane appeared to be biocompatible and safe and caused no immunological, foreign-body or irritating response. All measurements were made using the UNC-15 probe and Naber's probe with the help of a custom made acrylic stent, that served

as a fixed reference point. The theoretical advantage of the stent system was demonstrated by Sivertson and Burgett.⁽¹⁰⁾ In the present case the clinical parameters like horizontal furcation depth, vertical probing depth and clinical attachment level showed improvement when compared at 6 months from baseline. Quantitative radiographic evaluation was not done; however, comparisons between the initial and six-month postoperative radiograph revealed increased bone fill as revealed by the increased radio-opacity around the furcation area at six-month postoperative evaluation.

Conclusion

The management of class II furcation involvement presents a unique clinical problem due to the complexity in anatomy at the furcation area. However, the results observed in the present case showed that combined treatment modalities using alloplastic bone graft and GTR membrane are beneficial for the treatment of mandibular grade II furcation defects.

References

1. Newman MG, Takei HH, Klokkevold PR, Carranza FA. Classification of diseases and conditions affecting the periodontium. Clinical periodontology. 10th edition, Saunders; Elsevier India Pvt Ltd; 2006:103-104.
2. Prathap S, Hegde S, Kashyap R, Prathap MS, Arunkumar MS. Clinical evaluation of porous hydroxyapatite bone graft (PerioboneG[®]) with and without collagen membrane (Periocol[®]) in the treatment of bilateral grade II furcation defects in mandibular first permanent molars. J Indian Soc Periodontol 2013;17: 228-234.
3. Pontoriero R, Nyman S, Lindhe J, Rosenberg E, Sanavi F. Guided tissue regeneration in the treatment of furcation defects in mandible. J Clin Periodontol 1987;14:618-20.
4. Nasr HF, Aichelmann-Reidy ME, Yukna RA. Bone and bone substitutes. Periodontology 2000;1999;19:74-86.
5. Gottlow J, Nyman S, Lindhe J, Karring T, Wennstrom J. New attachment formation in human periodontium by guided tissue regeneration. Case reports. J Clin Periodontol 1986;13:604-616.
6. P.R. Cury, E.A. Sallum, F.H. Nociti Jr., A.W. Sallum, and M.K. Jeffcoat. Long-Term Results of GTR in Class II Furcation Defects: A randomized controlled trial. J Periodontol 2003;74:3-9.
7. Khanna D, Malhotra S, Naidu DV. Treatment of grade II furcation involvement using resorbable guided tissue regeneration membrane: A six month study. J Indian Soc Periodontol 2012;16 :404-10.
8. Jain D, Deepa D. A comparative evaluation of freeze-dried bone allograft with and without bioabsorbable guided tissue regeneration membrane Healiguide[®] in the treatment of Grade II furcation defects: A clinical study. J Indian Soc Periodontol 2015;19:645-50.
9. Bunyaratavej P, Wang HL. Collagen membranes: A review. J Periodontol 2001;72:215-29.
10. Sivertson JF, Burgett FG. Probing of pockets related to the attachment level. J Periodontol 1976;47:281-86.