

All on four - an alternative to ridge augmentation procedure in atrophied maxillary ridge

Akshay Gurha^{1,*}, Varun Verma², AS Rana³, Deepak Gupta⁴

¹Professor & Head, Maharana Pratap Dental College & Hospital, Kanpur, ²Senior Lecturer, ³Professor & Head, ⁴Reader, Dept. of Oral & Maxillofacial Surgery, Shree Bankey Bihari Dental College, Hapur, Ghaziabad, Uttar Pradesh

***Corresponding Author:**

Email: gurhaakshay1967@gmail.com

Abstract

Edentulism is a common physiologic problem which result from many factors such as poor oral hygiene, dental caries and periodontal disease. There are also those patients who face edentulism due to a terminal non restorable dentition that has a negative impact on oral health-related quality of life. Clinicians are faced with the growing need to offer solutions to this population due to an increase in their life expectancy and to fabricate prostheses that provide a replacement for the loss of natural teeth, allowing optimum satisfaction and improved quality of life. The All-on-Four treatment concept provides edentulous arches and immediate/post-extraction subjects with an immediately loaded, fixed prosthesis using 4 implants: 2 axially oriented implants in the anterior region and 2 tilted posterior implants. This treatment has been developed to maximize the use of available bone and allows immediate function.

Keywords: Edentulous arches, Dental implants, Abutment, All-on-Four implant

Introduction

Most edentulous patients with resorbed alveolar ridge have complaint of denture not staying in place. The dentures are stabilized by the coordination between the muscle forces of the cheek and tongue.¹ The common reasons for dissatisfaction in patients using dentures are pain, areas of discomfort, poor denture stability, reduced masticatory functions, decreased motor control of the tongue, reduced bite force, and diminished oral sensory function²⁻⁴ and compromised retention capability. For all such patients, in the present era, implant supported over-dentures is minimally invasive and cost effective option.

Dr. Paulo Malo⁵ successfully treated the first patient with the All-on-4 treatment concept. Since then hundreds of thousands of patients have been treated with this concept. The All-on-4 treatment concept is a cost-efficient, graftless solution that provides patients with a fixed full-arch prosthesis on the day of surgery. Characteristics include:

Characteristics include:

1. Full-arch rehabilitation with only four implants two implants drilled straight in the anterior region and two implants tilted up to 45° in the posterior.
2. Immediate Function (fixed provisional bridge)- Done for patients that meet the criteria for immediate loading of implants.
3. Graftless procedure- Bone grafting is avoided by tilting the posterior implants, utilizing available bone.

This full arch prosthesis that is delivered on the same day of surgery has proven to show a drastic improvement in quality of life along with patient satisfaction in regard to function, esthetics, sense, speech and self-esteem^{6,7}. Tilting of the posterior implants avoids time-taking bone grafting procedures and immediate loading shortens time-to-teeth.⁸ Lower cost in

comparison with conventional implant treatment modalities of the edentulous has given this concept a better acceptance in dentistry.⁸

Case Report

A 72 year old patient presented to the Department with a chief complaint of an unstable denture that posed a problem while eating and talking. Dental examination revealed that the mandibular and maxillary alveolar ridges were resorbed, the patient's previous dentures were worn out that led to a reduction in vertical facial height. The patient was the given the option of making a new conventional complete dentures, implant supported fixed prosthesis and implant over-denture. The patient opted for implant supported fixed prosthesis.

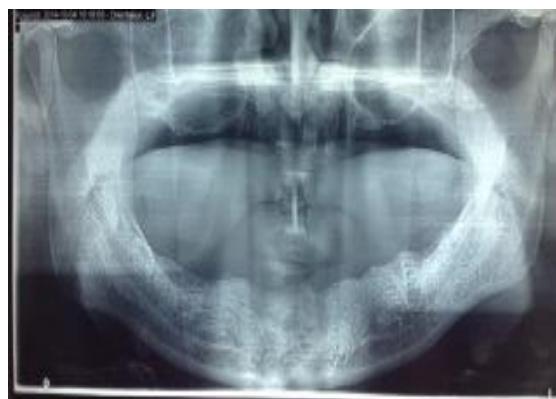

Fig. 1: Pre-operative Orthopantomogram

A cone-beam computerized tomographic scan (CBCT; I-CAT cone beam CT scan) (Fig. 2) was taken prior to surgery showing inadequate bone in the maxillary sinus region.

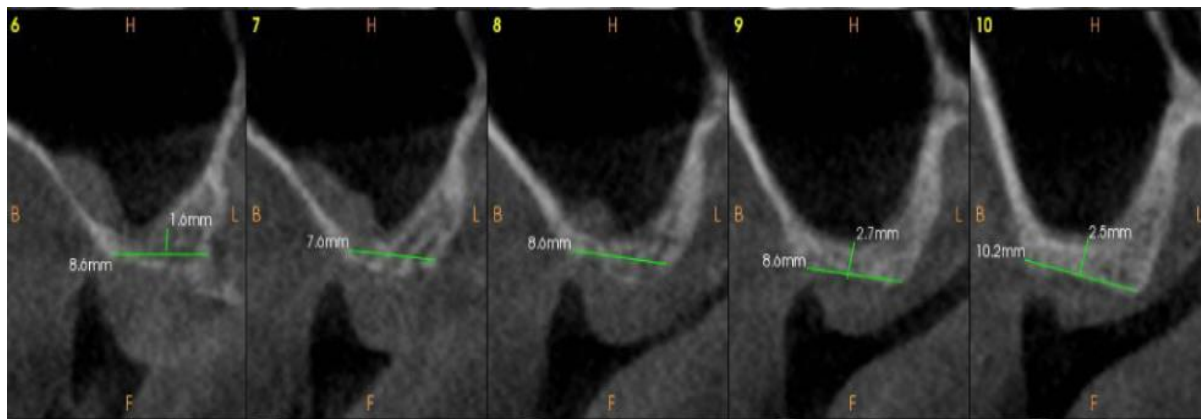


Fig. 2: Pre-operative CBCT of the maxillary sinus region

Local anesthesia was administered by both block and infiltration technique. Implant placement Touareg S (Adin) implants were inserted. Subject received 2 distally tilted implants in the posterior region followed by 2 anterior implants in the mandible. In the maxilla, the tilted implants were positioned just anterior to the maxillary sinus. The drill protocol followed the manufacturer's guidelines. The implant sites were usually underprepared avoiding countersinking to engage as maximum cortical support bone as possible. The recommended drill sequences for soft bone type IV, medium type II and type III, and dense type I bone were followed. A manual surgical torque wrench (Adin) was used to check the final torque of the implant. In this case of immediate implant placement, the soft tissues were readapted to obtain a primary closure around the abutments and fresh extraction sites and then sutured back into position with interrupted resorbable 4.0 vicryl (Ethicon). Straight, multiunit abutment, internal (Adin) were used to achieve relative parallelism of the implants so that a rigid prosthesis would seat in a passive manner.

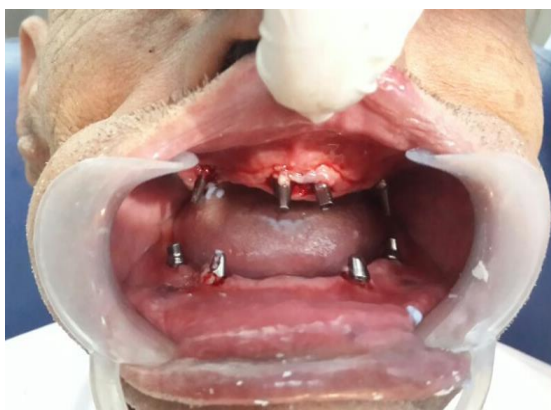

Fig. 3: After immediate placement of Abutments

Open-tray multiunit impression copings were placed on the abutments, and an impression was made with a custom open tray using precision impression material. Postoperatively, patient was given antibiotic 3

times per day over a period of 5 days. In addition, diclofenac sodium with serratiopeptidase were also used as an analgesic along with anti-inflammatory medication, methylprednisolone. Patient was instructed to avoid brushing and to use warm water rinses for the first postoperative week. A cold or room temperature soft diet for the first 24 hours following surgery was recommended, followed by a semisolid diet for the next 3 months.

Postoperatively, an orthopantomogram was taken to check the implant positions and the prosthetic components. The patient was scheduled for regular visits after 1 week, 2 weeks, 4 weeks postoperatively. No complications were reported during surgery or immediately after surgery.

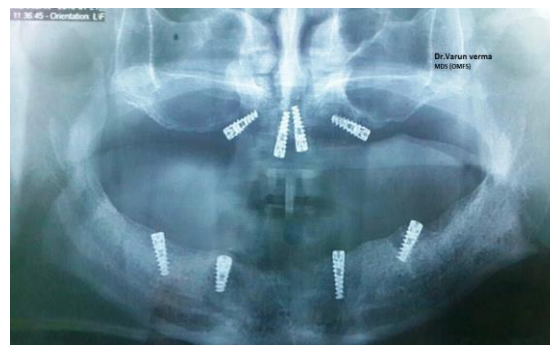

Fig. 4: Post-operative Orthopantomogram

Patient was recalled after 4 months and maxillary and mandibular fixed prosthesis was given. The patient was followed upto a period of 6 months and was satisfied with his new prosthesis functionally and esthetically.

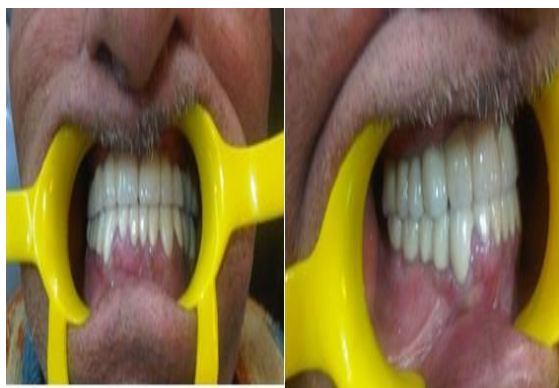

Fig. 5: After placement of complete prostheses

Discussion

Dental implants are traditionally placed in the vertical position. However, in the completely edentulous jaw as well as in the postextraction patient, problems such as minimum bone volume, poor bone quality, and the need for bone-grafting procedures prior to implant placement create some challenging conditions. For these situations, it has been demonstrated that distal tilting of implants preserves the relevant anatomical structures and allows for placement of longer implants with better cortical anchorage for prosthetic support.^{9,10} Tilting also increases the interimplant space, reduces cantilever length in jaws¹⁰⁻¹³ and reduces the need for bone augmentation. Good clinical outcomes have been reported in various studies using tilted implants.^{10,11,14}

This is in accordance with studies on biomechanical measurements, which demonstrated that tilted implants, when part of a prosthetic support, do not have a negative effect on the load distribution.¹⁵ In addition, a biomechanical rationale in tilting distal implants allows a reduction in cantilever length due to the more posterior position of the tilted implants, resulting in a more favorable stress distribution.^{16,17} The methodology of using tilted implants maximizing the use of the available bone without grafting has been reported, leading to successful clinical outcomes.⁹ This is in comparison to the traditional implant treatment in which insufficient bone in the posterior region requires bone-grafting procedures involving greater chair time for the patient as well as increased cost and increased number of procedures.

References

1. Heath MR. The effect of maximum biting force and bone loss upon masticatory function and dietary selection of the elderly. *Int Dent J.* 1982;32:345–356.
2. Wolff A, Gadre A, Begleiter A, Moskona D, Cardash H. Correlation between patient satisfaction with complete dentures and denture quality, oral condition, and flow rate of submandibular/sublingual salivary glands. *Int J Prosthodont.* 2003;16:45–48.
3. Ikebe K, Matsuda K, Morii K, Furuya-Yoshinaka M, Nokubi T, Renner RP. Association of masticatory performance with age, posterior occlusal contacts, occlusal

- force, and salivary flow in older adults. *Int J Prosthodont.* 2006;19:475–481.
4. Koshino H, Hirai T, Ishijima T, Ikeda Y. Tongue motor skills and masticatory performance in adult dentates, elderly dentates, and complete denture wearers. *J Prosthet Dent.* 1997;77:147–152.
5. Malo´ P, Nobre M. “All-on-Four” immediate-function concept with Bra´nemark system implants for completely edentulous mandibles. *Clin Implant Dent Relat Res.* 1998;1:12–19.
6. Mozzati M, Arata V, Gallesio G, Mussano F, Carossa S. Immediate postextractive dental implant placement with immediate loading on four implants for mandibular full-arch rehabilitation: a retrospective analysis. *Clin Implant Dent Relat Res* 2013;15:332-40.
7. Weinstein R, Agliardi E, Fabbro MD, Romeo D, Francetti L. Immediate rehabilitation of the extremely atrophic mandible with fixed full-prosthesis supported by four implants. *Clin Implant Dent Relat Res* 2012;14:434-41.
8. Babbush CA, Kanawati A, Kotsakis GA, Hinrichs JE. Patient-related and financial outcomes analysis of conventional full-arch rehabilitation versus the All-on-4 concept: A cohort study. *Implant Dent* 2014;23:218–24.
9. Aparicio C, Perales P, Rangert B. Tilted implants as an alternative to maxillary sinus grafting: a clinical, radiologic, and periosteal study. *Clin Implant Dent Relat Res.* 2001;3:39–49.
10. Krekmanov L, Kahn M, Rangert B, Lindstrom H. Tilting of posterior mandibular and maxillary implants of improved prosthesis support. *Int J Oral Maxillofac Implants.* 2000;15:405–414.
11. Del Fabbro M, Bellini CM, Romeo D, Francetti L. Tilted implants for the rehabilitation of edentulous jaws: a systematic review. *Clin Implant Dent Relat Res.* 2010;13(5):91-96.
12. Malo´ P, Rangert B, Nobre M. “All-on-Four” immediate-function concept with Bra´nemark system implants for completely edentulous mandibles: a retrospective clinical study. *Clin Implant Dent Relat Res.* 2003;5(suppl 1):2–9.
13. Malo P, Lopez I, Nobre M. The All on Four concept. In: Babbush C, Hahn J, Krauser J, eds. *Dental Implants: The Art and Science.* 2nd ed. St Louis, Mo: Saunders Elsevier;2010:435.
14. Malo´ P, Rangert B, Nobre M. All-on-4 immediate-function concept with Bra´nemark system implants for completely edentulous maxillae: a 1-year retrospective clinical study. *Clin Implant Dent Relat Res.* 2005;7(1):S88–S94.
15. Bellini CM, Romeo D, Galbusera F, et al. Comparison of tilted versus nontilted implant-supported prosthetic designs for the restoration of the edentulous mandible: a biomechanical study. *Int J Oral Maxillofac Implants.* 2009;24:511–517.
16. Bellini CM, Romeo D, Galbusera F, et al. A finite element analysis of tilted versus nontilted implant configurations in edentulous maxilla. *Int J Prosthodont.* 2009;22:155–157.
17. Zampelis A, Rangert B, Heijl L. Tilting of splinted implants for improved prosthodontic support: a twodimensional finite element analysis [published correction appears in *J Prosthet Dent.* 2008;99:167]. *J Prosthet Dent.* 2007;97(6 suppl):S35–S43.