



## Original Research Article

# Comparative evaluation of oxygenating agent “blue m gel” and traditional periodontal dressing “Coe-Pak” on patient preference parameters (Pain and wound healing) after surgical depigmentation – A split mouth study

Umesh Garg<sup>1</sup>, Navneet Kaur<sup>1\*</sup>, Gurpreet Kaur<sup>1</sup>

<sup>1</sup>Dept. of Periodontics and Oral Implantology, National Dental College and Hospital, Derabassi, Punjab, India



## ARTICLE INFO

## Article history:

Received 15-02-2024

Accepted 19-03-2024

Available online 01-05-2024

## Keywords:

Gingival pigmentation

Scalpel technique

Blue M gel

Active oxygen species

Coe-pak

## ABSTRACT

**Introduction:** Individuals with high lip line and gummy smile when accompanied with dark colored gingiva have an esthetic concern while smiling. For the management of gingival hyperpigmentation surgical technique with scalpel is still considered the gold standard, although healing may occur by secondary intension and oxygen is one of the essential nutrients for cellular metabolism and production of energy through ATP. It is also involved in collagen synthesis, oxygenative killing of bacteria and angiogenesis.

**Aim & Objectives:** To clinically evaluate and compare the effectiveness of oxygenating agent (Blue M Gel) and traditional periodontal dressing COE-PAK on patient preference parameters (pain and wound healing) after surgical depigmentation.

**Materials and Methods:** This split-mouth randomized clinical trial was conducted on 5 non-smoking individuals aged 20–40 years irrespective of gender with maxillary or mandibular physiologic gingival pigmentation class (III) and (IV) according to the Dummett–Gupta Oral Pigmentation Index (10 treated sites) who had requested an esthetic treatment for gingival hyperpigmentation of the maxillary or mandibular gingiva. The maxilla or the mandible was randomly divided into two symmetrical parts i.e. from the right second premolar to the midline and from the midline to the left second premolar—to receive either Blue M gel or Coe-Pak as a periodontal dressing after surgical depigmentation with a scalpel. Patient preference parameters such as pain was assessed after 24 hours and 7 days of intervention and re-epithelisation index with toluidine blue was assessed after 1 week and 1 month of intervention.

**Results:** The result of the study demonstrated that pain score and re-epithelisation score was less in Test group (Blue M Gel) as compared to control group (COE-PAK) and was found to be statistically significant.

**Conclusion:** It can be concluded that Blue M gel can also be a better alternative as a periodontal dressing compared to COE-PAK due to its properties of better healing and decreasing post-operative pain.

This is an Open Access (OA) journal, and articles are distributed under the terms of the [Creative Commons Attribution-NonCommercial-ShareAlike 4.0 License](https://creativecommons.org/licenses/by/4.0/), which allows others to remix, tweak, and build upon the work non-commercially, as long as appropriate credit is given and the new creations are licensed under the identical terms.

For reprints contact: [reprint@ipinnovative.com](mailto:reprint@ipinnovative.com)

## 1. Introduction

Aesthetic dentistry targeted at designing the perfect smile which is only delivered by a harmonious combination of both soft and hard tissue in the oral cavity. Gingival aesthetics along with the biological and functional demand are required to meet the need of the beauty in conscious

society. An aesthetically pleasing smile not only depend on the hard tissue components such as tooth position, size or shape, it also depends on the soft tissue components such as colour of the gingiva, amount of gingival display during smile and the framing of the lips. Colour of the gingiva may play a primary role in overall aesthetics of the soft tissue.<sup>1</sup> The factors which may vary the colour of the gingiva are number and size of blood vessels, thickness of epithelium, degree of keratinization and various pigments associated

\* Corresponding author.

E-mail address: [kaurparneet1963@gmail.com](mailto:kaurparneet1963@gmail.com) (N. Kaur).

with gingival epithelium.<sup>2</sup>

Periodontal surgical procedure provides a comprehensive treatment plan when there is an aesthetic concern and is considered the backbone of the aesthetic dentistry. Aesthetically there are various common gingival problems such as hyperpigmented gingiva unequal gingival contour, loss of interdental papilla, presence of black triangles, diastema formation and exposure of the root surface. Various pigments such as melanin, carotenoids, reduced haemoglobin and oxy-haemoglobin present in the oral mucosa may contribute as one of the factors which may affect the colour of the gingiva. If these pigments may start depositing in an excessive amount in the oral mucosa or in gingival soft tissue it may result in hyperpigmentation like condition.<sup>3</sup> Gingival hyperpigmentation is believed to be a genetic trait in the general population and is termed as physiologic racial gingival pigmentation. Hyperpigmentation usually does not present a medical problem; however the patients usually complain of dark black gums which seems to be unaesthetic and is not acceptable by the patient.

Melanin is endogenous non-haemoglobin derived brown coloured pigment usually produced by melanocyte cells which are present in stratum basale layer of the epithelium.<sup>4</sup> During gingival hyperpigmentation there is an excessive deposition of melanin granules which is produced by melanoblasts and intertwined in between the epithelial cells of stratum basale and supra basale cell layer. Highest gingival pigmentation is usually seen in attached gingiva and in interdental papilla which is around 25.4% and least involved is the marginal gingiva which is around 10.2%.<sup>5</sup> Gingival depigmentation is an aesthetic perioplastic surgical procedure which is commonly performed for the removal or reduction of melanin pigmentation by various techniques<sup>4</sup> such as de-epithelisation or scraping with scalpel and gingival abrasion technique using diamond bur, cryosurgery, electrosurgery, acellular dermal matrix allografts and LASERS (semi-conductor diode laser and carbon dioxide laser).<sup>3,6</sup> Each and every technique has its own advantages and disadvantages with variable results.

Surgical depigmentation is the most common technique in which there is a removal of layer of gingival epithelium along with underlying connective tissue layer and healing is by secondary intension so that a new epithelial layer is formed without any melanin pigmentation. The advantage of this technique is patient satisfaction and improvement in the aesthetics of the patient. Healing is one of the complex and multicellular process that involves epithelial cells along with fibroblast, endothelial cells, macrophages and platelet cells.<sup>7</sup> Wound is the common tissue where oxygen is usually depleted and may involve compromised haemodynamic and lower tissue oxygen tissue delivery.<sup>8</sup> Chronic wounds without essential nutrients may not heal for months or years. Therefore, oxygen is an essential part of wound healing and

plays a primary role in wound contracture and formation of the granulation tissue during the healing process by secondary intension. Oxygen is rapidly consumed during the wound healing therapies and is designed to supplement in the form of hyperbaric oxygen therapy or ozone therapy.

Recently, ozone therapy is one of the methods used to optimise the wound healing process in the oral cavity. A team of dental surgeon (Dr. Peter Blijdrop) in Netherland developed an active oxygen-based product (BLUE M GEL) with an intension to accelerate the healing process by angiogenic stimulation and antibacterial effect when applied on the local area. Blue M gel is composed of sodium perborate, Xylitol, Lactoferrin and glucose oxidase enzyme derived from honey. This is the new product used in dental applications which may release oxygen in adequate amount to promote angiogenesis and promotion of high tensile collagen fibres resulting in reduced scaring and risk of wound reoccurrence.<sup>9</sup> Commercially it is available as gel, toothpaste, mouthwash and mouth foam. Blue M gel has an anti-plaque and anti-gingivitis effect when applied topically however there is a very scant data in the literature regarding oxygen therapy for topical application.<sup>10</sup>

In the light of the benefits of the slow oxygen release for the enhancement of the wound healing and its beneficial effects in few clinical studies, the study was conducted with an aim to clinically evaluate and compare the effectiveness of oxygenating agent (Blue M Gel) and traditional periodontal dressing COE-PAK on patient preference parameters (Pain and wound healing) after surgical depigmentation.

## 2. Materials and Methods

This split mouth study was conducted in the Department of Periodontology and Oral Implantology, National Dental College and Hospital, Derabassi, Punjab. A total of 5 systemically healthy non-smoker patients in the age group of 20-40 years were selected based on the inclusion and exclusion criteria. The study was divided into two groups – Test Group (Blue M gel) and Control Group (COE-PAK Dressing), comprising of 5 subjects in each group. Each patient was given a detailed verbal and written description of the study and all the selected patients were required to sign an informed consent form prior to commencement of the study.

### 2.1. Study design

In the present clinical trial, a total of 5 patients in the age group of 20-40 years were selected and randomly allocated by toss of a coin to either the test group or the control group.

Test group- Surgical depigmentation with placement of Blue M gel (5 sites).

Control group- Surgical depigmentation with placement of COE-PAK dressing (5 sites).

## 2.2. Inclusion criteria

1. Patient who was co-operative, motivated and committed.
2. Patient with age group of 20- 40 years irrespective of gender were included.
3. Patients willing to follow recommended good oral hygiene practice and follow up regimen.

## 2.3. Exclusion criteria

1. Patients unable/unwilling to undergo surgical procedure.
2. Smokers, pregnant and lactating women, medically compromised patients.
3. Those with a history of periodontal surgery in less than 3 months.
4. Those with gingival pigmentation associated with other syndromes and lesions.

## 2.4. Pre-surgical protocol

A detailed medical and dental history was taken prior to the commencement of the surgery. Preoperative and postoperative clinical photographs were taken for documentation purposes. An informed verbal and written consent were obtained from the patient before the surgery.

## 2.5. Surgical procedure

Oral prophylaxis was done before the scheduled depigmentation Procedure. Subjects were advised to use 0.2% chlorhexidine gluconate mouthwash before the start of the procedure. Instructions were given regarding oral hygiene maintenance for its importance for the success of depigmentation procedure.

The depigmentation procedure was performed using a conventional scalpel. Subsequently, one of the two dressings was applied, and an interval of one week was maintained between the two halves to assess the pain and re-epithelisation indices. Each half underwent the following steps: Local anesthesia was given with 2% lidocaine (1:80000), and the entire pigmented layer of gingival epithelium in addition to an underlying layer of connective tissue was removed by abrasion with a no. 15 surgical blade. The depigmentation procedure was performed from the mucogingival junction to the base of the interdental papilla. Direct pressure was applied with a sterile gauze to control hemorrhage during the surgical procedure. The depigmented area was covered with the conventional Coe-Pak periodontal dressing in the control group, whereas the Blue M oxygen gel was applied to cover the depigmented area in the test group.

## 2.6. Post-surgical follow up

Post-operative check-up was done after 24 hours. Regular follow up of all patients was done after 1 week and 1 month.

## 2.7. Clinical parameters

### 2.7.1. Assessment of level of gingival hyperpigmentation

Assessment of level of gingival hyperpigmentation was assessed by means of Dummet–Gupta Oral Pigmentation (DOP) index.<sup>11</sup>

**Table 1:** Scoring criteria for DOP

Score	Description
1	No clinical pigmentation
2	Mild clinical pigmentation
3	Moderate clinical pigmentation
4	Heavy clinical pigmentation

### 2.7.2. Visual analysis scale measurement

The patients were instructed for charting of the VAS. Patients were asked to chart their perception on pain, bleeding over the first week healing period after 24 hours and after 7 days using a VAS with equal units from 0 to 10 (on a line of 10 cm), with 0 designating as no bleeding/pain to 10 for severe excruciating pain/ bleeding.

### 2.7.3. Evaluation of Re-epithelization

For the clinical evaluation of re-epithelization of tissue, toluidine blue was applied 1 week after the surgical depigmentation procedure both on the test group and control group. If the tissue stained with toluidine blue, this showed incomplete Re-epithelization and if the tissue does not take up the toluidine blue stain this showed complete Re-epithelization.<sup>12</sup>

## 2.8. Statistical analysis

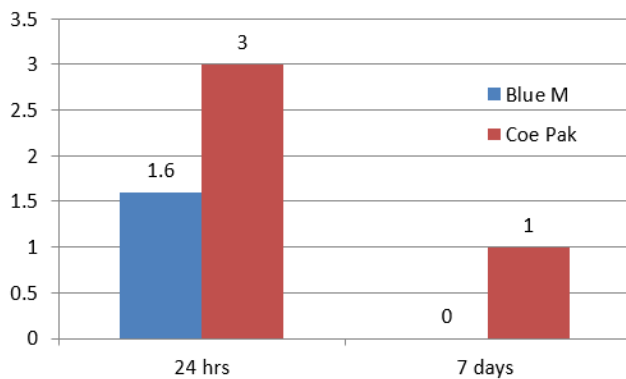
The data for the present study was entered in the Microsoft Excel 2007 and analyzed using the SPSS statistical software 19.0 Version. The descriptive statistics included mean, standard deviation. The intragroup comparison for the different time intervals was done using paired t test to find the difference between the individual time intervals. The level of the significance for the present study was fixed at 5%. The intergroup comparison for the difference of mean scores between two independent groups was done using the unpaired/independent t test.

Mean  $\pm$ SD pain score values were computed after 24 hours and 7 days among patients representing 2 groups as shown in Table 3 and Graph 1. The mean pain score at the 24 hours was  $1.60 \pm 0.54$  and  $3.00 \pm 0.010$  in the test group (Blue M gel) and control group (COE-PAK) respectively. At the 7<sup>th</sup> day, mean pain score was  $0.00 \pm 0.00$  in the test

**Table 2:** The criteria of Ishii et al. for re-epithelisation scoring.<sup>13</sup>

Evaluation	Score			
	1	2	3	4
Bleeding	None	Slight	Moderate	Severe
Pain	None	Slight	Moderate	Severe
Difficulty of procedure	Very easy	Easy	Difficult	Impossible
Wound healing	Complete epithelialization	Incomplete epithelialization	Ulcer	Tissue defect or necrosis

group (Blue M gel) and  $1.00 \pm 0.010$  in control group (COE-PAK). The pain score was significantly higher in the control group (COE-PAK) as compared to test group (Blue M gel) at 24 hours and 7 days.

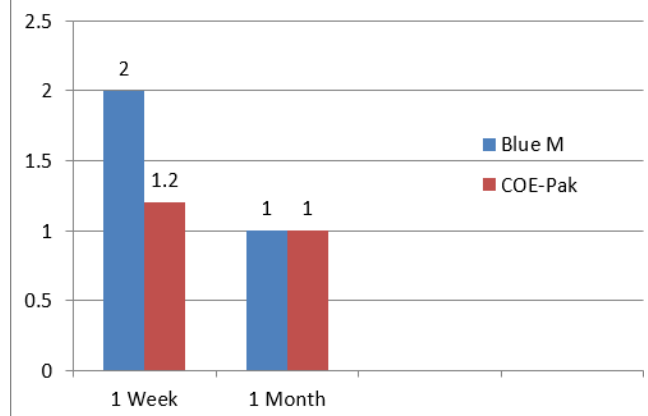


Graph 1: Inter group comparison of pain score based on VAS scale at 24 hours and 7 days

Mean  $\pm$ SD Re-epithelization values were computed at 1 week and 1 month among patients representing 2 groups as shown in Table 4 and Graph 2. The mean epithelization score at the 1 week was  $2.00 \pm 0.01$  and  $1.20 \pm 0.44$  in test group (Blue M gel) and control group (COE-PAK) respectively. At the 1 Month, mean epithelization score was  $1.00 \pm 0.010$  and  $1.00 \pm 0.010$  both in the test and control group. The epithelization score was significantly higher in the control group (COE-PAK) as compared to test group (Blue M gel) at 1 Week and at 1 month. There was no statistically significant difference in the epithelization score between test and control group.

### 3. Discussion

Surgical removal of the pigmentation using scalpel technique is one of the earlier techniques and is still considered as gold standard. Scalpel surgery can cause bleeding during and after the procedure, discomfort caused by the open surgical wound requires a periodontal dressing to protect the area of surgery for 7 to 10 days. Since the open surgical wound may heals with secondary intention, adding to the postoperative discomfort. Oral cavity is pool of microorganisms and during the mastication or any type of trauma may delay and slows down the normal sequence



Graph 2: Inter group comparison of epithelization scores between test group and control group after 1 week and 1 month

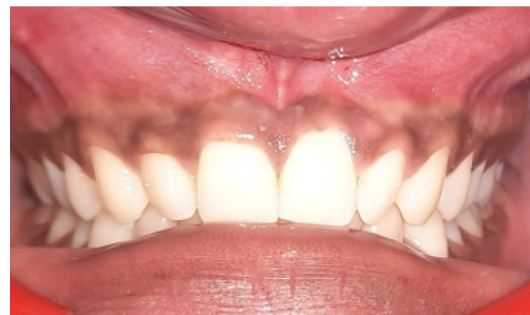

Figure 1: Pre-operative view

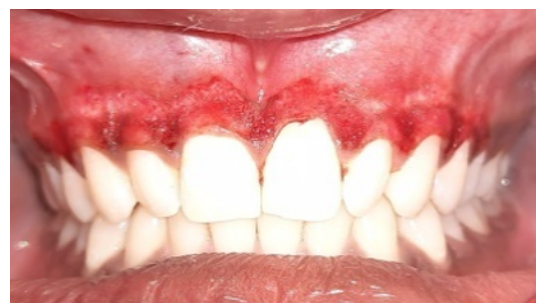

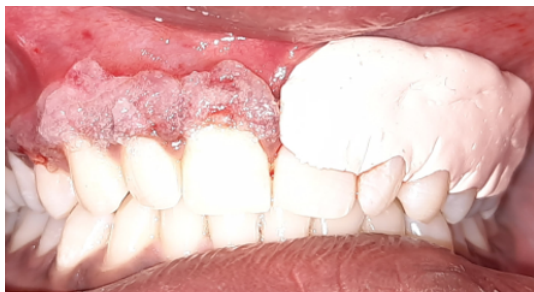Figure 2: Removal of pigmented layer with scalpel technique

**Table 3:** Inter group comparison of pain scores between test group and control group after 24 hours and 7 days

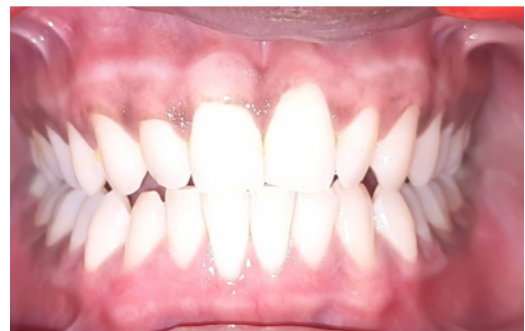Time Interval	Groups	Mean±SD	Std. Error Mean	P value
24 hours	Test Group (Blue M)	1.600±0.547	0.244	0.001 (Sig)
	Control Group (COE-PAK)	3.000±0.010	0.010	
7 days	Test Group (Blue M)	0.000±0.000	0.000	0.001 (Sig)
	Control Group (COE-PAK)	1.000±0.010	0.000	

**Table 4:** Inter group comparison of Re-epithelization scores between test group and control group after 1 week and 1 month

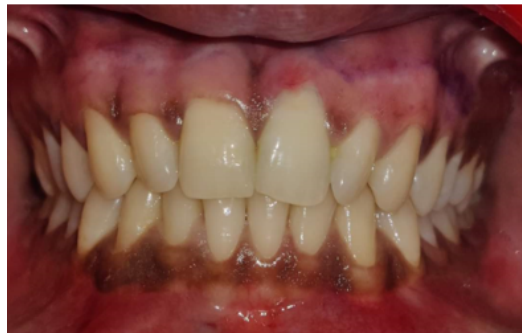Time Interval	Groups	Mean±SD	Std. Error Mean	P value
1 Week	Test Group (Blue M)	2.00±0.01	0.010	0.004 (Sig)
	Control Group (COE-PAK)	1.20±0.44	0.200	
1 Month	Test Group (Blue M)	1.000±0.01	0.010	1.00 (non-Sig)
	Control Group (COE-PAK)	1.000±0.01	0.010	



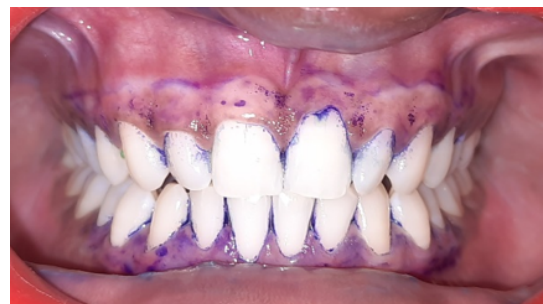**Figure 3:** Placement of COE-PAK & Blue M gel on respective sites



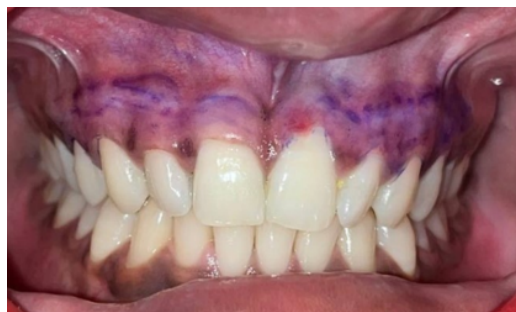**Figure 6:** Post-operative view after 1 month



**Figure 4:** Post-operative after 1 week



**Figure 7:** Toluidine blue staining to evaluate Re-epithelization after 1 month



**Figure 5:** Toluidine blue staining to evaluate Re-epithelization after 1 week

of the healing process. Wound healing is a complex and dynamic process requiring an appropriate environment to promote healing. Wound healing is a complicated process comprised of four constant, intersecting, and programmed stages, the events of which must occur in a specific order. Haemostasis, inflammation, proliferation, and maturation or remodelling are the main four stages of wound healing. Each of these stages is important in providing the healing process to progress.<sup>14</sup> Evidence indicates that oral wounds can be accompanied by postoperative pain and discomfort, the magnitude of which is related to the surgical approach used, the size of the wound, and the time it takes for the

wound to heal/epithelialize. Scarring is although rare in oral wounds, can occur under certain circumstances.

Wound dressings are an important component of wound management after periodontal surgery. Proper dressing should maintain a moist environment, eliminate excessive exudate, and create a strong barrier against bacterial or fluid contamination to facilitate wound healing. Topical oxygen therapy, hyperbaric oxygen therapy, ozonated therapy or gas plasma therapy has been used recently to induce angiogenesis in oral wound healing. Topical oxygen is used in the form of gel, mouthwashes or toothpaste in post-periodontal surgery and in peri-implantitis cases.

Oxygen supplementation during wound healing enhanced the oxidative killing of bacteria, stimulation of angiogenesis, accelerate extracellular matrix formation, increased proliferation of fibroblasts, and collagen deposition, thereby enabling faster healing. Oxygen released Blue M gel selectively eradicates the anaerobic bacteria associated with periodontitis to promote the recovery of a health-compatible oral flora.<sup>15</sup> Blue M gel can be considered as a good alternative for traditional periodontal dressing Coe-Pak after gingival depigmentation having pain-reduction properties, enhancement of wound healing and postoperative re-epithelialization.<sup>16</sup> The formulation of Blue M gel contains sodium perborate which may acts as a steady source of active oxygen.<sup>17</sup> It is a key active component and is required for plaque control and facilitate wound healing. When it comes into contact with tissue fluids, it creates a chemical process of hydrolysis and end product is released as hydrogen peroxide and boric acid at low concentrations. Hydrogen peroxide further releases the nascent oxygen to enhance wound healing and acts as a bactericidal. Oxygen which is released from the Blue M gel favours the oxygen therapy by increasing cellular metabolism, collagen synthesis, facilitate the release of growth factor especially VEGF and FGF, stimulation of angiogenesis and have bactericidal action.<sup>18</sup>

Because of the slow releasing oxygen product Blue M gel exhibit anti-infective, anti-inflammatory action, bactericidal and prevents the growth of the biofilms causing oral infections. Therefore, the randomized, split mouth study of surgical depigmentation was conducted on 10 sites in 5 patients within the age group of 20-40 years, presenting with either maxillary or mandibular physiologic gingival pigmentation. On one side Blue M gel was placed and on the other side Coe-Pak was placed as a dressing after surgical depigmentation. Patient preference parameter pain was assessed after 24 hours and 7 days of intervention and re-epithelisation was assessed after 1 week and 1 month. The rationale of periodontal dressings is to aid in reducing postoperative discomfort and post-operative pain. Regarding the pain perception score after 24 hours and 7 days of intervention, the pain score was found to be statistically significant in pain and discomfort experienced

by them in both the groups. Blue M gel group showed less pain score as compared to COE-PAK periodontal dressing. Blue M gel has the property of anti-inflammatory, anti-infective and enhances the immune cell function. Also, it has a controlled release of oxygen molecules which reverses the hypoxia process. Similarly, Mattei et al 2020 and 2021 used blue® m oxygen therapy to reduce postoperative pain and lesser inflammatory process successfully in test group as compare to the control group.<sup>19,20</sup>

Surgical wound area is usually covered with periodontal dressing COE-PAK for 7-14 days after periodontal surgery. Studies in the literature concluded that periodontal dressing may accelerates the wound healing process. The result of present study showed that there was a statistically significant difference in mean epithelisation score in between two groups after 1 week and non-significant difference after 1 month in between two groups. Blue M gel showed faster re-epithelization as compared to COE-PAK periodontal dressing. Blue M gel exerts the property of neovascularization, stimulation, and formation of new blood cells (angiogenesis) and increase in the production of new fibroblasts and high tensile strength collagen fibers.<sup>21</sup> However, COE-PAK dressing act as a physical barrier to protect the open wound and does not possess any effect on the wound healing process or antibacterial activity. Similar result was found in the study conducted by Juliana et al 2022 and Imano M et al 2019 concluded that Blue M gel optimize the process of tissue healing and faster reepithelization.<sup>16,22</sup>

In the literature, there are clinical studies, case report and series, and randomized controlled clinical trials which proves the positive outcomes with topical application of oxygen therapy. Although the present study is only limited to smaller sample size and the data in the literature is very scant and needs more long-term clinical investigation and their usage in different surgical procedures to evaluate the curative and novel oral care therapy in clinical practice.

#### 4. Conclusion

Hypoxia in the wound healing may result in tissue injury because during wound healing it requires more energy for cell growth, proliferation, and angiogenesis, and also for the removal of bacteria and foreign debris. Furthermore, abundant supply of oxygen is required to maintain neovascularization and epithelialization. Topical oxygen therapy with Blue M gel products can be considered novel oral care therapy in clinical practice. It is easy to handle, safe and effective treatment in oral wounds with topical application of oxygen.

Within the limitations of the study, Blue M Gel can be the better alternative as a periodontal dressing and effective adjunctive therapy for enhancement of wound healing. Based on the result of the study, Blue M oxygen gel after surgical depigmentation enhanced wound healing, stimulates rapid re-epithelisation, and less postoperative

pain as compared to the conventional COE-PAK dressing.

## 5. Source of Funding

None.

## 6. Conflict of Interest

None.

## References

- Kaur H, Jain S, Sharma R. Duration of reappearance of gingival melanin pigmentation after surgical removal a clinical study. *J Indian Soc Periodontol.* 2010;14(2):101–5.
- Raaman AR, Pratebha B, Jananni M, Saravanakumar R. Computerized Intensity Values to Objectivize Dummett Gupta Classification of Physiologic Gingival Pigmentation. *Clin Adv Period.* 2015;5(2):140–5.
- Kathariya R, Pradeep AR. Split mouth de-epithelization techniques for gingival depigmentation: A case series and review of literature. *J Indian Soc Periodontol.* 2011;15(2):161–8.
- Murthy BM, Kaur J, Das R. Treatment of gingival hyperpigmentation with rotary abrasive, scalpel, and laser techniques. A case series. *J Indian Soc Periodontol.* 2012;16(4):614–9.
- Ponnaiyan D, Gomathy L, Anusha J. The correlation of skin color and gingival pigmentation patterns in a group of South Indians in Tamil Nadu, India. *Oral Health Dent Manag.* 2013;4(2):54–8.
- Yousuf A, Hossain M, Nakamura Y, Yamada Y, Kinoshita J, Matsumoto K, et al. Removal of gingival melanin pigmentation with the semiconductor diode laser: a case report. *J Clin Laser Med Surg.* 2000;18(5):263–6.
- Häkkinen L, Uitto VJ, Larjava H. Cell biology of gingival wound healing. *Periodontol 2000.* 2000;24:127–52.
- Frykberg RG, Banks J. Challenges in the treatment of chronic wounds. *Adv Wound Care (New Rochelle).* 2015;4(9):560–82.
- Tawfick WA, Sultan S. Technical and clinical outcome of topical wound oxygen in comparison to conventional compression dressings in the management of refractory nonhealing venous ulcers. *Vasc Endovascular Sur.* 2013;47(1):30–7.
- O'neil TC. Antibacterial properties of periodontal dressings. *J Periodontol.* 1975;46(8):469. doi:10.1902/jop.1975.46.8.469.
- Dummett CO. Physiologic pigmentation of the oral and cutaneous tissues in the Negro. *J Dent Res.* 1946;25(6):421–32.
- Sridharan G, Shanka AA. Toluidine blue: A review of its chemistry and clinical utility. *J Oral Maxillofac Pathol.* 2012;16(2):251–5.
- Ishii S, Aoki A, Kawashima Y, Watanabe H, Ishikawa I. Application of an Er:YAG laser to remove gingival melanin hyperpigmentation: Treatment procedure and clinical evaluation. *J Jap Soc Laser Dent.* 2002;13:89–96.
- Guo S, Dipietro LA. Factors affecting wound healing. *J Dent Res.* 2010;89(3):219–9.
- Sy K, Flamme J, Maquet H, Chai F, Nuet C, Siepmann F, et al. Antimicrobial effect and physical properties of an injectable “active oxygen” gel for the treatment of periodontitis. *Am J Dent.* 2020;33(6):305–9.
- Juliana H, Tarek S. Comparative study of the effect of BlueM active oxygen gel and coe-pack dressing on postoperative surgical depigmentation healing. *Saudi Dent J.* 2022;34(4):328–34.
- Hyslop PA, Hinshaw DB, Scraufstatter IU, Cochrane CG, Kunz S, Vosbeck K, et al. Hydrogen peroxide as a potent bacteriostatic antibiotic: implications for host defense. *Free Radic Biol Med.* 1995;19(1):31–7.
- Eisenbud DE. Oxygen in wound healing: nutrient, antibiotic, signaling molecule, and therapeutic agent. *Clin Plast Surg.* 2012;39(3):293–10.
- Mattei BM, Imanishi SA, Ramos GDO, De Campos P, Weiss SG, Deliberador TM, et al. Mouthwash with active oxygen (blue® m) induces keratinocytes proliferation. *Open J Stomatology.* 2020;10(6):107. doi:10.4236/ojst.2020.106012.
- Mattei BM, Imanishi SA, Ramos GDO, De Campos P, Weiss SG, Deliberador TM, et al. Mouthwash with active oxygen (blue® m) reduces postoperative inflammation and pain. *Case Rep Dent.* 2021;p. 5535807. doi:10.1155/2021/5535807.
- Han SJ, Jeong SY, Nam YJ, Yang KH, Lim HS, Chung J, et al. Xylitol inhibits inflammatory cytokine expression induced by lipopolysaccharide from Porphyromonas gingivalis. *Clin Diagn Lab Immunol.* 2005;12(11):1285–91.
- Imano M, Chaves L, Storrer C, Amaral CFD, Candido B, Deliberador TM. Use of oxygen gel as an optimizer of tissue healing in donor and recipient areas along with the free gingival grafting technique. *IN Perio limited.* 2019;4(6):1161–9.

## Author biography

**Umesh Garg**, Post Graduate Student

**Navneet Kaur**, Reader

**Gurpreet Kaur**, Professor and HOD

**Cite this article:** Garg U, Kaur N, Kaur G. Comparative evaluation of oxygenating agent “blue m gel” and traditional periodontal dressing “Coe-Pak” on patient preference parameters (Pain and wound healing) after surgical depigmentation – A split mouth study. *IP Int J Periodontol Implantol* 2024;9(1):31-37.