



## Case Report

# Non-surgical periodontal therapy in severe chronic periodontitis patients associated with Type II Diabetes mellitus: A case report

Vandana A Pant<sup>1</sup>, Dilip Kumar Maurya<sup>1,\*</sup>, Meghna Nigam<sup>1</sup>

<sup>1</sup>Dept. of Periodontology, Babu Banrasi Das College of Dental Sciences, Lucknow, Uttar Pradesh, India



### ARTICLE INFO

#### Article history:

Received 28-01-2022

Accepted 08-02-2022

Available online 31-03-2022

#### Keywords:

Diabetes mellitus type II

Periodontal abscess

Nonsurgical management

### ABSTRACT

Diabetes mellitus is a condition that affects both adults and children and is caused by insulin insufficiency, insulin resistance, or both. Gingivitis, periodontitis, recurrent periodontal abscess, delayed healing after extraction, etc. are the most common oral symptoms. Early identification and management of diabetes mellitus with simultaneous periodontal therapy can improve the oral complications. Close coordination between the medical and dental teams can benefit the diabetic individuals. The goal of this article was to raise awareness regarding the oral signs and complications of diabetes mellitus.

This is an Open Access (OA) journal, and articles are distributed under the terms of the [Creative Commons Attribution-NonCommercial-ShareAlike 4.0 License](https://creativecommons.org/licenses/by-nc-sa/4.0/), which allows others to remix, tweak, and build upon the work non-commercially, as long as appropriate credit is given and the new creations are licensed under the identical terms.

For reprints contact: [reprint@ipinnovative.com](mailto:reprint@ipinnovative.com)

## 1. Background

Diabetes mellitus and periodontitis are the two most common, chronic non-communicable diseases affecting population over worldwide. Amongst the various complications, periodontitis is recognised as one of “the sixth complication” of diabetes.<sup>1</sup> The association between the two disease is more complex than this, and there is clear evidence of two-way bidirectional relationship between the diabetes and periodontitis.

Diabetes mellitus is a group of various metabolic disorders which are indicated by chronic hyperglycaemia with disturbances of carbohydrates, fat and protein metabolism ensued from the defects in insulin production, insulin action or both.<sup>2</sup> Diabetes has far-reaching consequences on multiple body systems and organs, including immune system (increased risk of infections), eyes (retinopathy) and oral manifestations.

The current classification of diabetes is based upon the pathophysiology of each form of the disease.<sup>2</sup> Type 1 diabetes results from cellular mediated autoimmune

destruction of pancreatic  $\beta$ -cells, usually leading to complete loss of insulin secretion. Type 2 diabetes, on other hand results from the insulin resistance, caused by impaired insulin secretion which alters the use of innate produced insulin at the target cells. Type 2 diabetes is more common as people become older, and it's frequently connected to lifestyle factors including obesity and lack of exercise.

Currently, there are three different ways to diagnose diabetes namely first RBS (Random blood Sugar), second GTT (Glucose Tolerance Test) and third HbA1c (Glycated haemoglobin). HbA1c  $\geq 6\%$  confirms diabetes while the severity in score correlates with the diabetic complications. The inter-relationship between the periodontitis and diabetes suggests the tendency of systemic disease to oral infection and vice versa.

Greater gingival inflammation were seen in adults with type 2 diabetes than in non-diabetic controls, with the highest level of inflammation in subjects with poor glycaemic control.<sup>3</sup> The function of immune cells, which include neutrophils, monocytes, and macrophages also gets altered in diabetes.<sup>4</sup> Neutrophil adherence, chemotaxis, and phagocytosis are often impaired, while monocyte and macrophages hyper-responsiveness is seen that significantly

\* Corresponding author.

E-mail address: [dkmmystery91@gmail.com](mailto:dkmmystery91@gmail.com) (D. K. Maurya).

increase periodontal destruction.<sup>5</sup> The majority of evidence suggests that diabetes also increases the risk of periodontitis. Longitudinal research has also shown the incidence of periodontitis was 2.6-fold higher in diabetic subjects than in non-diabetic patients.<sup>6–8</sup>

## 2. Procedure: Case report

A 56-year-old male patient reported to the department of periodontology at Babu Banarsi Das College of Dental Sciences complaining of sensitivity and tooth mobility in the upper front and upper left back teeth region of jaw since one month. Patient reported labial swelling and pus discharge with respect to 21,22,23.

Patient is diabetic since last 3 years for which he was taking ayurvedic medication and antihypertensives since last 2 years. He visited to a dentist for the same problem and was prescribed some medication and handmade toothpaste including some analgesic but to no relief. He is also chronic tobacco chewer since 15years.

Extraoral examination revealed swelling on the left side of the face extending from the outer canthus of left eye through the lateral wall of the nose up to the vermilion border of the upper lip (Figure 1A). Submandibular and cervical lymph node were not palpable.

Intraoral examination revealed moderate stains, calculus deposits and generalized gingival inflammation deposits (Figure 1B). There was swelling, suppuration and draining sinus tract on labial aspect of 21,22,23 (Figure 1C). The colour of the gingiva was reddish pink, which was mildly enlarged, with blunt and rolled out margins. The consistency was soft and oedematous, while stippling was absent and the position of gingival margin was 2mm coronal to CEJ in maxillary anteriors (and apical to the CEJ in mandibular anteriors) with bleeding on probing. Cervical abrasion was seen with respect 21,22,23,24. 21,22,23 and 27 showed grade III mobility. There was moderate swelling in the mid palatal region and was fluctuant (Figure 1D). Generalised increase in periodontal probing depth and CAL  $\geq 7$ mm was recorded. Grade I furcation involvement was seen in 16,26,37,47. Occlusal caries was present w.r.t 25 and root stump w.r.t 45,46. All the teeth were vital.

Various investigation was advised: 1. Radiographic (OPG), 2. blood sugar level, 3.CBC, 4. HbA1c and 5. Covid test RTPCR.

Radiographic examination revealed generalized moderate horizontal bone loss. Furcation involvement w.r.t.36, PDL widening w.r.t 18,17,16,21,22,23,24,26,36,47 and root stump w.r.t 45,46 (Figure 1E).

According to intraoral examination and radiographic examination following diagnosis were made: 1. Generalised severe chronic periodontitis modified by type 2 diabetes mellitus. 2 periodontal abscesses with respect to 21,22,23. Reversible pulpitis w.r.t 25.

Prognosis was hopeless w.r.t 27 due to severe bone loss.

### 2.1. Treatment

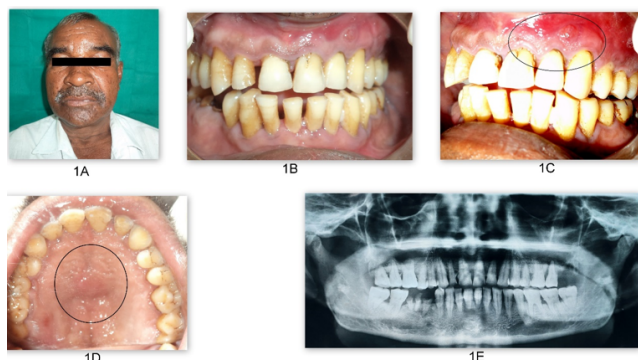
A joint effort of medical-dental treatment plan was devised together with the attending physician. In the first appointment, topical LA was given following which the abscess was drained in 21,22 and 23 by applying gentle digital pressure and subgingival irrigation was done with 5% Povidone-iodine (Betadine solution) in the tooth 21,22,23. Oral hygiene instructions were given and medications prescribed were as follows (Tab Amoxicillin 500mg + clavulanic acid 125mg BD, metronidazole 400mg BD, Aceclofenac 100mg + Paracetamol 325mg + Serratiopeptidase 15mg BD, metrogyl gel topical application, Pantoprazole (40mg) OD and Multivitamin OD) for 7 days. Patient was asked to use betadine mouth rinse twice daily for 2 weeks.

In second visit after 5days, re-evaluation and supragingival ultrasonic scaling was performed along with subgingival betadine irrigation. Result of test were as follows 1) covid test was negative, 2) CBC (Hb% 11.1%, WBC 8000/mm<sup>3</sup>, RBC 4.43mil/mm<sup>3</sup>, Platelets count 1,33,000/mm<sup>3</sup>, DLC (N62%, L29%, E05%, M04%, B00%)) 3) Fasting and PP blood sugar were 73.0mg/dl/127.0mg/dl) respectively while HbA1C values was significantly higher at 10.8% (estimated average glucose level was 263mg/dl). Patient was referred to the physician for management of high blood sugar level. He was prescribed vildagliptin 50mg OD for diabetes and tablet Telmikind 40mg OD for hypertension. Patient was reinforced for diet modification. The medication which was advised on 1<sup>st</sup> appointment was continued for another one week.

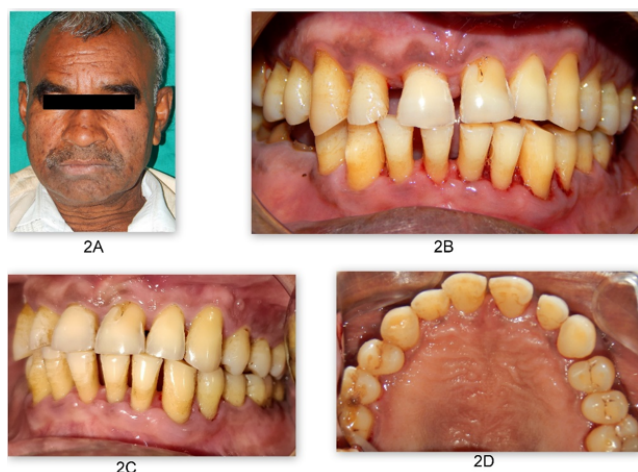In third visit after 7 days from 2<sup>nd</sup> visit, complete supragingival and subgingival ultrasonic scaling was performed with subgingival betadine irrigation. He was advised to continue betadine mouthrinse twice daily for another two weeks and rest of the medication was discontinued. He was reinforced for continuing medication of hypoglycaemic.

In fourth visit after 7days, re- evaluation was done where swelling and buccal sinus tract reduced with respect 22,23 (Figure 2A,B and C). Mobility reduced from grade III to grade II with respect 21,22,23. Resolution of palatal swelling was noted (Figure 2D). Patient was advised to continue with hypoglycaemics and anti-hypertensive medication to control the diabetes and hypertension. Patient was called after one month for the re-evaluation and monitoring of blood sugar level to plan for the extraction of hopeless teeth, restoration, further periodontal therapy, and subsequent rehabilitation.

After three-month follow-up, HbA1c value reduced from 10.8% to 7.3%. Mobility also reduced from grade II to grade I w.r.t 11,21,22,23,25 and 26.



**Fig. 1:** **A:** Facial view swelling seen below the left eye; **B:** Front view moderate stain and calculus, periodontal abscess wrt 21,22,23 and gingivitis; **C:** Lateral View periodontal abscess wrt 21,22,23; **D:** Palatal View palatal swelling seen just behind the rugae area; **E:** Orthopantomograph (OPG)



**Fig. 2:** **A:** Facial View: swelling resolved on below the left eye; **B:** Frontal view periodontal abscess wrt 21,22,23 and gingivitis were resolved; **C:** lateral view periodontal abscess resolved wrt 21,22,23; **D:** Palatal View Palatal swelling resolved.

### 3. Discussion

The present case demonstrates the successful periodontal treatment of a male diabetic patient manifesting periodontal abscess and chronic periodontitis. The patient's glycaemic control improved from 10.8% to 7.3% after the hypoglycaemic and antimicrobial medication. There is also robust evidence that patient with high blood glucose level will have severe effect on oral maintenance.<sup>9</sup>

Lalla et al<sup>10</sup> determined the oral manifestation of periodontitis in different age cohorts. He found that patient having history of diabetes reported 4.8 times higher prevalence of periodontal disease than non-diabetic subjects. In diabetic patient, CAL was higher in the age group of 15-55years. They also found that the rate of periodontal deterioration in diabetic people is due to poor glycaemic control, suggesting that precise metabolic

management is required to avoid periodontal problems. Uncontrolled diabetes causes the increased aggregation of advanced glycation end-product (AGEs) and impaired leukocyte function which stimulates additional periodontal tissues breakdown.

This case is a good example of association of multiple abscess due to high blood glucose level. The rationale for control of sugar level can be well co-related to the improvement of periodontal condition. Administration of antimicrobial lead to faster resolution of abscess. The reduction in HbA1C and subsequent remission of periodontal manifestations is sheer evidence of systemic periodontal relationship.

### 4. Conclusion

The oral manifestations of uncontrolled Type II diabetes on periodontium occur in mild to severe forms as in the present case which showed severe gingival inflammation with multiple periodontal abscess. The uncontrolled diabetes with HbA1C value of 10.8 % was associated with marked periodontal tissue destruction. The accurate diagnosis and sequential management of diabetes and non-surgical periodontal therapy is the key to successful resolution of symptoms. This case also demonstrates that systematic control of diabetes and periodontal treatment can result in remarkable improvements of systemic conditions and periodontal manifestation. To avoid risks that might interfere with treatment or its outcomes, the interdisciplinary coordination between dentist and attending physician plays a fundamental role in the treatment of both diabetes and periodontitis.

### 5. Declaration of Patient Consent

The authors certify that they have obtained all appropriate patient consent forms. In the form the patient has/have given his/her/their consent for his/her/their images and other clinical information to be reported in the journal. The patient understand that their names and initials will not be published and due efforts will be made to conceal their identity, but anonymity cannot be guaranteed.

### 6. Conflict of Interest

The authors declare that there is no conflict of interest.

### 7. Source of Funding

None.


### References

1. Loe H. Periodontal disease. The sixth complication of diabetes mellitus. *Diabetes Care*. 1993;16(1):329–34.
2. World Health Organization. WHO definition, diagnosis and classification of diabetes mellitus and its complications. In *Diagnosis and classification of diabetes mellitus*. 2nd ed; 1999.

3. Cutler CW, Machen RL, Jotwani R, Iacopino AM. Heightened gingival inflammation and attachment loss in type 2 diabetics with hyperlipidemia. *J Periodontol.* 1999;70(11):1313–21. doi:10.1902/jop.1999.70.11.1313.
4. Position Paper; Diabetes and Periodontal Diseases. *J Periodontol.* 1999;70(8):935–49. doi:10.1902/jop.1999.70.8.935.
5. Manouchehr-Pour M, Spagnuolo PJ, Rodman HM, Bissada NE. Comparison of neutrophil chemotactic response in diabetic patients with mild and severe periodontal disease. *J Periodontol.* 1981;52(8):410–5. doi:10.1902/jop.1981.52.8.410.
6. Nelson RG, Shlossman M, Budding LM. Periodontal disease and NIDDM in Pima Indians. *Diabetes Care.* 1990;13(8):836–40. doi:10.2337/diacare.13.8.836.
7. Miller LS, Manwell MA, Newbold D. The relationship between reduction in periodontal inflammation and diabetes control: A report of 9 cases. *J Periodontol.* 1992;63(10):843–8. doi:10.1902/jop.1992.63.10.843.
8. Grossi SG, Skrepinski FB, Decaro T. Treatment of periodontal disease in diabetics reduces glycosylated hemoglobin. *J Periodontol.* 1997;68(8):713–9. doi:10.1902/jop.1997.68.8.713.
9. Chapple IL, Genco R. EFPAAP working group 2 of the joint, diabetes and periodontal diseases: consensus report of the Joint EFP/AAP Workshop on Periodontitis and Systemic Diseases. *J Periodontol.* 2013;84(4):106–12.
10. Lalla E, Lamster IB, Schmidt AM. Enhanced interaction of advanced glycation end products with their cellular receptor RAGE: implications for the pathogenesis of accelerated periodontal disease in diabetes. *Ann Periodontol.* 1998;3(1):13–9. doi:10.1902/annals.1998.3.1.13.

### Author biography

**Vandana A Pant**, Professor and HOD

**Dilip Kumar Maurya**, Post Graduate Student  <https://orcid.org/0000-0002-4333-2879>

**Meghna Nigam**, Senior Lecturer

**Cite this article:** Pant VA, Maurya DK, Nigam M. Non-surgical periodontal therapy in severe chronic periodontitis patients associated with Type II Diabetes mellitus: A case report. *IP Int J Periodontol Implantol* 2022;7(1):23-26.