



Original Research Article

Assessment of inflammatory status of peri-implant soft tissue around functionally loaded immediate implants placed in periodontally compromised tooth extraction sockets

Kuruvilla Elizabeth^{1,*}, K R Biniraj¹, Emmatty Rishi¹, Paul P Tony¹, Jose Priya¹, K A Divyasree¹

¹Dept. of Periodontology, Royal Dental College, Chalissery, Kerala, India



ARTICLE INFO

Article history:

Received 28-02-2022

Accepted 07-03-2022

Available online 31-03-2022

Keywords:

Periimplantitis

Aspartate aminotransferase

periimplant mucosa

Extraction socket

ABSTRACT

The present study was aimed at assessment of the soft tissue condition around immediate implants used to replace periodontally compromised mandibular anterior teeth.

A longitudinal study was conducted on 17 functionally loaded immediate implants placed in periodontally compromised sockets at mandibular anterior region. Clinical and biochemical assessment of inflammatory status of peri-implant mucosa were recorded at 2nd week, 6th and 12th-month intervals after loading. Clinical parameters included modified Plaque Index (mPI), modified Bleeding Index (mBI), marginal soft tissue level (ML), Papilla Index (PI) and width of attached mucosa (AM). Biochemical parameter was the levels of Aspartate aminotransferase (AST) enzyme in peri-implant crevicular fluid (PCF).

Inter-comparison of observations were statistically analysed using repeated-measures ANOVA. The mean mPI score was 0.71, 0.41 and 0.53 at three intervals (p=0.354) indicating moderate score. The mean mBI was 1.06, 0.35 and 0.29 at various intervals (p=0.000), pointing reduced bleeding tendency. Throughout the study, 70.588% of sites had positive ML, suggesting soft tissue stability. Mean PI scores were 1.71, 2.06 and 2.65 and for AM were 2.41, 2.41 and 2.94 respectively at the three intervals, with a statistically significant p-value of 0.000 for both. The mean AST level in PCF was 1876.47 μ IU, 1729.41 μ IU and 2117.65 μ IU (p=0.431), pointing no increase in inflammation.

Considering the results obtained, implants under study exhibited no major inflammatory changes in the soft tissue, during the study period.

This is an Open Access (OA) journal, and articles are distributed under the terms of the [Creative Commons Attribution-NonCommercial-ShareAlike 4.0 License](https://creativecommons.org/licenses/by-nc-sa/4.0/), which allows others to remix, tweak, and build upon the work non-commercially, as long as appropriate credit is given and the new creations are licensed under the identical terms.

For reprints contact: reprint@ipinnovative.com

1. Introduction

A delayed implant placement following the traditional protocol after extraction can lead to reduction in bone height and an increase in soft tissue thickness that may result in altered crown-implant ratio. Hence, an immediate implant placement helps to preserve the bony socket and minimize crestal bone at these sites, as the residual ridge resorption is highest at the first 6 months after tooth extraction.¹

This becomes a challenge in a periodontally compromised site, as a previous history of periodontitis would keep it doubtful in determining the soft and hard tissue response and prognosis of such a treatment approach. Moreover, the mandibular anterior sextants are the commonest sites that demand immediate prosthetic replacements following extractions, as it comes in the esthetic zone. A long-term maintenance protocol becomes equally challenging for implants placed in such vulnerable sites, to make them inflammatory free following the functional loading. Thus, a longitudinal study was planned

* Corresponding author.

E-mail address: drelizabethkuruvilla@gmail.com (K. Elizabeth).

to evaluate and assess the soft tissue changes around immediate implants when used to replace periodontally compromised mandibular anterior teeth, that would bring into light the feasibility and long term prognosis of such a treatment approach.

The objective of the study was to assess the inflammatory status of peri-implant mucosa around such implants, using clinical and biochemical parameters at various intervals within a period of 12 months following its functional loading.

2. Materials and Methods

Sample selection for the study followed the principles outlined in the Declaration of Helsinki on clinical research involving human subjects. Written informed consent was obtained from all the participants of the study. A thorough case history was obtained and all the study sites were confirmed to be of immediate implants that had a preceding history of tooth being extracted due to periodontitis with \geq grade II mobility. These implants were functionally loaded following the regular protocol of healing period. Functionally loaded implants placed adjacent to natural teeth and with a fair or good simplified oral hygiene status having a gingival index score of ≤ 2 were only included as samples.

The original sample size required was 10, calculated using Epi Info software developed by CDC, USA.² The sample sites were increased to 17, to compensate for any dropouts and resultant follow-up bias.

Study protocol was explained and written consent was obtained from all the patients included in the study. The sample sites were implants completed 2 weeks of functional loading with final prosthesis. The study commenced with a baseline data assessment of 6 various parameters to assess the inflammatory status of peri-implant mucosa at 2 weeks following its loading (considered as Day 0). After this, assessment intervals were fixed to be at the end of 6th and 12th month.

Six parameters were utilized to assess the inflammatory status of peri-implant mucosa. The clinical parameters included modified Plaque Index (mPI),³ [Figure 1] modified sulcus Bleeding Index (mBI) by Mombelli et al,³ [Figure 2] measurement of marginal soft tissue level from adjacent tooth (ML) described by Oh et al.,⁴ [Figure 3] Papilla Index (PI) by Jemt⁵ [Figure 4] and measurement of width of attached mucosa at the midfacial aspect of implants (AM) [Figure 5]. Estimation of aspartate aminotransferase (AST) enzyme in the peri-implant crevicular fluid was the biochemical parameter used.

The biochemical assessment consisted of estimation of AST in PCF. 1 μ l of PCF sample was collected using microcapillary pipettes [Figure 6] and immediately transferred to a cryovial containing 99 μ l of phosphate buffer saline of pH 7.2 and was sent for biochemical

estimation. AST level in the sample was estimated on the same day with an autoanalyser.be provided.

3. Results

The data of observation of various parameters recorded at 2 weeks, 6th and 12th-month intervals following loading were tabulated and subjected to statistical analysis using repeated measures ANOVA for intercomparison. The statistical software used was Epi Info 7. A p-value of <0.05 was considered to be statistically significant.

The mean value obtained for modified Plaque Index (mPI) at the baseline, 6th month and 12th month were 0.71, 0.41 and 0.53 respectively. The p-value obtained was 0.354 comparing the three values. So it was inferred that there was no statistically significant change in mPI although there was clinical improvement in the plaque scores [Graph 1].

The modified Bleeding Index (mBI) had a mean of 1.06, 0.35 and 0.29 at the three recalls and the p-value was estimated to be 0.000, which was showing a statistically significant value. This shows a gradual reduction in the bleeding tendency of the sites from the baseline period (2 weeks) to the 12th month [Graph 2].

On comparing the marginal soft tissue levels (ML), 70.588% of the sites were having a positive level of marginal soft tissue, which means the soft tissue levels of these sites were apical to that of the adjacent teeth. The level maintained at the same rate throughout the study, suggesting a stable soft tissue throughout the study period [Graph 3].

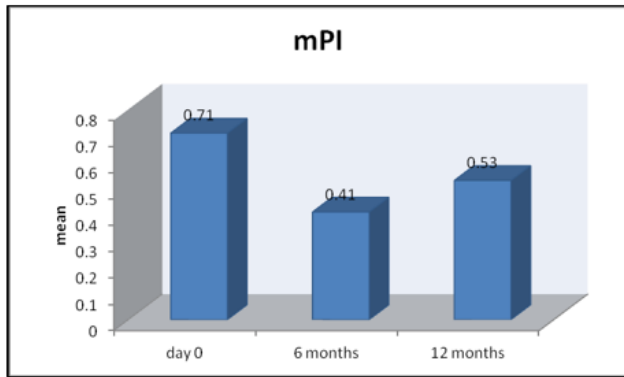
The analysis of Papilla Index (PI) had mean of 1.71, 2.06 and 2.65 at the three intervals respectively and the p value obtained was 0.000 suggesting a statistically significant difference. This indicates that there was a steady increase in the papilla growth from day 0 to 12th month, which is a positive factor in the study [Graph 4].

The mean width of attached mucosa (AM) at three recall visits were 2.41, 2.41 and 2.94 respectively ($p = 0.000$), which also shows a statistically significant difference. Hence, it can be inferred that there was an increase in the width of attached mucosa from day 0 to 12th month [Graph 5].

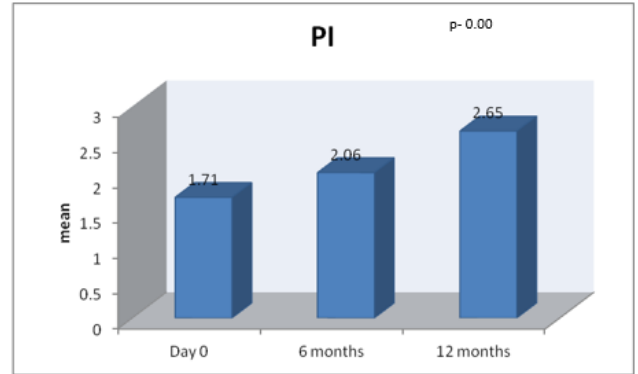
The mean level of AST was found elevated at all intervals of baseline, 6 months and 12 months at 1876.47 μ IU, 1729.41 μ IU and 2117.65 μ IU respectively. But the difference at each interval exhibited no statistically significant difference ($p=0.431$) indicating that the inflammatory status of peri-implant mucosa remained stable throughout the study period [Graph 6].

4. Discussion

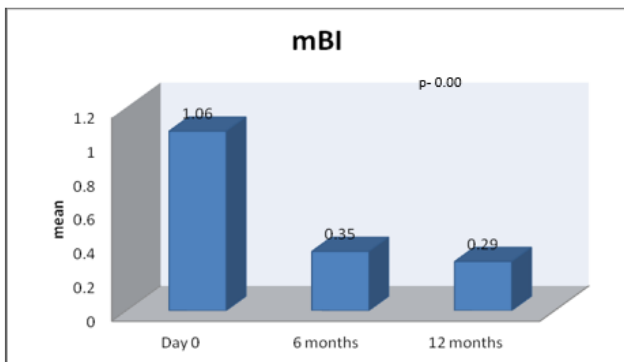
The present study was done to assess the inflammatory status of peri-implant mucosa of immediate implants placed in periodontally compromised tooth extraction sites in



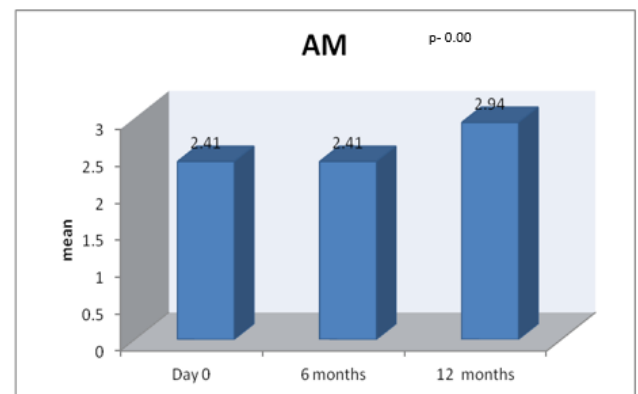
Graph 1: Comparison of modified plaque index at day 0, 6th month and 12th month



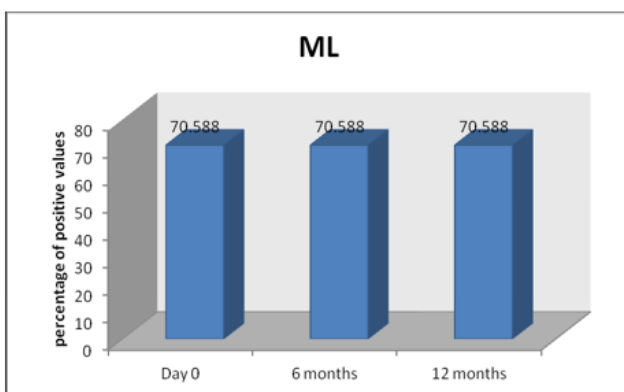
Graph 4: Comparison of Papilla Index at day 0, 6th month and 12th month



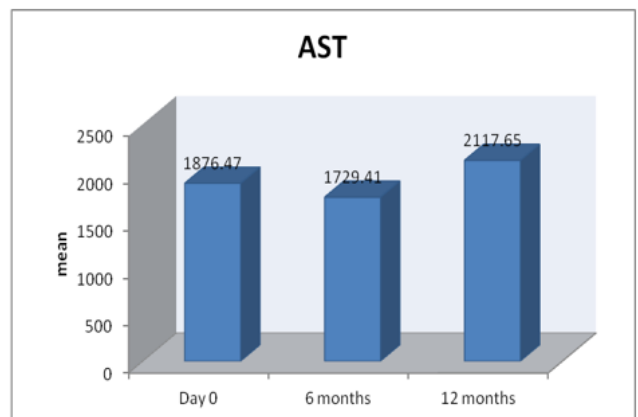
Graph 2: Comparison of modified Bleeding Index at day 0, 6th month and 12th month



Graph 5: Comparison of Attached Mucosa at day 0, 6th month and 12th month



Graph 3: Comparison of marginal soft tissue levels at day 0, 6th month and 12th month



Graph 6: Comparison of AST at day 0, 6th month and 12th month

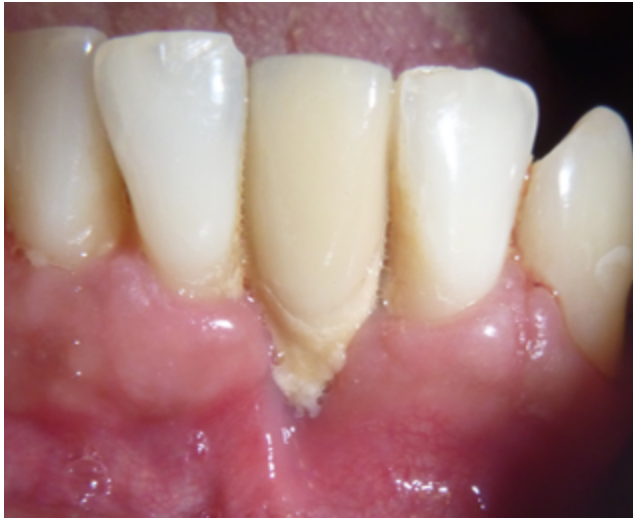

Fig. 1: Measurement of modified plaque index

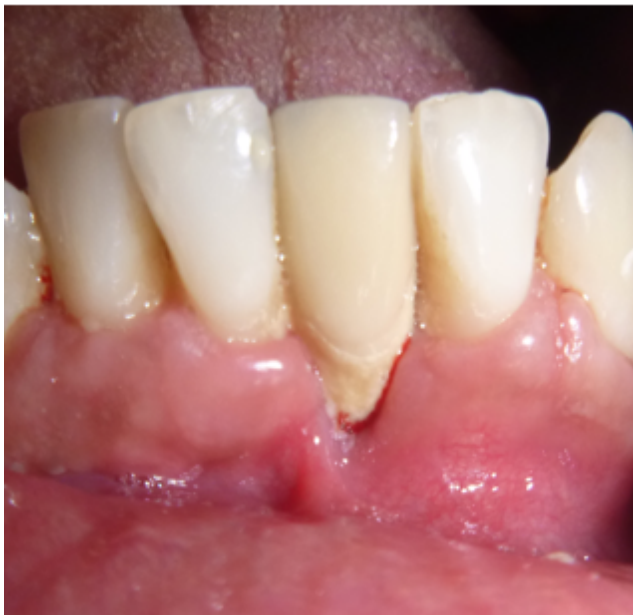

Fig. 2: Measurement of modified bleeding index (mBI)

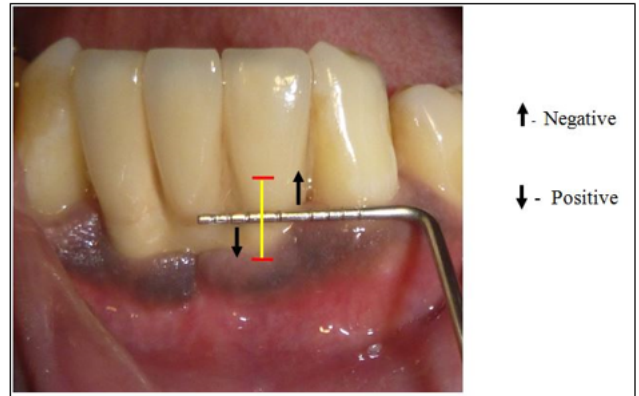


Fig. 3: Measurement of marginal soft tissue level (ML), arrow pointing up indicates negative scoring and arrow pointing down indicates positive scoring.

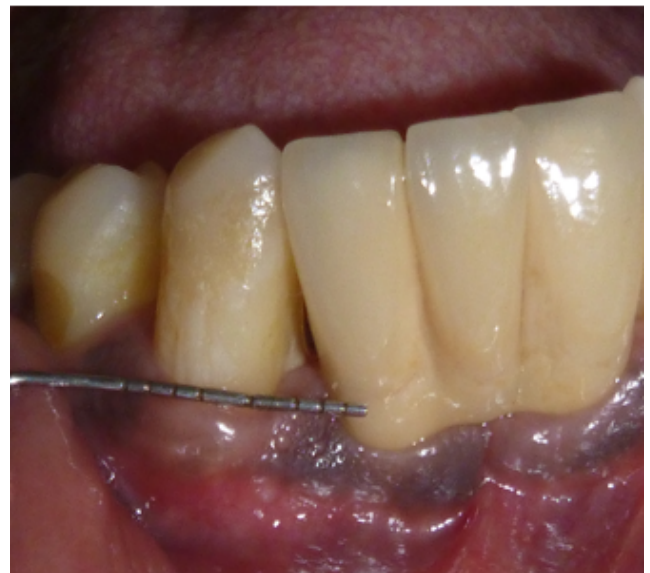

Fig. 4: Measurement of papilla index (PI)

mandibular anterior region. However, the observations and the results obtained varied for each parameters measured.

The comparison of mPI scores was not statistically significant, indicating a consistency in the maintenance of sites during the study period compared to baseline. During the follow up visits, bleeding tendency was found to be decreasing when compared to baseline, as measured by mBI. An intercomparison of mBI at different follow up periods showed no increase in inflammatory status of the peri-implant mucosa which was a clinically relevant result as the implants were placed in a site with chronic inflammation. A similar study by Buser et al. showed a statistically significant change in plaque index and mBI

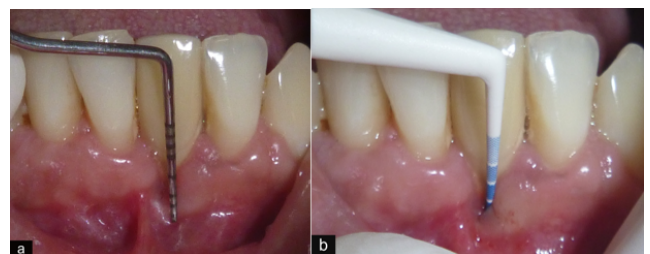


Fig. 5: Measurement of width of attached mucosa – Done by subtracting probing depth measured using Haw-click probe from the total width of keratinised mucosa; **a:** Measurement of total width of keratinised mucosa; **b:** Measurement of probing depth.

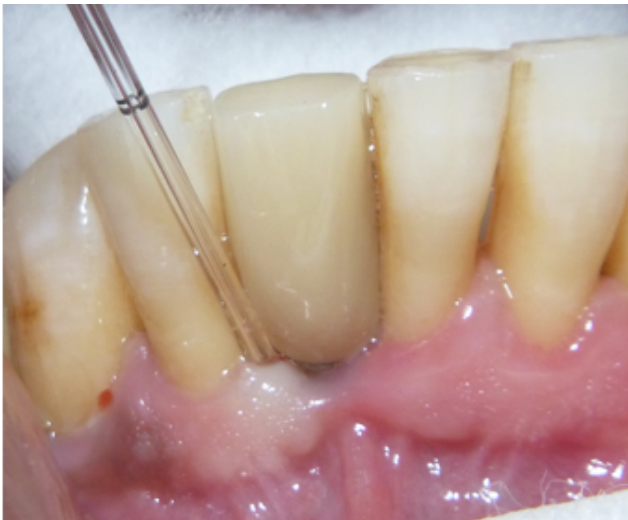

Fig. 6: Collection of PCF using microcapillary pipette.

scores.⁶ This difference in results compared to the present study could be due to the fewer sample sites and shorter follow up period of the present study and the retrospective and cross-sectional nature of the other study.

In the present study, the marginal soft tissue of peri-implant mucosa remained in the same position throughout the study period, indicating that a progression in marginal bone loss was not evident in cases of immediate implants placed in periodontally compromised sites. This was different from the results in a systematic review by Hartog et al. which had evaluated the soft tissue recession around immediate implants, wherein some of the studies reviewed had an increase in midfacial soft tissue recession.⁷

In the present study, the papilla fill was measured between implant prosthesis and the adjacent natural tooth. There was a progressive improvement in the papilla fill Index throughout the study period similar to the results demonstrated in a 2- year longitudinal study by Lee et al.⁸

The width of attached mucosa showed a clinically significant progression throughout the study period. Although there is still a controversy regarding the need of an adequate width of peri-implant attached mucosa, only 1 out of the 17 sites did not satisfy the minimally required width of 2 mm when measured at the end of 12 months.^{9–11} The study by Lee et al. also exhibited a similar improvement in the width of keratinized mucosa at the end of their 2 year study period.⁸

In the biochemical estimation of AST levels in PCF suggesting the inflammatory status, it was observed to have a stable value throughout the follow up visits. Since the threshold of AST in recognizing peri-implant mucositis or peri-implantitis is not completely established, the values obtained should be considered only suggestive of the condition not confirmatory. Similarly, according to the study by Rühling et al., the assessment of AST in PCF was found

to be of limited value as a diagnostic and prognostic marker for peri-implant disease.^{12,13}

5. Conclusion

The findings of the present study showed good soft tissue stability and a positive clinical improvement in the inflammatory status of peri-implant mucosa upto a follow up period of 1 year. The current study revealed no evident signs of peri-implant mucositis or peri-implantitis in any of the sites considered.

Thus, immediate implants could be used as a definitive treatment option in replacing periodontally compromised teeth in esthetic zone, with stringent placement and maintenance protocol. Considering the excellent tissue response, this treatment approach using immediate implants is recommended to prevent the residual ridge resorption at the extraction sites of periodontally compromised teeth.

However, further studies with longer follow up period, larger sample size, considering more standardization in sample selection with uniformity in the residual bone left, reason for extraction and periodontal status of teeth to be replaced, have to be undertaken with highly predictable and sensitive parameters for assessment is recommended to substantiate the present study conclusions.

6. Conflict of Interest

The authors declare that there is no conflict of interest.

7. Source of Funding

None.

References

- Hansson S, Halldin A. Alveolar ridge resorption after tooth extraction: A consequence of a fundamental principle of bone physiology. *J Dent Biomech.* 2012;3. doi:10.1177/1758736012456543.
- Nashar AA, Yakoob H. Evaluation of the use of plasma rich in growth factors with immediate implant placement in periodontally compromised extraction sites: a controlled prospective study. *Int J Oral Maxillofac Surg.* 2015;44(4):507–12. doi:10.1016/j.ijom.2014.12.001.
- Mombelli A, van Oosten M, Jr ES, Land NP. The microbiota associated with successful or failing osseointegrated titanium implants. *Oral Microbiol Immunol.* 1987;2(4):145–51. doi:10.1111/j.1399-302x.1987.tb00298.x.
- Oh TJ, Shotwell JL, Billy EJ, Wang HL. Effect of Flapless Implant Surgery on Soft Tissue Profile: A Randomized Controlled Clinical Trial. *J Periodontol.* 2006;77(5):874–82. doi:10.1902/jop.2006.050169.
- Jemt T. Regeneration of Gingival Papillae After Single-Implant Treatment. *Int J Periodont Rest Dent;*1997(17):327–33.
- Buser D, Bornstein MM, Weber HP, Grutter L, Schmid B, Belser UC, et al. Early Implant Placement with Simultaneous Guided Bone Regeneration Following Single-Tooth Extraction in the Esthetic Zone: A Cross-Sectional, Retrospective Study in 45 Subjects With a 2- to 4-Year Follow-Up. *J Periodontol.* 2008;79(9):1773–81. doi:10.1902/jop.2008.080071.
- Hartog DL, Slater JH, Vissink A, Meijer H, and GMR. Treatment outcome of immediate, early and conventional single-tooth implants

- in the aesthetic zone: a systematic review to survival, bone level, soft-tissue, aesthetics and patient satisfaction. *J Clin Periodontol.* 2008;35(12):1073–86. doi:10.1111/j.1600-051X.2008.01330.x.
8. Lee YM, Kim DY, Kim JY, Kim SH, Koo KT, Kim TI, et al. Peri-implant Soft Tissue Level Secondary to a Connective Tissue Graft in Conjunction with Immediate Implant Placement: A 2-Year Follow-up Report of 11 Consecutive Cases. *Int J Periodontics Restorative Dent.* 2012;32(2):213–22.
 9. Molina MP, Suarez F, Rios HF, Moreno PG, Wang HL. Guidelines for the Diagnosis and Treatment of Peri-implant Diseases. *Int J Periodontics Restorative Dent.* 2014;34(6):102–11. doi:10.11607/prd.1994.
 10. Bouri A, Bissada N, Al-Zahrani MS, Faddoul F, Nouneh I. Width of Keratinized Gingiva and the Health Status of the Supporting Tissues Around Dental Implants. *Int J Oral Maxillofac Implants.* 2008;23(2):323–6.
 11. Pranskunas M, Poskevicius L, Juodzbaly G, Kubilius R, Jimbo R. Influence of Peri-Implant Soft Tissue Condition and Plaque Accumulation on Peri-Implantitis: a Systematic Review. *J Oral Maxillofac Res.* 2016;7(3):e2. doi:10.5037/jomr.2016.7302.
 12. Rühling A, Jepsen S, Kocher T, Hans-Christian P. Longitudinal Evaluation of Aspartate Aminotransferase in the Crevicular Fluid of Implants with Bone Loss and Signs of Progressive Disease. *Int J Oral Maxillofac Implants.* 1999;14(3):428–35.
 13. Perez AS, Villaescusa M, Caffesse RG. Presence of Aspartate Aminotransferase in Peri-Implant Crevicular Fluid With and Without Mucositis. *J Oral Implantol.* 2012;38(2):115–23. doi:10.1563/AAID-

JOI-D-10-00055.

Author biography

Kuruvilla Elizabeth, Former Post Graduate Student

K R Biniraj, Professor

Emmatty Rishi, Professor

Paul P Tony, Professor

Jose Priya, Reader

K A Divyasree, Senior Lecturer

Cite this article: Elizabeth K, Biniraj KR, Rishi E, Tony PP, Priya J, Divyasree KA. Assessment of inflammatory status of peri-implant soft tissue around functionally loaded immediate implants placed in periodontally compromised tooth extraction sockets. *IP Int J Periodontol Implantol* 2022;7(1):9-14.