

Content available at: <https://www.ipinnovative.com/open-access-journals>

IP International Journal of Periodontology and Implantology

Journal homepage: <https://www.ijpi.in/>

## Case Report

# Interdisciplinary management of mucosal fenestration in two stages – A rare case report with one year follow-up

M S Prathap<sup>1</sup>, Shruthy Prathap<sup>2,\*</sup>

<sup>1</sup>Dept. of Conservative Dentistry and Endodontics, Yenepoya Dental College, Mangalore, Karnataka, India

<sup>2</sup>Dept. of Periodontics, Yenepoya Dental College, Mangalore, Karnataka, India



### ARTICLE INFO

#### Article history:

Received 13-11-2021

Accepted 18-12-2021

Available online 05-02-2022

#### Keywords:

Fenestration

Bone regeneration

Connective tissue graft

Interdisciplinary

Periapical surgery

### ABSTRACT

Gingival fenestrations are relatively rare phenomenon which results from exposure of tooth due to loss of the overlying bone and gingiva. If left untreated such lesions may act as a source of infection by providing a nidus for bacteria. This case report describes one such case of mucosal fenestration that was managed well using an interdisciplinary approach which included endodontic retreatment, periapical surgery with regenerative approach in the first stage. After 6 months second stage surgery was performed using connective tissue graft. At one year follow up, complete closure of the mucosal defect was found with substantial bone regeneration.

This is an Open Access (OA) journal, and articles are distributed under the terms of the [Creative Commons Attribution-NonCommercial-ShareAlike 4.0 License](https://creativecommons.org/licenses/by-nc-sa/4.0/), which allows others to remix, tweak, and build upon the work non-commercially, as long as appropriate credit is given and the new creations are licensed under the identical terms.

For reprints contact: [reprint@ipinnovative.com](mailto:reprint@ipinnovative.com)

## 1. Introduction

Various dental pathologies can lead to alveolar bone loss resulting in various types of osseous defects. An alveolar dehiscence and fenestration are commonly occurring osseous defects. An alveolar dehiscence denotes a lack of facial and lingual alveolar cortical plate resulting in denuded surface, while a fenestration is a circumscribed defect of the cortical plate which exposes the underlying root surface, but does not involve the alveolar margin of bone.

A mucosal fenestration is a clinical entity in which the gingiva is also denuded, thus exposing root to the oral cavity. Various factors are responsible for mucosal fenestration which includes decreased thickness of alveolar housing, labioversion of the tooth in the dental arch, contour of the root apex, occlusal factors, orthodontic tooth movement, periodontal and endodontic pathology, abscess formation, aberrant frenum.<sup>1</sup>

The most common area to be affected by dehiscence or fenestration is the anterior region of the arch especially the incisors. Mucosal fenestration have been discussed in the literature but has been found to be very rare.

Although they are usually symptom free, they might act as plaque-retaining area resulting in irritation and inflammation of the surrounding mucosa.<sup>2</sup> It may also be cause of concern for esthetics and root hypersensitivity with high chances of frequent infections.

However mucosal fenestrations affecting permanent teeth are clinically challenging because they require a more complex approach. Several case reports have proposed various treatment options which include root canal treatment, root resection, blind root surface instrumentation and mouth rinsing with chlorhexidine, full thickness mucogingival flap with primary or secondary healing, full thickness mucogingival flaps with guided tissue regeneration(GTR), bone grafting and pedicle flap operations.<sup>3,4</sup>

Biodentin is used as a root end filling material. Biodentin has been promoted as a favourable repair material due

\* Corresponding author.

E-mail address: [shruthyprathap@gmail.com](mailto:shruthyprathap@gmail.com) (S. Prathap).

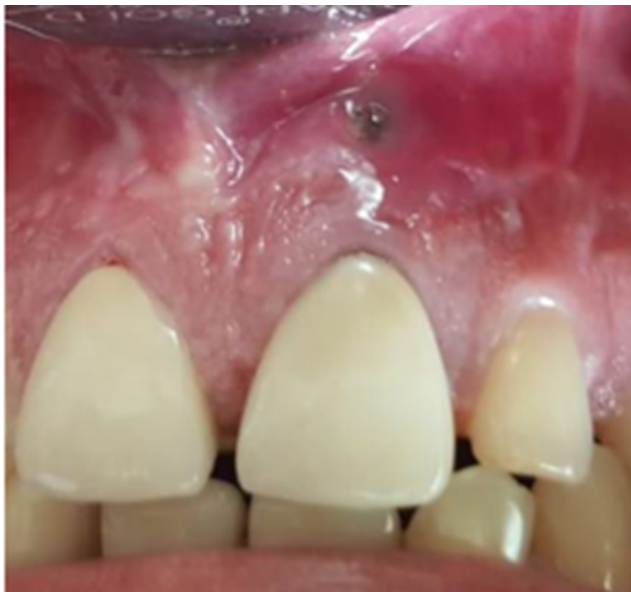to its bioactivity and biocompatibility. Biodentine has a setting time of less than 12 minutes and high mechanical properties with excellent sealing ability. Its property to release calcium ion and enhancing the alkaline environment makes biodentine more conducive for osteoblastic action.<sup>5,6</sup>

This case report presents a case of mucosal fenestration in an endodontically treated tooth with a history of attempted apicectomy. The hard and soft tissue defects were treated successfully by a combination of periapical surgery, root end resection, retrograde filling with biodentin and osseous grafting in first stage. In the second stage the defect was managed using connective tissue graft.

## 2. Case Report

A 42 year old male patient reported to the dental office with a chief complaint of exposed root surface and pus discharge in relation to upper left central incisor. He gave a history of trauma in the same tooth 15 years back and history of endodontic treatment and attempted apicectomy 5 years back. The patient was healthy with no significant medical history. The patient remained asymptomatic for three years after which he started noticing the mucosal defect in the gums related to the upper front teeth.

On intraoral examination tooth was found to be asymptomatic with mucosal discontinuity and pus discharge from the same area. A mucosal as well as alveolar bone fenestration was detected in relation to maxillary right central incisor. The root of the tooth was visible through the defect as it was 4mm long and 3 mm wide. The patient had relatively a poor oral hygiene with plaque and calculus deposits in relation to most of the teeth.

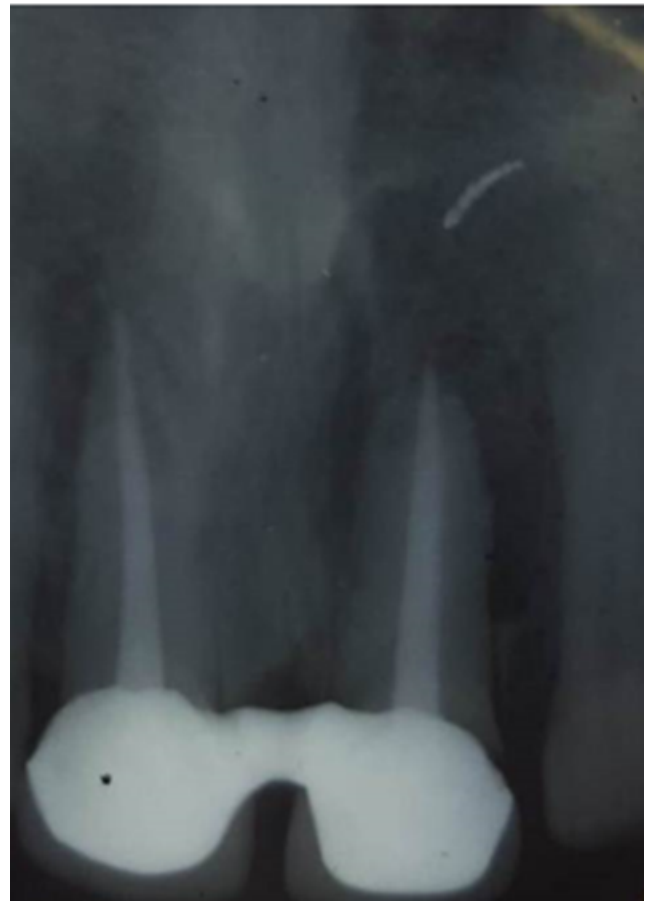

**Fig. 1:**

Fremitus test was found to be positive. Gingival palpation led to purulent discharge from the fenestrated and inflamed area.

Transgingival probing under local anaesthesia revealed that there was a loss of alveolar bone in the facial aspect.

Radiographic examination revealed a diffuse radiolucency circumscribing the teeth and the reduced root length and open apex. Periapical area showed extruded endodontic filling material. The CBCT image also revealed a loss of facial cortical bone.

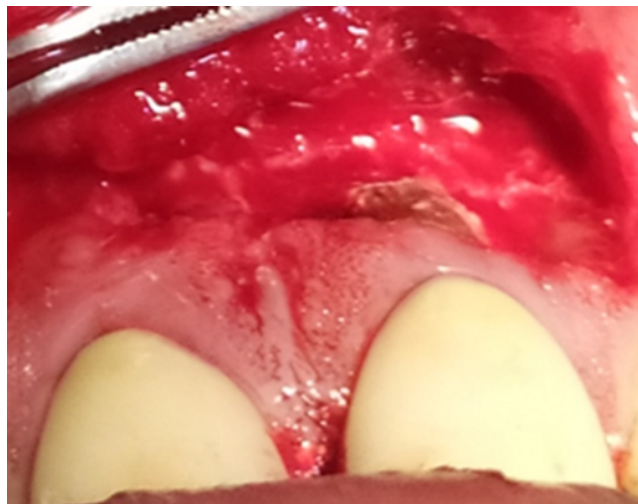


**Fig. 2:**

The treatment was planned such that the trauma from occlusion is relieved by trimming the palatal part of the restoration, endodontic treatment is repeated in the affected teeth and the periodontal and regenerative procedures carried out.

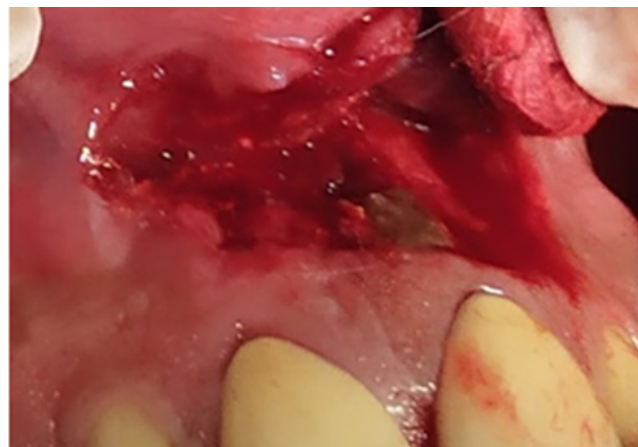
In the first visit a thorough scaling a rootplaning was done and the patient advised appropriate brushing technique. The old obturated material was removed and meticulous cleaning and shaping was performed. The canal was irrigated with 2.5% sodium hypochlorite. Calcium hydroxide paste was placed and the orifice sealed with temporary restorative material. Patient was prescribed antibiotics for 5 days as the the tooth was infected with

the presence of pus discharge. The patient was recalled after a week. A thin epithelial lining of the mucosal defect was removed first with No 11 blade after which a mucoperiosteal flap was raised.



**Fig. 3:**

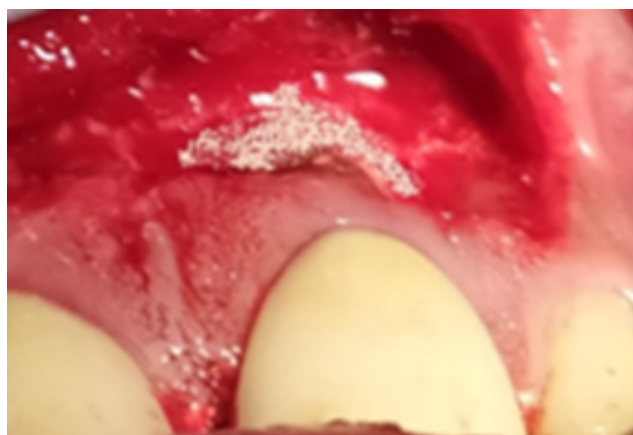
The defect was debrided along with the removal of granulation tissue. Around 2mm of the root apex was resected, the extruded endodontic material also was removed.



**Fig. 4:** Defect after degranulation, and apical resection

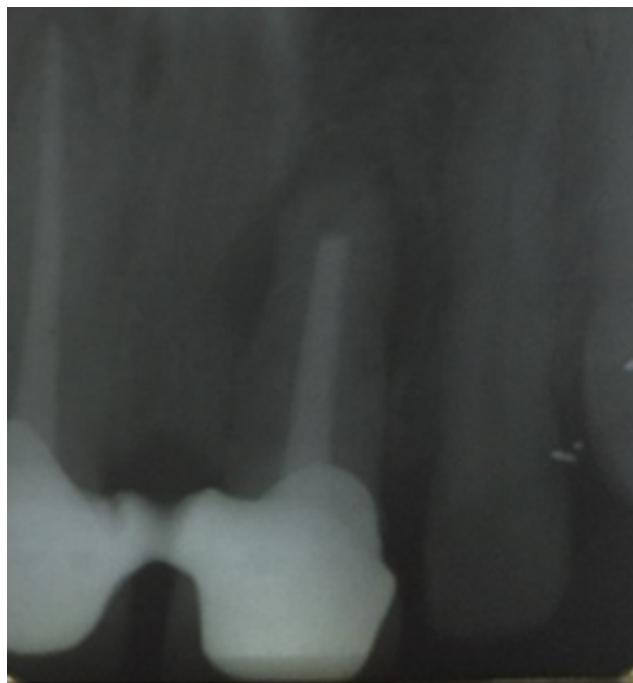Biodentin was placed at the resected area which was allowed to set. Synthetic bone graft material (hydroxyapatite) was packed in to the defect.

The elevated flap was displaced and sutured tightly using simple interrupted sutures. The deepithelised mucosal defect was also approximated and sutured. The patient was prescribed antibiotic, amoxicillin 500mg for 5 days and analgesics for postoperative pain. The patient was advised to use chlorhexidine mouthwash for one week. After a week patient was recalled for suture removal and review. Healing



**Fig. 5:** Placement of osseous graft

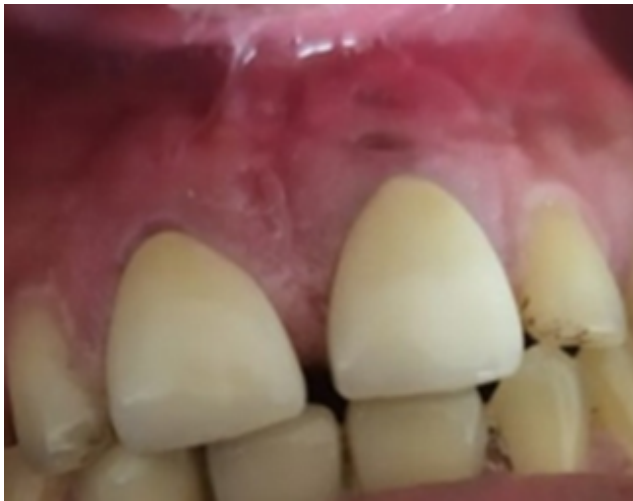was found to be uneventful and in the following visits the mucosal defect had completely healed. At 6 months postoperatively, the radiograph showed significant bonefill and clinically but the mucosal defect was not completely healed. Hence a second surgical procedure was planned using connective tissue graft harvested from the palate.



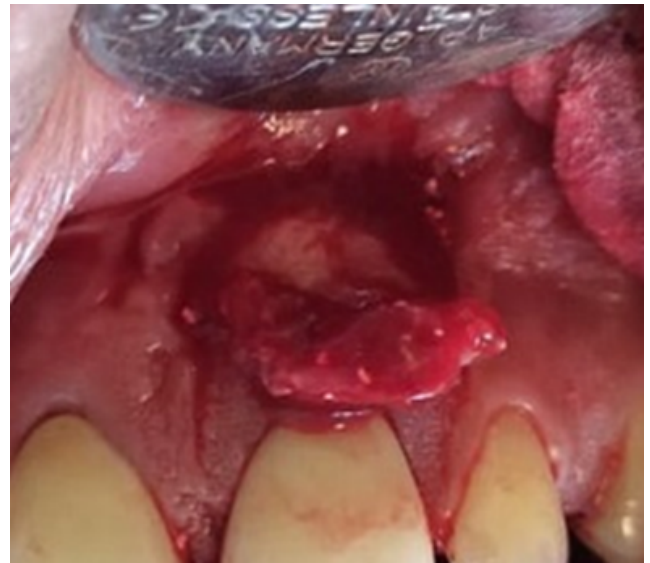**Fig. 6:** Six months Postoperative Radiograph

### 3. Discussion

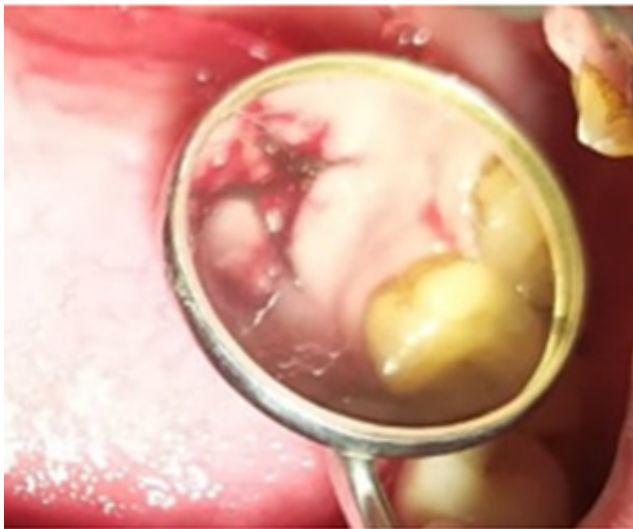
A mucosal fenestration is often clinically challenging. Although they are generally symptom free, they might act as plaque retaining areas resulting in irritation and inflammation of the surrounding mucosa.<sup>2,7</sup>



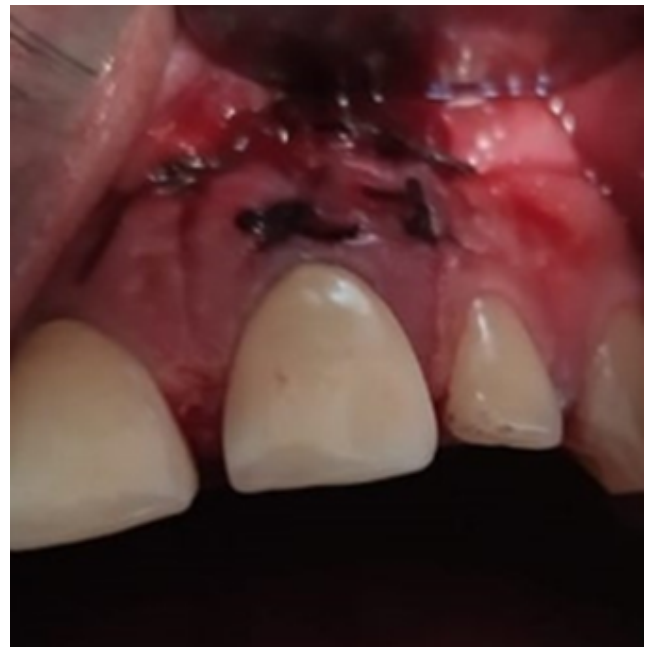**Fig. 7:** Six months postoperative photograph



**Fig. 9:** Placement of connective tissue graft at the recipient site



**Fig. 8:** Connective tissue graft harvested from palate



**Fig. 10:** Connective tissue graft sutured at the recipient site

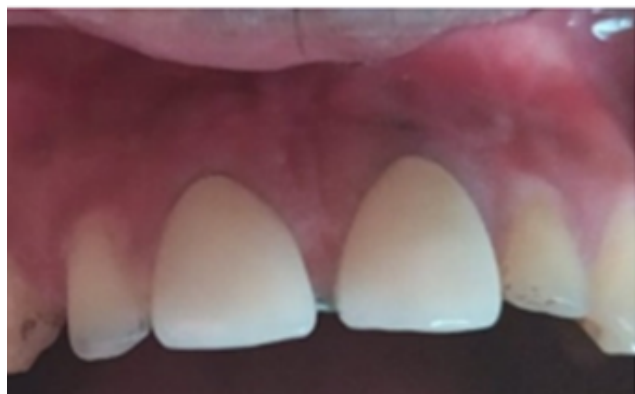Biodentine is a calcium silicate based restorative cement with dentin like mechanical properties. The powder mainly contains tricalcium and dicalcium silicate ( $3 \text{ CaO SiO}_2$ ), which is main component of Portland cement, as well as calcium carbonate ( $\text{CaCO}_3$ ) and zirconium oxide. The liquid consists of calcium chloride ( $\text{CaCl}_2 \cdot 2\text{H}_2\text{O}$ ) solution with an admixture of polycarboxylate.<sup>8,9</sup>

Biodentin has a shorter setting time of 12 minutes as compared to MTA which is 2 hours 45 minutes.<sup>10</sup>

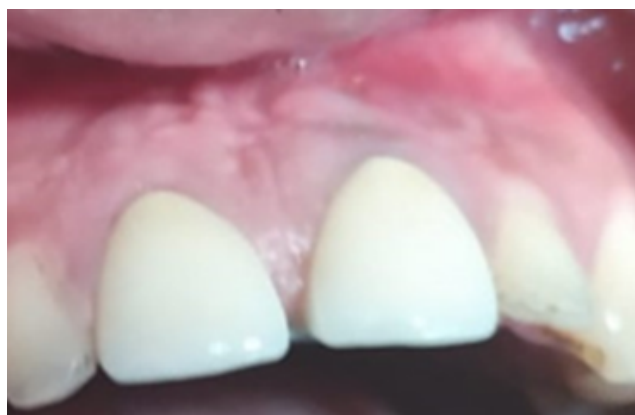Quicker setting time eliminates the need for two step obturation as with MTA, and reduces the risk of bacterial contamination. Despite varied etiology, mucosal fenestration secondary to chronic periapical inflammation has been reported more often in literature which in many cases is associated with an extreme buccal inclination of root or with very thin buccal cortical plate.

Various treatment modalities advocated in literature for the management of mucosal fenestration are lateral pedicle flap, guided tissue regeneration, and apicectomy combined with endodontic treatment.<sup>2</sup>

Rajula M et al (2020) successfully managed a case of mucosal fenestration using bioactive glass with platelet rich fibrin and free connective tissue graft.<sup>11</sup> Saravanan et al (2016) managed an uncommon presentation of concomitant gingival recession with an isolated mucosal fenestration with an allograft matrix.<sup>12</sup>



**Fig. 11:** Two weeks postoperative picture



**Fig. 12:** At 1 year followup

In the present case connective tissue grafting was done after 6 months after the endodontic retreatment, apicectomy and osseous grafting as there was a significant amount of bone destruction in the initial stage. One year postoperatively a substantial amount of bone fill was observed and there was complete closure of the mucosal penetration. The multidisciplinary treatment approach involving endodontic retreatment, apicectomy with apical seal using biodentin, osseous grafting with biooss connective tissue graft in the second stage (after 6 months) has led to the successful outcome.

#### 4. Conclusion

Mucosal fenestration is an opening or an interstice through the oral mucosa. They are relatively rare but when present pose a difficult situation for the clinician. It makes the case more challenging resulting in poor prognosis. The present case report describes a situation where there was a mucosal as well as alveolar bone fenestration. There have been various non surgical and surgical procedures that have been documented for treatment. The present case was successfully managed using an interdisciplinary approach which included endodontic retreatment, apicectomy, periodontal flap and regenerative

and mucogingival procedure procedures.

#### 5. Source of Funding

This work not supported in any foundation.

#### 6. Conflict of Interest

The authors declare no potential conflicts of interest concerning the authorship and publication of this article.

#### References

1. Jafri Z, Sultan N, Ahmadr D. An infrequent clinical case of mucosal fenestration: Treated with an interdisciplinary approach and regenerative therapy. *J Indian Soc Periodontol.* 2019;23(2):168–71. doi:10.4103/jisp.jisp\_325\_18.
2. Daweswl, Barnes IE. The surgical treatment of fenestrated buccal roots of an upper molar. A case report. *Int Endod J.* 1983;16(2):82–6. doi:10.1111/j.1365-2591.1983.tb01301.x.
3. Ju YR, Tsai AH, Wu YJ, Pan WL. Surgical intervention of mucosal fenestration in a maxillary premolar: a case report. *Quintessence Int.* 2004;35(2):125–8.
4. Lehman J, Meister F, Gerstein H. Use of a pedicle flap to correct an endodontic problem: A case report. *J Endod.* 1979;5(10):377–83. doi:10.1016/s0099-2399(79)80082-5.
5. Laux M, Abbott PV, Pajarola G, Nair PNR. Apical inflammatory root resorption : A correlative radiographic and histologic assessment. *Int Endod J.* 2000;33(6):483–93. doi:10.1046/j.1365-2591.2000.00338.x.
6. Laurant P, Camps J, Meo D, Dejou M, About J, I. Induction of special cell responses toCa (3) SiO5 based posterior restorative material. *Dent Mater.* 2008;24:1486–94.
7. Pinto LAS, Seale NS, Reddy AK, Cordeiro RCL. Fenestration gingival defect in erupting permanent mandibular incisors: a case report. *Quintessence Int.* 1998;29(4):239–42.
8. Nowicka A, Lipskim M, Parafunk. Response of human dental pulpcapped with biodentine and mineral trioxide aggregate. *J Endod.* 2013;39(6):743–7.
9. Zanini M, Sautier M, Berdal A, Simon S. Biodentine induces immortalized murine pulp cell differentiation into odontoblast like cells and stimulates biomineralization. *J Endod.* 2012;38(9):1220–6.
10. Parirokh M, Torabinejad M. Mineral trioxide aggregate: a comprehensive literature review–Part I: chemical, physical, and antibacterial properties. *J Endod.* 2010;36(1):16–27. doi:10.1016/j.joen.2009.09.006.
11. Rajula PBM, Varatharajan K, Mani R, Krishnakumar S. Gingival fenestration management : a rarefied case entity and literature review. *J Pharm Bioall Sci.* 2020;12(1):648–51. doi:10.4103/jpbs.JPBS\_77\_20.
12. Balasubramanian S, Singh V, Bhat SG, Acharya SR, Ballal V, Saraswathi V, et al. Isolated mucosal fenestration with localized gingival recession: Closure with an acellular dermal graft. A rare case report with two years' follow-up. *Quintessence Int.* 2016;47(5). doi:10.3290/j.qi.a35522.

#### Author biography

**M S Prathap**, Professor

**Shruthy Prathap**, Additional Professor

**Cite this article:** Prathap MS, Prathap S. Interdisciplinary management of mucosal fenestration in two stages – A rare case report with one year follow-up. *IP Int J Periodontol Implantol* 2021;6(4):234–238.