



## Case Report

# A case report: Pregnancy tumor in lower mandibular anterior region and its management

Pallavi Sharma<sup>1</sup>, Samiksha Sharma<sup>1,\*</sup>, Shiva Chouhan<sup>1</sup>, Vikas Jindal<sup>1</sup>, Amit Goel<sup>1</sup>, Komal Fanda<sup>2</sup>

<sup>1</sup>Dept. of Periodontics, Himachal Dental College, Sundernagar, Himachal Pradesh, India

<sup>2</sup>Himachal Institute of Dental Sciences, Paonta Sahib, Himachal Pradesh, India



### ARTICLE INFO

#### Article history:

Received 27-11-2021

Accepted 22-12-2021

Available online 05-02-2022

#### Keywords:

Pregnancy Tumor

Pyogenic Tumor

Treatment

### ABSTRACT

Pyogenic granuloma (PG) or granuloma pyogenicum is a tumor like lesion in the oral cavity primarily seen around gingiva. PG is considered to be a non-neoplastic in nature. It is manifested as a painless sessile or pedunculated, erythematous, exophytic with specific papular or nodular with a smooth or lobulated surface, which may have a fibrinous covering. The lesion usually bleeds easily on a slight provocation. It is a reactive lesion, also classified in pregnancy associated gingival diseases. It occurs due to irritation or physical trauma from calculus or cervical restorations as also some contribution by hormonal factors and usually affects the gingiva. The growth is typically seen on or after the third month of pregnancy and may grow rapidly to acquire a large size, thus, requiring surgical removal.

This is an Open Access (OA) journal, and articles are distributed under the terms of the [Creative Commons Attribution-NonCommercial-ShareAlike 4.0 License](https://creativecommons.org/licenses/by-nc-sa/4.0/), which allows others to remix, tweak, and build upon the work non-commercially, as long as appropriate credit is given and the new creations are licensed under the identical terms.

For reprints contact: [reprint@ipinnovative.com](mailto:reprint@ipinnovative.com)

## 1. Introduction

Pregnancy tumor, Pyogenic granuloma is a renowned oral lesion that mainly occurs on gingiva during pregnancy. In 1844, Hullihen designated the first case of pyogenic granuloma.<sup>1</sup> In 1904, Hartzell attributed the current term of “pyogenic granuloma” or “granuloma pyogenicum.”<sup>2</sup> Angelopoulos et al histologically described it as “hemangiomas granuloma” because it consists of numerous blood vessels and the inflammatory nature of the lesion.<sup>3</sup> Cawson et al. in dermatologic literature have described it as a “granuloma telangiectacticum” due to the presence of numerous blood vessels seen in histological sections. They described two forms of pyogenic granulomas, the lobular capillary hemangioma and the non-lobular capillary hemangioma.<sup>4</sup>

The term of PG is misleading, because the lesion is unrelated to infection and it is not a true granuloma. It arises as a result of various stimuli, such as low grade local irritation, trauma, or hormonal factors.<sup>5</sup> These lesions have been described as a painless, exophytic mass that has either a sessile or pedunculated base extending from the gingival margin or, in most instances, from the interproximal tissues in the maxillary anterior. The pregnancy tumor most commonly develops on the buccal gingiva in the interproximal tissue between teeth.<sup>6</sup> This benign hyperplastic lesion of the oral mucosa occurs in up to 5% of pregnancies. It hardly ever reaches more than 2 cm in size and has an affinity to recur, if not completely removed. The gingiva is involved in 70% of cases, followed by the tongue, lips, and buccal mucosa. Pregnancy tumor generally occurs at the end of the first trimester and swift growth usually accompanies the steady increase of circulating estrogens and progesterones. Partial or complete regression is common after child birth. Repeated mild

\* Corresponding author.

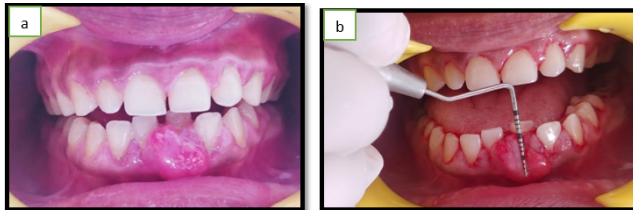
E-mail address: [samikshasharma1693@gmail.com](mailto:samikshasharma1693@gmail.com) (S. Sharma).

irritation with gestational steroid changes may subsequently exacerbate inflammatory response, leading to development of this proliferating lesion.<sup>7</sup>

In this article, we have presented a case report of a large pyogenic granuloma of the gingiva in a 28 year old female patient who presented a localized tumor like enlargement in the lower anterior region of mandibular jaw.

## 2. Case Report

A 22 year old female reported to the Department of Periodontics, Himachal dental college, Sundernagar with chief complaint of gingival overgrowth and bleeding on slight provocation in the lower central incisor of mandibular region of jaw. The patient reported that he noticed the swelling during pregnancy, which was painless and gradually increased in size during pregnancy.[Figure 1a] [Figure 1b]

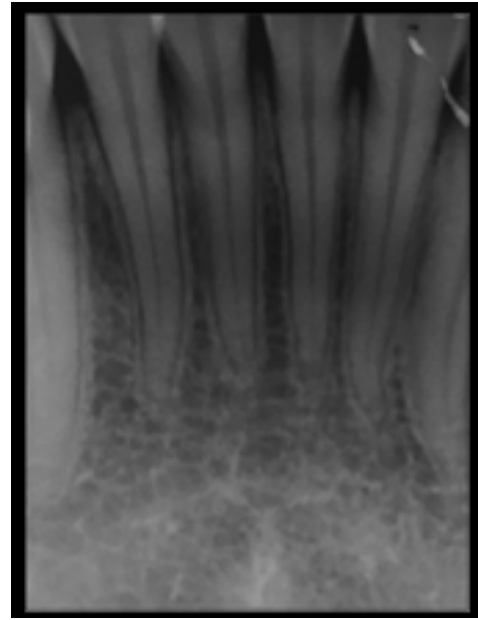


**Fig. 1:** a: Preoperative Frontal view; b: Measurement of lesion with probe

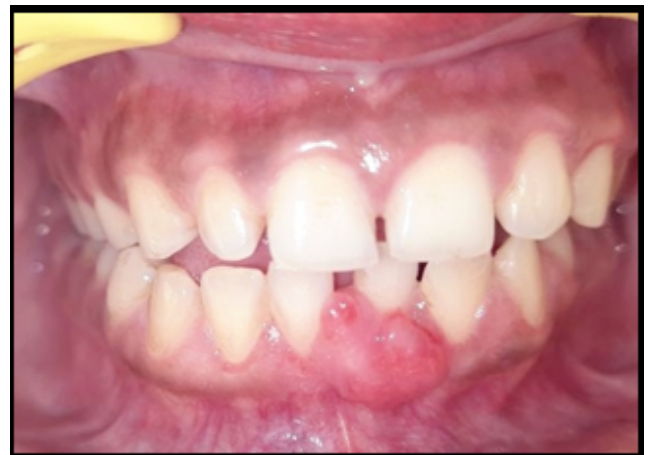Teeth associated with it did not show any mobility. Radiographically, there were no visible abnormalities and the alveolar bone in the region of the growth appeared normal [Figure 2]. Routine blood investigations was found to be normal. A provisional diagnosis of pyogenic granuloma was made. The differential diagnosis included peripheral ossifying fibroma, peripheral giant cell granuloma, hemangioma and fibroma.

Conventional periodontal treatment, including scaling and root planing was performed to decrease gingival inflammation. Patient was given oral hygiene instructions and correct brushing technique was demonstrated as also a 0.12% chlorhexidine mouthwash was prescribed. Three weeks later, it was noticed that the lesion did not regress completely as shown in [Figure 3]. The lesion was excised with the help of surgical blade, followed by curettage and through scaling of the involved teeth and then transported in 10% formaldehyde for histopathological examination[Figure 4a] [Figure 4b]. After that gingivoplasty was done to recontour the soft tissue and periodontal pack was given. After that patient was recalled after 1 week for removal of the pack and checkup.

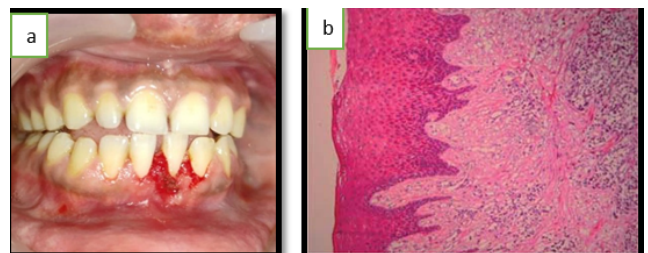
Histopathological report shows parakeratinized epithelium, stretched in some places and showed proliferation towards the base of the lesion. The underlying connective tissue stroma showed dilated and engorged



**Fig. 2:** Periapical X-ray of the lesion area.



**Fig. 3:** After scaling and root planing



**Fig. 4:** a: Lesion removed after excision; b: Histological section

blood vessels, extravasated red blood cells, angiogenesis, few inflammatory cells and bundles of collagen fibers. The diagnosis of pyogenic granuloma hence was histologically confirmed. The patient was recalled every 3rd month for maintenance and to check for possible recurrence [Figure 5].

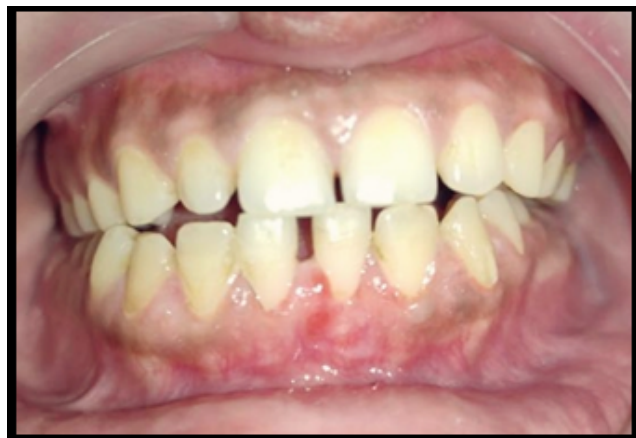

Fig. 5: Post-operative view

### 3. Discussion

Pyogenic granuloma is a type of inflammatory hyperplasia that affects the tissues of the mouth. This lesion is now widely accepted to be the outcome of an excessive localised connective tissue reaction to a minor injury or other underlying irritation.<sup>8</sup> Calculus, poor dental hygiene, nonspecific infection, overhanging restorations, cheek biting, and other factors might be unpleasant. The underlying fibro-vascular connective tissue becomes hyperplastic as a result of the irritation, and granulation tissue proliferates, resulting in the creation of a pyogenic granuloma.<sup>9</sup> A complete surgical excision is required to treat pyogenic granuloma. Differentiating pyogenic granuloma from other benign soft tissue lesions is important. Peripheral giant cell granuloma, pregnancy tumour, and typical granulation tissue are a few examples.<sup>10</sup> Excision and biopsy of the lesion is indicated unless it will result in a significant deformity, in which case incisional biopsy is recommended. For minor painless non-bleeding lesions, conservative surgical excision of the lesion with removal of irritants such as plaque, calculus, and foreign materials is indicated. Excision of gingival lesions to the periosteum, as well as thorough scrubbing and root planing of adjacent teeth, is indicated to eliminate all obvious sources of irritation.<sup>11</sup>

The lesion was surgically removed and sent for histopathologic testing in this case. The surrounding teeth were scaled and root planned to remove all of the local irritants, which could have been the primary etiological component in this case.<sup>12</sup> Various different therapeutic

approaches have been employed by doctors, including the use of the Nd: YAG laser, carbon dioxide laser, flash lamp pulse dye laser, cryosurgery, electrodesiccation, sodium tetradecyl sulphate sclerotherapy, and intralesional steroids.<sup>13</sup> Because recurrence of oral pyogenic granulomas is common in pregnant women, therapy should be done after parturition. Treatment can, however, be completed in the second trimester if necessary, with post-parturition follow-up.<sup>14</sup> Pyogenic granuloma can be effectively treated if the diagnosis and treatment approach are correct. Preventing the recurrence of this benign lesion is also possible with appropriate management of the lesion.

### 4. Conclusion

Pyogenic granuloma is a frequent skin and oral cavity lesion, particularly of the gingiva. A case of a massive gingival pyogenic granuloma in a female patient is presented in this case report which illustrates how one such case's diagnosis, treatment, and follow-up were completed. It can be deduced from the presentation of this study that a combination of several etiological events may have led the inflammatory tissue to pass the threshold from ordinary gingivitis to granuloma development. Because nerves do not develop within the reactive hyperplastic tissue, the lesion was painless. Surgical excision is an effective therapy option for preventing lesion recurrence. As a result, accurate diagnosis and treatment planning should be taken into account. The lesion should be carefully managed while the mucogingival complex is preserved and improved.

### 5. Source of Funding

This work not supported in any foundation.

### 6. Conflict of Interest

The authors declare no potential conflicts of interest concerning the authorship and publication of this article.

### References

- Hullihen SP. Case of aneurism by anastomosis of the superior maxillae. *Am J Dent Sci.* 1844;4(3):160–2.
- Hartzell MB, Granuloma. *Granuloma Pyogenicum. J Cutan Dis Syph.* 1904;22(3):520–5.
- Angelopoulos AP. Pyogenic granuloma of the oral cavity: Statistical analysis of its clinical features. *J Oral Surg.* 1971;29(12):840–7.
- Cawson RA, Binnie WH, Speight PM, Barrett AW, Wright JM. *Lucas's Pathology of Tumors of the Oral Tissues.* 5th Edn. Churchill Livingstone; 1988. p. 252–6.
- Esmail N, Sharmila M, Sangeeta K, Rahul. A case report of pregnancy tumor and its management using the diode laser. *J Dent Lasers.* 2012;6(2):68–71. doi:10.4103/0976-2868.106666.
- Gomes SR, Shakir Q, Thaker PV, Tavadia JK. Pyogenic granuloma of the gingiva: A misnomer? - A case report and review of literature. *J Indian Soc Periodontol.* 2013;17(4):514–9.
- Kamal R, Dahiya P, Puri A. Oral pyogenic granuloma: Various concepts of etiopathogenesis. *J Oral Maxillofac Pathol.* 2012;16(1):79–82. doi:10.4103/0973-029X.92978.

8. Mathur LK, Bhalodi AP, Manohar B, Bhatia A, Rai N, Mathur A, et al. Focal fibrous hyperplasia: a case report. *Int J Dent Clin.* 2010;2(4):56–7.
9. Kerr DA. Granuloma pyogenicum. *Oral Surg Oral Med Oral Pathol.* 1951;4(2):158.
10. Jafarzadeh H, Sanatkhani M, Mohtasham N. Oral pyogenic granuloma: a review. *J Oral Sci.* 2006;48(4):167–75.
11. Neville BW, Damm DD, Allen CM, Bouquot JE. Oral and Maxillofacial Surgery. 2nd Edn. Philadelphia: Saunders; 2002. p. 447–9.
12. Regezi JA, Sciubba JJ, Jordan RC. Oral Pathology: Clinical Pathological Considerations. 4th Edn. Philadelphia: WB Saunders; 2003. p. 115–6.
13. Parisi E, Glick PH, Glick M. Recurrent intraoral pyogenic granuloma with satellitosis treated with corticosteroids. *Oral Dis.* 2006;12(1):70–2. doi:10.1111/j.1601-0825.2005.01158.x.
14. Steelman R, Holmes D. Pregnancy tumor in a 16-year-old: Case report and treatment considerations. *J Clin Pediatr Dent.* 1992;16(3):217–8.

## Author biography

**Pallavi Sharma**, MDS

**Samiksha Sharma**, 3rd Year Post Graduate Student

**Shiva Chouhan**, Reader

**Vikas Jindal**, Professor and HOD

**Amit Goel**, Professor

**Komal Fanda**, Senior Lecturer

**Cite this article:** Sharma P, Sharma S, Chouhan S, Jindal V, Goel A, Fanda K. A case report: Pregnancy tumor in lower mandibular anterior region and its management. *IP Int J Periodontol Implantol* 2021;6(4):230-233.