



Case Report

Frenectomy by millers technique: A case report

Nishita Bhosale^{1,*}, Yogesh Khadtare¹, Pramod Waghmare¹, Amit Chaudhari¹, Priya Lele¹, Neelam Gavali¹

¹Dept. of Periodontology, Bharati Vidyapeeth Deemed to be University Dental College and Hospital, Pune, Maharashtra, India



ARTICLE INFO

Article history:

Received 20-10-2020

Accepted 30-11-2020

Available online 24-12-2020

Keywords:

Aberrant frenum

Frenectomy

Millers technique

Laterally displaced flap

ABSTRACT

The Aberrant labial frenum results in diastema and gingival recession thereby compromising the esthetic and functional needs of the patient. There are various procedure for the treatment of the aberrant frenum. The classical frenectomy technique by Archer is an extensive procedure which results in Unesthetic scarring of the tissue, loss of interdental papilla. To overcome these drawbacks, Miller introduced a newer technique where he combined the frenectomy technique with laterally displaced flap. The main advantage of this technique is that the healing takes place by primary intention with no scarring of the tissue. This article is a case report on frenectomy with laterally displaced flap (Millers technique).

© This is an open access article distributed under the terms of the Creative Commons Attribution License (<https://creativecommons.org/licenses/by/4.0/>) which permits unrestricted use, distribution, and reproduction in any medium, provided the original author and source are credited.

1. Introduction

The frenum is anatomic structure derived from the latin word “fraenum”, which is formed by a membranous fold of mucous membrane, connective tissue and sometimes muscle fibres. There are numerous frena which are present in the oral cavity and the most commonly noted frena are the maxillary labial frenum, the mandibular labial frenum, and the lingual frenum.¹

The stability to the upper and lower lips and to the tongue is provided by the frena which is its primary function.²

The aberrant frenum can lead to gingival recession when they are too closely attached to the gingival margin. This can be either because of opening of the gingival crevice due to muscle pull or a interference with the improper placement of a toothbrush.¹

The development of maxillary labial frenum is from the post-eruptive remnant of the ectolabial bands which connects the tubercle of the upper lip to the palatine papilla. There is no bone deposited inferior to the frenum when the two central incisors erupt widely separated. A V-shaped bony cleft is formed between the two central incisors,

resulting in an abnormal frenum attachment. When there is a decreased vestibular depth and an inadequate width of the attached gingiva, mandibular frenum is considered as aberrant.^{1,3} Frenum has been classified by Placek et al (1974) depending upon the extension of the attachment fibers as:⁴

1. Mucosal – here the frenal fibers are attached to the mucogingival junction
2. Gingival – here the fibers are inserted within the attached gingiva
3. Papillary – here the fibers are extending into the interdental papilla
4. Papilla penetrating – here the frenal fibers cross the alveolar process and extend up to the palatine papilla.

Papillary and papilla penetrating frena are considered as pathological and have been associated with recession, loss of papilla, diastema, malalignment of teeth, difficulty in brushing and it may also prejudice the denture fit or retention leading to psychological disturbances to the individual.^{5,6} Miller has recommended that the frenum should be characterized as pathogenic when the frenum is unusually wide or there is no zone of attached gingiva along

* Corresponding author.

E-mail address: drnishita.02nb@gmail.com (N. Bhosale).

the midline or when the frenum is extended the interdental papilla shifts.⁷

The abnormal frena can be diagnosed visually by moving the upper lip outwards and downwards and lower lip is moved outwards and upwards. If the gingival margin shows movement or if blanching is seen due to ischemia, then the test is positive and the frenum is said to be aberrant. This test is known as the Blanching test or Tension test. (Figure 1)

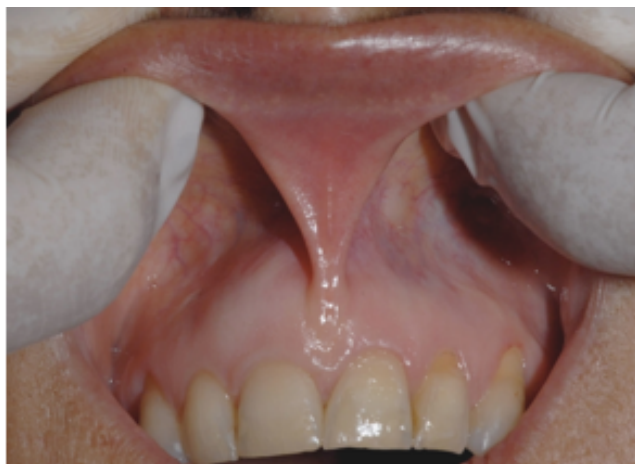

Fig. 1: Blanching/Tension test

According to Olivi et al, clinical indications for frenum removal include:⁸

1. Abnormal frenum with inflamed gingiva due to poor oral hygiene
2. Abnormal frenum associated with inflamed gingival recession
3. Maxillary frenum associated with Diastema after complete eruption of permanent canines
4. Abnormal maxillary frenum (Class III or IV), resulting in the presence of a diastema during mixed dentition.
5. Abnormal mandibular frenum with high insertion leads to the onset of gingival recession

The treatment of the aberrant frena can be either done by frenectomy or by frenotomy procedures. Frenectomy is defined as the complete removal of the frenum, with its attachment to the underlying bone, while Frenotomy is the relocation of the frenal attachment.⁹

There are various surgical techniques of frenectomy which include Classical frenectomy by Archer and Kruger, Millers technique (unilateral single pedicle flap), Schuchardt Z-plasty, V-Y Plasty, Frenectomy using electrocautery, Laser – Diode, CO₂, Nd:YAG, Er:YAG and other soft tissue lasers.

The main drawback of the classical frenectomy technique is scarring which may lead to periodontal problems and unesthetic appearance.

Miller has given a surgical technique where the frenectomy is combined with a laterally positioned pedicle graft. The primary advantage of this technique is complete closure seen across the midline due to laterally positioned gingiva and the healing by primary intention which resulted in aesthetically acceptable attached gingiva across the midline. Interdental papilla remained undisturbed as no attempt was made to dissect the trans-septal fibers. Therefore esthetically and functionally better results were obtained.⁷

This article presents a case report on frenectomy by Millers technique.

2. Case

A 23 years old male patient reported to the Department of Periodontology. On clinical examination, according to Miller, the frenum was considered abnormal as it was unusually wide and there was inadequate zone of attached gingiva along the midline⁷ and also the tension test was positive and therefore frenectomy by Millers technique was decided. The entire surgical procedure was explained to the patient and written informed consent was obtained from the patient before the surgical procedure.

2.1. Surgical technique

Armamentarium - no.15 surgical blade, Haemostat, Gauze, 5-0 black silk sutures, Needle holder, suture cutting scissors and a periodontal dressing.

Procedure:⁹(Figure 2)

2% lignocaine with 1:80000 adrenaline was used as a local infiltration to anaesthetize the area. To separate the frenulum from the interdental papilla a horizontal incision was made. This incision was extended apically up to the vestibular depth to completely separate the frenum from the alveolar mucosa. (Any remnant of frenum tissue in the mid line and on the under surface of lip was excised). 2-3 mm apical to marginal gingiva up to vestibular depth, a vertical parallel incision was made on the mesial side of lateral incisor. The gingiva and alveolar mucosa in between these two incisions were undermined by partial dissection to raise the flap. 1-2 mm apical to gingival sulcus in the attached gingiva a horizontal incision was made, connecting the coronal ends of the two vertical incisions. Flap was raised, mobilised mesially and sutured to obtain primary closure across the midline. Postoperative instructions were given to the patient. Patient was recalled 1 week postoperatively for the removal of the sutures.

2.2. Post-operative care and follow up

Patient was asked not to consume any hot and spicy food. Patient was prescribed analgesic for 3 days and was recalled after 7 days for suture removal.

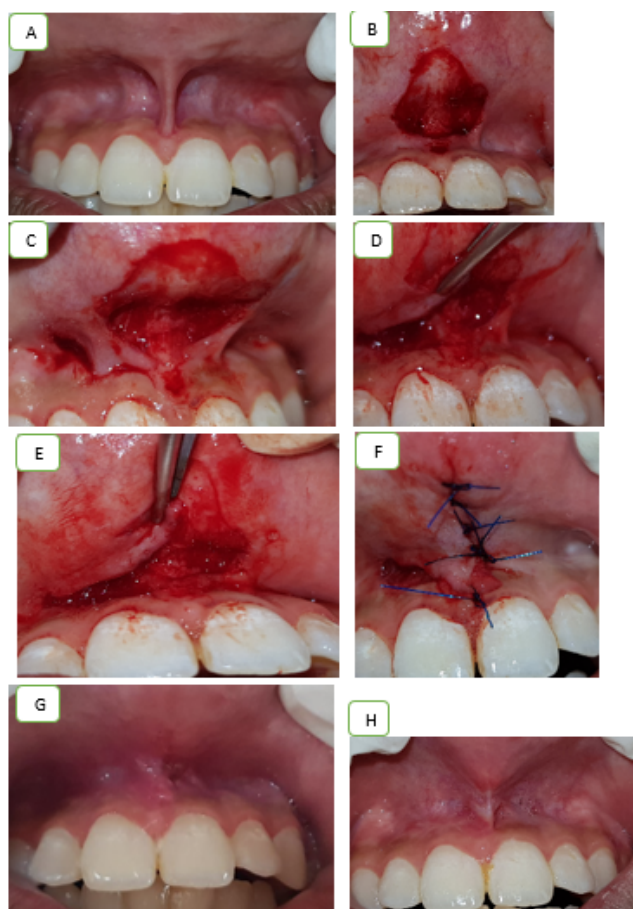


Fig. 2:

3. Discussion

To create more functional and aesthetic results more conservative and precise techniques are being adopted in this era of periodontal plastic surgery,¹⁰ Management of abnormal frenal attachment started from Archers classical frenectomy to modern concepts by Edwards. To evade the formation of scar and to facilitate healing, application of laser and soft tissue grafts helped in evolving the newer frenectomy procedures.¹¹ The features that help in assessment of a frenum are vestibular depth, attached gingival zone, interdental papilla and midline diastema. An adequate zone of attached gingiva gives an aesthetically pleasing appearance and also help in the avoidance of recession which necessitates removal of the same.¹¹

Frenum is said to be pathogenic when it is unusually wide or there is no apparent zone of attached gingiva along the midline or the interdental papilla shifts when the frenum is extended.⁷

In a study conducted by Miller on 27 subjects with abnormal frenum who had undergone orthodontic closer of diastema, frenectomy combined with a laterally positioned pedicle graft was performed. The study showed that there was no loss of interdental papilla. In 24 cases there was

no relapse of diastema was seen and in only three cases minimal relapse (less than 1 mm) was noted. He suggested that the reopening of diastema was prevented by the newly formed broad attached gingiva which contains collagenous fibres which may have a bracing effect. According to Miller the ideal time for performing this surgery must be after orthodontic movement is completed and about six weeks before appliances are removed.⁷

The Millers technique offers two distinct advantages. Firstly, on healing, there is no anesthetic scar formation as a continuous band of gingiva is formed across the midline and secondly there is no trauma to the interdental papilla as the trans-septal fibres are not disrupted surgically.

In a study done by Nirwal Anubh et al,¹² performed frenectomy using laterally displaced pedicle graft. They achieved esthetically pleasing result as there was no loss of interdental papilla and no scar formation in the midline. Similar results were obtained in the present case report with good colour match.

A similar study was conducted by Ameet Mani et al¹³ and Devishree et al¹⁴ where they performed lateral pedicle frenectomy. They too observed that healing was by primary intention without any scarring in the midline.

In our case report, postoperatively we were able to achieve esthetically pleasing result without scar formation. Assessment of Pain was done using the Visual analogue scale during and after 24 and 72 hrs. Mild to moderate pain was there during and soon after the procedure. Post operative review after 2 days reveals absence of pain in the surgical site.¹⁵

4. Conclusion

The present case report describes the Millers surgical technique i.e., frenectomy with a lateral pedicle graft. The main advantage of this technique is that the healing takes place by primary intention, a thick zone of attached gingiva is formed, the colour matches with the adjacent tissue, no scarring takes place and there is no loss of interdental papilla as the transseptal fibers are not severed. We were able to achieve the above in our Case. More Comparative studies need to be done.

5. Source of Funding

None.

6. Conflicts of interest

The authors declare no conflicts of interest in the present study

References

1. Priyanka M, Emmadi P, Ambalavanan N, Sruthi R, Ramakrishnan T. An overview of frenal attachments. *J Indian Soc Periodontol* . 2013;17(1):12–5. doi:10.4103/0972-124x.107467.

2. Mintz SM, Siegel MA, Seider PJ. An overview of oral frenum and their association with multiple syndromic and nonsyndromic conditions. *Oral Surg Oral Med Oral Pathol Oral Radiol Endod* . 2005;99:321–4. doi:10.1016/j.tripleo.2004.08.008.
3. Huang WJ, Creath CJ. The midline diastema: a review on its etiology and treatment. *Pediatric Dent*. 1995;17:171–9.
4. Dibart S, Karima M. Labial frenectomy alone or in combination with a free gingival autograft. In: Serge Dibart, Mamdouth Karima (eds) *Practical Periodontal Plastic Surgery*. Germany: Blackwell Munksgaard; p. 53.
5. Dewel BF. The labial frenum, midline diastema and palatine papilla: A clinical analysis. *Dent Clin North Am*. 1966;p. 175–84.
6. Diaz-Pizan ME, Lagravere MO, Villena R. Midline diastema and frenum morphology in the primary dentition. *J Dent Child (Chic)*. 2006;26:11–4.
7. Miller PD. The frenectomy combined with a laterally Positioned pedicle graft; functional and aesthetic consideration. *J Periodontol*. 1985;56:102–6.
8. Olvi G, Chaumanet G, Genovese MD, Beneduce C, Er AST. Cr:YSGG Laser labial frenectomy : a clinical retrospective evaluation of 156 consecutive cases. *Gen Dent*. 2010;58:126–33.
9. Miller PD. Reconstructive periodontal plastic surgery mucogingival surgery). *J Tenn Dent Assoc*. 1991;71:14–8.
10. Chaubey KK, Arora VK, Thakur R, Narula IS. Perio-esthetic surgery: Using LPF with frenectomy for prevention of scar . *J Indian Soc Periodontol*. 2011;15(3):265.
11. Archer W. Oral surgery- a step by step atlas of operative techniques. In: 3rd Edn. Philadelphia, W B Saunders Co; 1961. p. 192.
12. Anubha N, Chaubey KK, Arora V, Thakur R, Zeba Z, Narula I, et al. Frenectomy combined with a laterally displaced pedicle graft. *Indian J Dent Sci*. 2010;2(2):47–51.
13. Mani A, Marawar P, Furtad L. Frenectomy with laterally displaced flap: a Case Report. *Int Dent J Students Res*. 2012;1(3):63–6.
14. Devishree D. Frenectomy: A Review with the Reports of Surgical Techniques. *J Clin Diagn Res* . 2012;6(9):1587–92. doi:10.7860/jcdr/2012/4089.2572.
15. Fearmonti R, Bond J, Erdmann D, Erdmann MD. A Review of Scar scale and Scar Measuring Devices. *Eplasty*. 2010;10(43):354–63.

Author biography

Nishita Bhosale, Assistant Professor

Yogesh Khadtare, Assistant Professor

Pramod Waghmare, Professor

Amit Chaudhari, Associate Professor

Priya Lele, Associate Professor

Neelam Gavali, Assistant Professor

Cite this article: Bhosale N, Khadtare Y, Waghmare P, Chaudhari A, Lele P, Gavali N. Frenectomy by millers technique: A case report. *IP Int J Periodontol Implantol* 2020;5(4):177-180.