



## Case Report

# Bernotti V-Y plasty Technique for root coverage procedure

Sindhu R Ghorpade<sup>1</sup>, Rajaram Vijayalakshmi<sup>1,\*</sup>, Jaideep Mahendra<sup>1</sup>,  
Burnice Nalina Kumari<sup>1</sup>

<sup>1</sup>Dept. of Periodontology, Meenakshi Ammal Dental College & Hospital, Chennai, Tamil Nadu, India



### ARTICLE INFO

#### Article history:

Received 06-03-2020

Accepted 23-09-2020

Available online 20-10-2020

#### Keywords:

Bernotti VY

Gingival recession

Root coverage

### ABSTRACT

Gingival recession is the exposure of the root surface resulting from migration of the gingival margin apical to the cemento-enamel junction (CEJ). It may be localized or generalized and can be associated with one or more tooth surfaces. Even though gingival recession may occur without any symptoms it can give rise to pain from exposed dentin, patient concern about loss of the tooth, poor esthetics or root caries. The denuded root surfaces cause deterioration in the esthetic appearance, dentin hypersensitivity, and inability to perform proper oral hygiene procedures. The Bernotti V-Y flap is a coronally advanced flap technique with a “VY” flap design, which consist of a microsurgery technique with or without connective tissue graft, that will improve mucosal biotype and keratinized band in a predictable way for isolated mucosal recession, dehiscence and translucent tissue at teeth or implant sites. It is a conservative flap design, inspired by Semilunar and Modified Semilunar Tarnow’s technique, to minimize interproximal crestal bone loss and possible loss of papillae around teeth or implants, marginal mucosal position is stabilized avoiding adverse aesthetic outcomes. Miller’s Class I and II recession defects with a minimum height of (two) 2 mm are suitable to be selected to perform the Bernotti V-Y flap. The Bernotti V-Y flap consist of a pedicle flap, making a “V” incision apical to the recession defect and the flap is coronally advanced. Stability and aesthetic outcomes are achieved with the Bernotti V-Y flap.

© 2020 Published by Innovative Publication. This is an open access article under the CC BY-NC license (<https://creativecommons.org/licenses/by-nc/4.0/>)

## 1. Introduction

Gingival recession is defined as the exposure of the root surface by an apical shift in the position of the gingiva. Recession of the gingival margin results in impaired esthetics and hypersensitivity.<sup>1</sup> Prevalence in Indian population: Mythri et al (2015): 40.98% subjects. The Bernotti v-y flap is a coronally advanced flap technique: Dr. Ana Luisa Bernotti. It is a microsurgical technique with or without connective tissue graft. It improves mucosal biotype and keratinized band in a isolated mucosal recession, dehiscence and translucent tissue, at teeth or implants sites. It is a conservative flap design, inspired in semilunar and modified semilunar tarnow’s technique.

## 2. Case I

28 year old male patient came with a chief complaint of sensitivity in upper left back tooth from past 2 months. No relevant medical and dental history present. On intraoral examination gingival recession was seen in relation to 24 with probing depth of 2 mm and CAL of 4 mm.

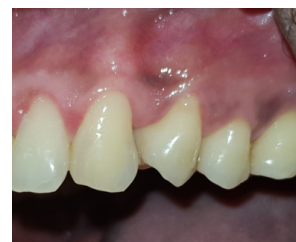
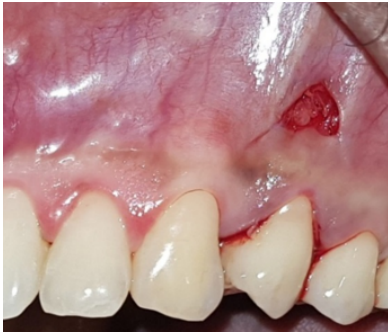
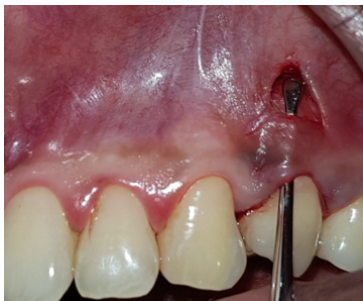Fig. 1: Pre-operative view

\* Corresponding author.

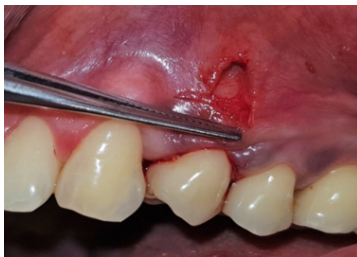E-mail address: [rajaramvijayalakshmi@gmail.com](mailto:rajaramvijayalakshmi@gmail.com) (R. Vijayalakshmi).



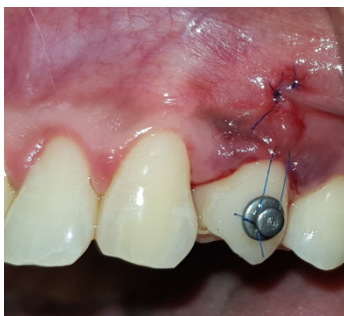
**Fig. 2:** Incision placed



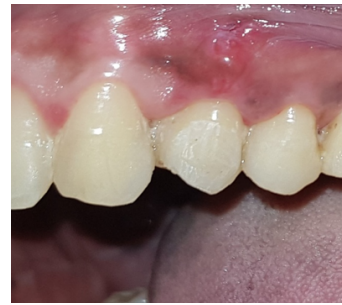**Fig. 3:** Tunneling done



**Fig. 4:** A-PRF membrane placed



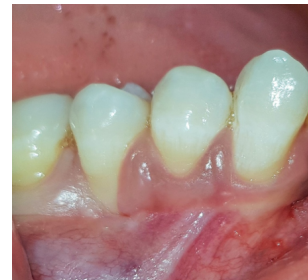**Fig. 5:** Flap sutured



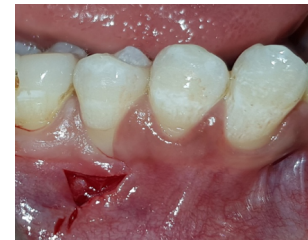**Fig. 6:** 3 months post-operative view

### 3. Case II

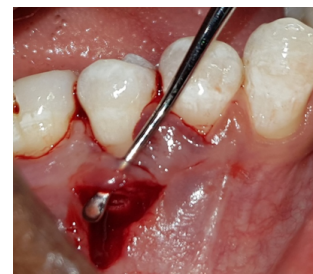26 year old male patient came with chief complaint of sensitivity in lower right back tooth from past 2 months. No relevant dental and medical history present. On intra-oral examination, gingival recession present in relation to 45 with probing depth of 1mm and CAL of 5 mm.



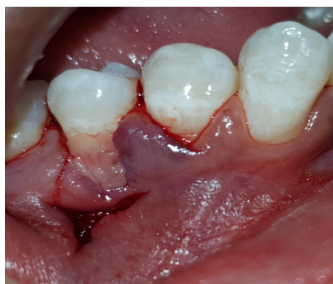**Fig. 7:** Pre-operative view



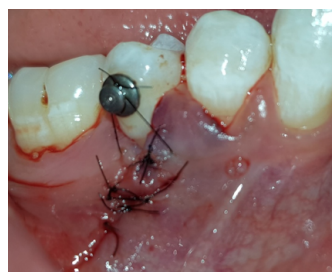**Fig. 8:** Incision placed



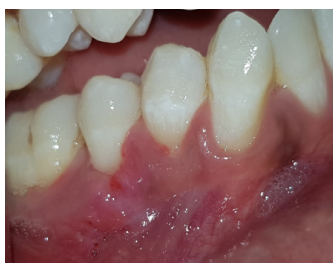**Fig. 9:** Tunneling done



**Fig. 10:** A-PRF membrane placed



**Fig. 11:** Flap sutured



**Fig. 12:** 3 months post-operative view

### 3.1. Preoperative preparation

It included thorough scaling and root planing. The clinical parameters evaluated included: Probing depth, Clinical attachment level, Recession depth (RD) and Recession width (RW). These were measured using William's probe (Figure 1). Patient was asked to pre-rinse with 0.12% chlorhexidine mouth rinse.

### 3.2. Preparation of advanced platelet rich fibrin

10 ml of venous blood of the patient is obtained. It is then centrifuged at 1500 rpm for 14 minutes. At the end of centrifugation cycle the test tube showed 3 layers. Upper layer is the plasma, middle layer is the fibrous A-PRF clot and the third layer at the bottom is RBC's.

### 3.3. Surgical Procedure

The Bernotti V-Y Flap procedure involves making a submarginal supraperiosteal V- shaped incision 1 mm to 2

mm apical to the mucogingival junction (Figures 2 and 8), creating a pedicle flap. Then flap was extended one tooth mesially and distally to the recession defect. It is important to note that the flap should leave the adjacent papillae intact in order to preserve blood supply. An intrasulcular incision was then made with a microsurgical blade and tunnelled to allow for coronal movement of the marginal tissue without tension (Figures 3 and 9). A-PRF membrane was placed after tunnelling (Figures 4 and 10). A horizontal mattress suture was placed in the mucosa, which creates the vertical slope of the Y and advances the marginal part of the flap coronally above the recession defect (Figures 5 and 11). This tension-free coronal movement of the tissue was obtained by a zipper-like effect of the horizontal mattress. Coe-pack was placed after the completion of the procedure to protect the site from food debris and trauma.

### 3.4. Post-Operative Instructions

The patient was advised amoxicillin 500 mg 8 hourly for 5 days and analgesic (Paracetamol 325 mg + Aceclofenac 100 mg) daily for three days, after food. The patient was instructed to rinse with a 0.12% chlorhexidine solution for 2 weeks. The patient was instructed to be cautious while mastication and to avoid toothbrushing at the surgical site for 14 days. Suture was removed after 2 weeks and healing was satisfactory. Complete root coverage was achieved in both the cases.

## 4. Discussion

The surgeons are now interested in more user-friendly, less invasive, esthetically favourable patient-oriented surgeries. The concept of "Extension for prevention" has now changed to "Conserve to preserve."<sup>2</sup> The concept of "minimally invasive surgery (MIS)" is one such peculiar and innovative approach which aims to produce minimal wounds, minimal flap reflection, and gentle handling of the soft and hard tissues (Harrel et al. 2005).<sup>3</sup> Various minimally invasive root coverage techniques used in the recent years have shown greater predictability and higher success rates.

Vestibular incision subperiosteal tunnel access (VISTA) (Zadeh et al 2011),<sup>4</sup> Modified VISTA technique (Lee et al 2013),<sup>5</sup> Gum drop technique (Tuttle D 2014),<sup>6</sup> Pin Hole surgery (Chao et al 2015).<sup>7</sup> Advantages of V-Y Bernotti technique includes protection to the interdental tissue, no invasive flaps or iatrogenic black triangles, provides a better blood supply, resulting in less crestal bone loss, allows for coronal movement of the marginal tissue with no tension from the suture on the vertical slope in creating the "Y" part of the flap,<sup>8</sup> allows for excellent soft-tissue match and is an alternative to conventional grafting techniques. Limitations include it is technique sensitive, needs a thicker biotype of tissue, atleast 2 mm of keratinized gingiva to show a better result.

The use of Advanced platelet rich fibrin gives an added advantage of improved vascularity and enhanced healing as it is rich with growth factors such as vascular endothelial growth factor (VEGF), platelet derived growth factor (PDGF), transforming growth factor (TGF- $\beta$ ) and fibroblast growth factor (b-FGF) among many others. The A-PRF blood clot is highly rich in neutrophilic granulocytes. These stimulate the migration of host monocytes into the site and facilitate removal of any necrotic remnants along with revascularization by recruitment of growth factors such as VEGF.<sup>9</sup>

## 5. Conclusion

The V-Y Bernotti flap technique provides a good alternative to conventional root coverage procedures especially for treatment of single isolated gingival recession. Minimal incisions, excellent wound healing<sup>9</sup> and minimal patient discomfort are some of the main advantages of this technique. However the procedure is technique sensitive and a good case selection is an important criterion for the success of this procedure. Hence further long term studies are needed to evaluate the effectiveness and success of this technique.

## 6. Source of Funding

None.

## 7. Conflict of Interest

None.

## References

- Pradeep K, Rajababu P, Satyanarayana D, Sagar V. Gingival Recession: Review and Strategies in Treatment of Recession. *Case Rep Dent.* 2012;2012:1–6.
- Dongre M, Banthia R, Ritika R, Banthia P. Minimally invasive techniques for regenerative therapy. *J Interdiscip Dent.* 2016;6(2):56.
- Harrel SK, Wilson TG, Nunn ME. Prospective Assessment of the Use of Enamel Matrix Proteins With Minimally Invasive Surgery. *J Periodontol.* 2005;76(3):380–4.
- Zadeh HH. Minimally invasive treatment of maxillary anterior gingival recession defects by vestibular incision subperiosteal tunnel access and platelet-derived growth factor BB. *Int J Periodontics Restor Dent.* 2011;31(6):653–60.
- Lee CT, Hamalian T, Schulze-Späte U. Minimally invasive treatment of soft tissue deficiency around an implant-supported restoration in the esthetic zone: modified VISTA technique case report. *J Oral Implantol.* 2013;41(1):71–6.
- Tuttle D, Kurtzman G, Bernotti AL. Gum Drop Technique: Minimally Invasive Soft-Tissue Platelet-Rich Plasma Grafting for Marginal Soft-Tissue Recession. *Compend Contin Educ Dent.* 2018;39(5):9–12.
- Chao JC. A novel approach to root coverage: The pinhole surgical technique. *Int J Periodontics Restorative Dent.* 2012;32:521–31.
- Ozcelik O, Haytac MC, Seydaoglu G. Treatment of multiple gingival recessions using a coronally advanced flap procedure combined with button application. *J Clin Periodontol.* 2011;38(6):572–80.
- Hakkinen L, Uitto VJ, Larjava H. Cell biology of gingival wound healing - Perio. *Periodontol.* 2000;24:127–52.

## Author biography

**Sindhu R Ghorpade** Post Graduate Student

**Rajaram Vijayalakshmi** Associate Professor

**Jaideep Mahendra** Professor

**Burnice Nalina Kumari** Assistant Professor

**Cite this article:** Ghorpade SR, Vijayalakshmi R, Mahendra J, Kumari BN. **Bernotti V-Y plasty Technique for root coverage procedure** . *IP Int J Periodontol Implantol* 2020;5(3):129-132.