

Tongue tie: A case report

Amit Kumar Singh^{1*}, Rashi Chauhan², Khushboo Rani³, Kriti Singh⁴

^{1,2}Reader, ^{3,4}Post Graduate Student, Dept. of Oral Medicine & Radiology, Buddha Institute of Dental Science & Hospital, Patna, Bihar, India

*Corresponding Author: Amit Kumar Singh

Email: dramitujjainsingh@gmail.com

Abstract

Tongue tie also known as Ankyloglossia is congenital disorder characterized by short, thick frenulum which causes reduced mobility of tongue it reduces possible extension such as protrusion and elevation of tongue. It is caused by short frenum or genioglossus muscle. It is seen in various age group. It causes difficulty in feeding, dental hygiene maintenance and speech. The tongue tie is most commonly appears from tip of tongue to the base of tongue.

Keywords: Ankyloglossia, Frenectomy, Tongue tie.

Introduction

The tongue is a muscular organ that affects, speech, position, of the teeth, periodontal tissue, nutrition, and swallowing. It is the non-medical term for a relatively common physical condition that limits the normal function of the tongue. Tongue –tie may lead to various functional abnormalities that include abnormal speech, mal-occlusion and Wallace defined tongue tie as “a condition in which the tip of the tongue cannot be protruded beyond the lower incisor teeth because of a short frenulum linguae, often containing scar tissue. “As defined by the International Affiliation of Tongue tie Professionals: The Embryologic remnant of the tissue in the midline of the under surface of the tongue and the floor of the mouth.

Case Report

A 20 year old male patient reported to the department of oral medicine and radiology with complaint of difficulty in moving his tongue freely and pronouncing certain words freely. Patient gave no medical problems and this was his first visit to the dentist. The patient was conscious, co-operative with normal gait. All vital signs were within normal range. On extra oral examination there was no significant findings noted Intra-oral examination revealed a short, fibrotic lingual frenum that was attached to floor of mouth. The frenum extending from the ventral surface of the tongue to the lingual gingiva of the anterior mandible. It was also observed that the patient was unable to raise his tongue to touch the palate. There was no malocclusion and recession present lingual to the mandibular incisors. On taking family history there was no such case reported in patient’s family members. A complete hemogram has been done with all the values within normal limits. On taking consent with patient’s parents an treatment plan of frenectomy with LASER guided instrument has been made. During surgical frenectomy has been performed with the removal of partial lingual frenum with the purpose to make the tongue freely movable. After performing partial frenectomy there is an immediate tongue protrusion of 20mm which was comfortable with the patient. The phonetics of the patient was improved and was kept on

antimicrobials along with NSAIDS to relief pain for 15 days with instructions to move the tongue slowly to avoid recurrence. The patient was followed up for 5 months with no recurrence and difficulty in phonetics and during intake of food.

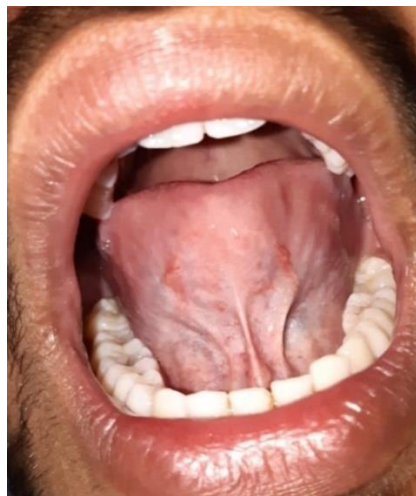

Fig. 1: Pre-operative view of subject with Kotlow Class II ankyloglossia

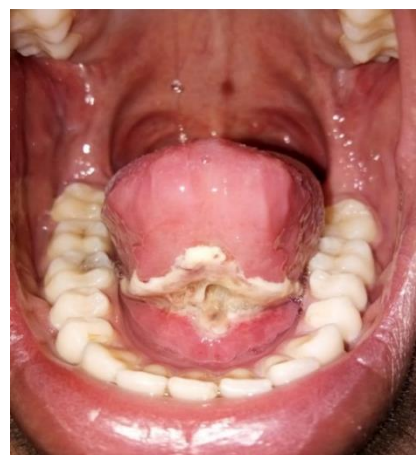


Fig. 2: Diamond shaped wound post frenulum excision

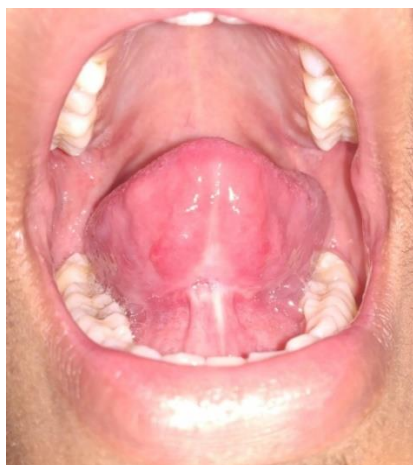

Fig. 3: Healing after 3 month

Discussion

Ankyloglossia is a developmental defect characterized by short lingual frenulum and tongue attachment to the floor of the mouth. Ankyloglossia is caused by failure in cellular degeneration which leads to longer anchor present between tongue and floor of the mouth and. The pathogenesis of ankyloglossia is not clearly known.

Table 1: Kotlow’s classification based on free tongue

Classification of Ankyloglossia		Range of free tongue
Clinically acceptable	Normal range of free tongue	>16mm
Class I	Mild ankyloglossia	12-16mm
Class II	Moderate ankyloglossia	8-11mm
Class III	Severe ankyloglossia	3-7mm
Class IV	Complete ankyloglossia	< 3mm

Ankyloglossia is associated with various rare syndromes such as X-linked cleft palate, van der Woude syndrome, Opitz syndrome and Kindler syndrome. The incidence of ankyloglossia ranges from 0.02% to as high as 4.8% according to various reports. There is no universal classification of ankyloglossia although various classifications have been proposed. Management of ankyloglossia compromise of surgical intervention,

followed by speech therapy. Surgical methods are classified as: (i) Frenectomy (ii) Frenectomy (iii) Frenuloplasty. Surgical intervention includes conventional technique with scalpel, electro cautery and laser treatment have Hemostatic coagulant and cicatrizing effect which makes it less invasive avoids excessive bleeding and reduces post-operative complication. The laser has also an advantage of antibacterial effects which decreases risk of infection, inflammation and avoid swelling. Post-operative exercise of tongue is necessary as there will be no improvement in speech. It advances ability of sensation parts of tongue and increase in alternating movement of tongue (Diadoctiokinesis).

Conclusion

Tongue tie restrict the functional ability and social ashamed due to speech problem of the individual. Due to this circumstances, correction should be done by combined laser excision and speech therapy can improve the individual life.

Source of funding

None.

Conflict of interest

None.

References

1. Tanya, Priya Lele. Ankyloglossia. Treatment with surgical Laser-A Case Report (IOSR-JDMS). 2014;13(7).
2. Madhusudhan Untying the Tongue. A Case Report. J Int Med Dent 2017;4(3):72-5.
3. Kotlow LA. Ankyloglossia (tongue tie): A diagnostic and treatment quandary. *Quintessence Int* 1999;30:259-62.

How to cite this article: Singh AK, Chauhan R, Rani K, Singh K. Tongue tie: A case report. *Int J Periodontol Implantol* 2019;4(3):113-4.