

## Comparative evaluation of intrabony defect with platelet rich plasma alone and platelet rich plasma along with bioactive glass

Prashant Singh<sup>1</sup>, Kirandeep Kaur<sup>2\*</sup>, Meghna Dewan<sup>3</sup>, Sandeep Kaur<sup>4</sup>

<sup>1</sup>Reader, <sup>2</sup>Senior Lecturer, <sup>3</sup>Senior Research Officer, <sup>4</sup>Lecturer, <sup>1,2</sup>Dept. of Periodontology & Implantology, <sup>4</sup>Dept. of Oral Medicine & Radiology, <sup>1,2</sup>Institute of Dental Sciences, Sehora, Jammu, Jammu & Kashmir, <sup>3</sup>AIIMS Cohort Study, AIIMS, New Delhi, <sup>4</sup>Indira Gandhi Government Dental College & Hospital, Jammu (J&K), India

**\*Corresponding Author: Kirandeep Kaur**

Email: drkirandeepkour@gmail.com

### Abstract

Platelet-rich plasma (PRP) has been a breakthrough in the stimulation and acceleration of bone and soft tissue healing. It represents a relatively new biotechnology that is part of the growing interest in tissue engineering and cellular therapy today. Bioactive glass (BG) is a kind of bioactive ceramic consisting of SiO<sub>2</sub>, CaO, Na<sub>2</sub>O and P<sub>2</sub>O<sub>5</sub> and results in the formation of a hydroxyapatite layer that has a stiffness closely matching the mineral phase of bone without forming fibrous tissue or promoting inflammation or toxicity. The purpose of this paper is to 1. To evaluate the role of Platelet Rich Plasma (PRP) in intrabony defects 2.) To evaluate the role of combination of Platelet Rich Plasma along with Bioactive glass in intrabony defects.

**Keywords:** Platelet rich plasma, Bioactive glass, Intrabony defect.

### Introduction

Periodontal disease, in its various forms, has afflicted humans since the dawn of history. It is a chronic inflammatory disease caused by a complex subgingival microbial plaque, producing loss of alveolar bone and connective tissue attachment. These responses tend to result in variety of intraosseous defects of various architectures.<sup>1</sup> The ultimate goal of any periodontal therapy is to prevent further attachment loss, the arrest of disease progression and the reconstitution of the lost periodontal structures.

Conventional periodontal treatment, such as scaling and root planing is highly effective at repairing disease related defects and halting the progression of periodontitis. But over the last three decades, the major goal of periodontal therapy has been shifted from repair to regeneration of periodontal tissues thereby reversing the damage to the periodontium caused by the disease process.<sup>2</sup>

Current literature suggests that there has been a great interest in polypeptide growth factors as a biologic mediator in periodontal regeneration. Of all known polypeptide growth factors, platelet-derived growth factor (PDGF) has been shown to exert a more favorable effect on periodontal regeneration and gain in clinical attachment level and defect fill in human. Platelet rich plasma (PRP) is a convenient approach to obtain autologous PDGF and TGF- $\beta$  (transforming growth factor- $\beta$ ).<sup>3</sup>

Platelet rich plasma (PRP) is an autologous concentration of human platelets in a small volume of plasma. It contains seven fundamental protein growth factors actively secreted by platelets to initiate wound healing. These growth factors include three isomers of platelet-derived growth factor (PDGF $\alpha\alpha$ , PDGF $\beta\beta$ , and PDGF $\alpha\beta$ ) and two of the numerous transforming growth factors (TGF $\beta$ 1 and TGF $\beta$ 2) vascular endothelial growth factor and epithelial growth factor. Though PRP is a platelet concentrate; it also contains 3 proteins in blood i.e. fibrin, fibronectin and vitronectin known to act as cell adhesion

molecules for Osteoconduction and as a matrix for bone, connective tissue, and epithelial migration.<sup>4</sup> The concentrate of platelets from autologous blood is obtained by using double centrifugation technique. The first hard spin will separate the red blood cells from the plasma, which contains the platelets, the white blood cells, and the clotting factors. The second soft spin finely separates the platelets and white blood cells together with a few red blood cells from the plasma. This soft spin produces the PRP and separates it from the platelet poor plasma.<sup>5</sup> PRP works through the degranulation of the  $\alpha$ -granules in platelets which contain the synthesized and pre-packaged growth factors. The active secretion of these growth factors is initiated by the clotting process of blood and begins within 10 minutes after clotting. PRP must be developed in an anticoagulated state and is used with the graft or flap within 10 minutes of clot initiation.<sup>4</sup> PRP acts on healing capable cells and leads to mitogenesis and angiogenesis. It also enhances the bone formation when applied to combinations of cellular autogenous bone and non-cellular bone substitutes.<sup>5</sup>

The effectiveness of PRP in combination with different type of grafting material, with or without GTR membrane has been evaluated in regenerative periodontal therapy. Bioactive glass (BG) is a kind of bioactive ceramic consisting of SiO<sub>2</sub>, CaO, Na<sub>2</sub>O and P<sub>2</sub>O<sub>5</sub>. The term "Bioactive" relates to the ability for bonding to bone and enhance tissue formation. When BG is brought into contact with body fluids a rapid leach of Na<sup>+</sup> and congruent dissolution of Ca<sup>2+</sup>, PO<sub>4</sub><sup>3-</sup> and Si<sup>4+</sup> takes place at the glass surface that lead to cellular responses at the interface of the glass and bone.<sup>6</sup> This interaction induces osteoconduction and osteoinduction and results in the formation of a hydroxyapatite layer that has a stiffness closely matching the mineral phase of bone without forming fibrous tissue, promoting inflammation or toxicity. Adding PRP to bioactive glass is an effective treatment modality for intrabony defects as PRP facilitates bone graft application and

contributes to soft tissue healing.<sup>7</sup> Hence, the present study has been undertaken for evaluation of treatment of intrabony defect with PRP alone and PRP along with BG, clinically as well as radiographically.

### Materials and Methods

A total of sixteen patients in age group of 18 years and older comprising both male and female patients visiting the Out-Patients Department of Periodontics and Oral Implantology, Himachal Dental College, Sunder Nagar H.P. were selected for the proposed study.

#### Inclusion Criteria

1. Patients aged 18 years and above.
2. Free from any systemic disease.
3. Maintaining good oral hygiene.
4. Clinical and radiographic indication of a proximal endosseous defect. Probing depth (PD) at the site of endosseous defect more than 6mm.
5. Absence of any occlusal interference.

#### Exclusion Criteria

1. Patients with any systemic disease.
2. Patient currently on medication affecting the coagulation mechanism.
3. Presence of any parafunctional habit.
4. Presence of furcation involvement.
5. Pregnant women.
6. Patient undergone any periodontal treatment 6 month prior to the study.

#### Armamentarium

##### Surgical Armamentarium (Fig. 1)

##### Radiographic Armamentarium (Fig. 2)

1. Complete x-ray unit having long cone for paralleling technique.
2. X- Ray film holder for long cone paralleling technique.
3. Intra-oral E-speed X-ray films (Kodak).
4. X-ray grid (Dentech-Japan).

##### Bone Graft

Bioactive glass (Perioglas) bone graft material was used in this study. It is supplied sterile, packaged either in a Tyvek-sealed PET-G cup or in a filled syringe (0.5 cc) within a second sterile barrier package. The device packages are protected by an outer shrink-wrapped cardboard box.

#### Study Design

Immediately prior to the surgery each defect of the selected patient was randomly assigned to either a combination of PRP and Bioactive glass (test group) or PRP (control group). The test group included 8 patients treated with PRP/BG whereas the control group included 8 patients treated with PRP alone. Both groups were subjected to the recording of the clinical parameters at day 0 (baseline) and 6 months post-operatively. Following clinical parameters were assessed **1.** Plaque Index (Silness and Loe, 1964), **2.** Bleeding On Probing (Ainamo & Bay 1975), **3.** Probing Depth, **4.** Clinical Attachment Level and **5.** Radiographic Assessment.

#### Preparation of Platelet Rich Plasma (PRP)

The PRP preparation was done immediately prior to surgery.

#### PRP Procurement Armamentarium (Fig. 3,4)

1. Automated Centrifugation Machine (REMI-8C)
2. Disposable Syringe 10ml
3. Glass Test Tubes -15 ml
4. Sodium Citrate Solution (anti-coagulant)
5. Micropipettes/ Disposable Syringe
6. Calcium Chloride- 10%
7. Human Thrombin
8. Tourniquet
9. Sterile gloves

#### Procedure

Under aseptic techniques, 10 ml of blood was drawn intravenously from the antecubital region of patients forearm using syringes (10ml). This was transferred to centrifugal vials containing 1.0ml of sodium citrate anticoagulant. The vials were thoroughly shaken to ensure mixture of anticoagulant with blood. The blood collected in vial containing sodium citrate anticoagulant was centrifuged at 2400 r.p.m. for 10 minutes. The supernatant formed was platelet poor plasma (PPP) and buffy coat. PPP and 1.0mm buffy coat containing RBC (Fig. 5) is collected in a fresh vial and again centrifuged at 3600 r.p.m. for 15minutes. The upper half of the supernatant is discarded and the lower half is mixed thoroughly to yield PRP. (Fig. 6)

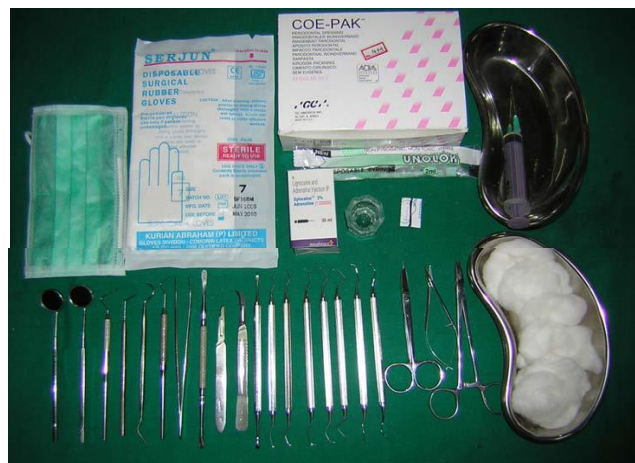

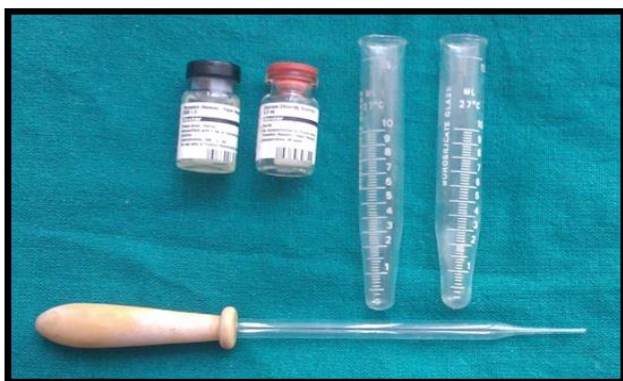Fig. 1: Surgical armamentarium



Fig. 2: Radiographic armamentarium



**Fig. 3:** Configuration machine



**Fig. 4**




**Fig. 5:** Three layers formed: PPP, Buffy coat, RBC

#### Surgical Technique

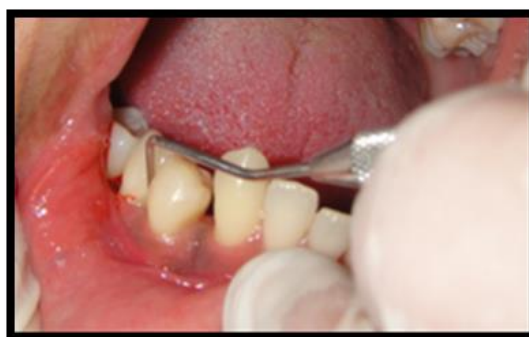The patient was comfortably seated in the dental chair and made to rinse with 0.2% Chlorhexidine digluconate for 30 seconds prior to the surgery. Facial skin all around the oral cavity was scrubbed with povidine iodine solution. Local anaesthesia 2% Lidocaine, with Adrenaline concentration of 1:200000 was administered. After confirmation of effective anaesthesia buccal and lingual intrasulcular incisions were

given with Bard Parker (blade no. 12 and 15) (Fig. 7) and full-thickness mucoperiosteal flaps were elevated using periosteal elevator (Fig. 8). Care was taken to preserve the marginal gingiva and interproximal soft tissue to achieve proper closure of the grafted site. Debridement of the defect and root planing were carried out with curettes and ultrasonic instruments. The surgical site was thoroughly irrigated with sterile saline and carefully inspected to ensure complete removal of granulation tissue. Finally 0.5 ml of PRP, 0.3ml of  $\text{CaCl}_2$  and blood harvested from surgical sight just after incision is mixed in a vial containing BG and left for gelation and placed in test side (Fig. 9) and suture is placed. The surgical site was protected with a non-eugenol periodontal dressing (Coe-Pak) for a period of one week. Radiographic X-rays were taken with grid at 0 months and 6 months (Fig. 10 & 11). In control sites PRP alone was placed. (Fig. 12-17).

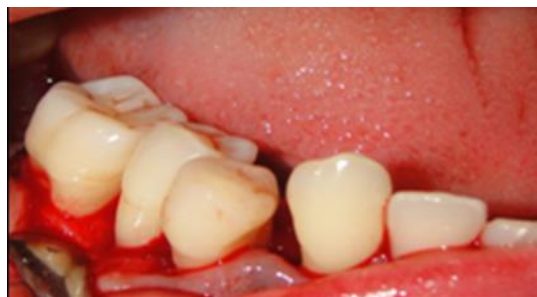

**Fig. 6:** Two layers formed: PPP, PRP

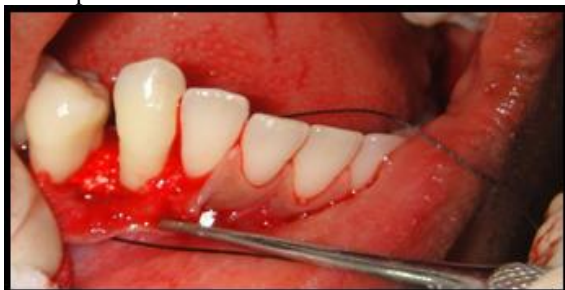#### Surgical Procedure



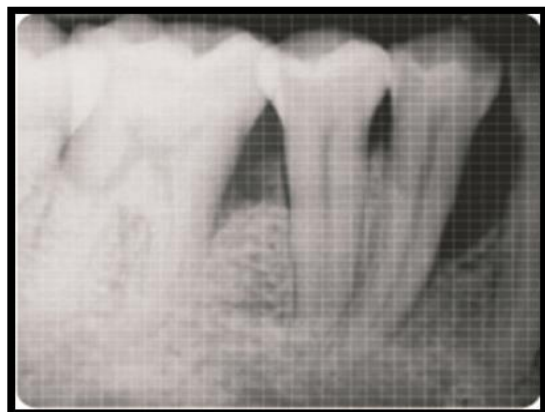**Fig 7:** Surgical site



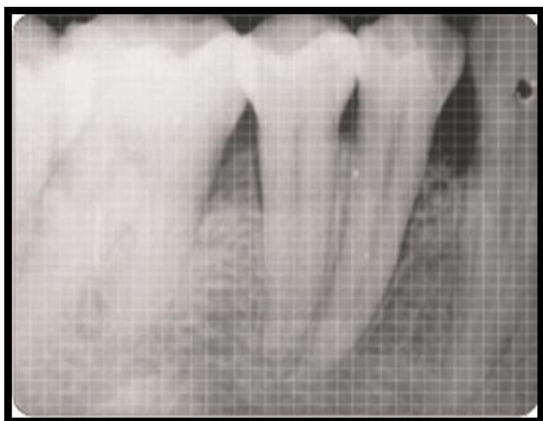**Fig. 8:** Flap reflection & debridement



**Fig. 9:** Filling the debrided defect with PRP along with perioglas

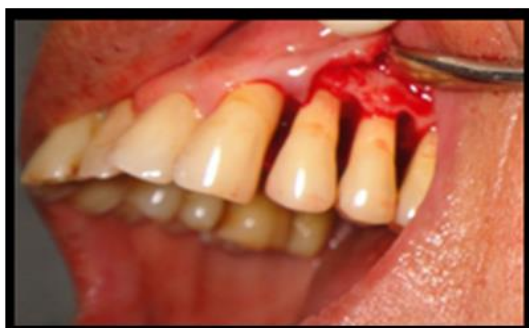

**Fig. 10:** Pre-operative baseline

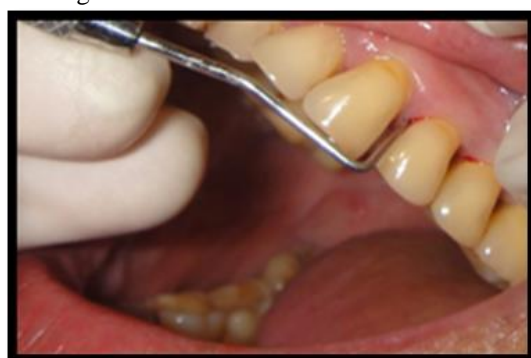

**Fig. 11:** Post operative 6 Months

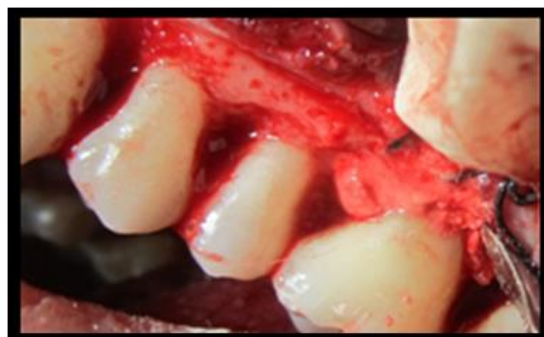**Control Site**



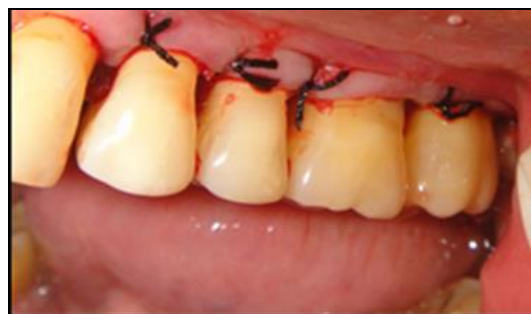**Fig. 12:** Surgical site



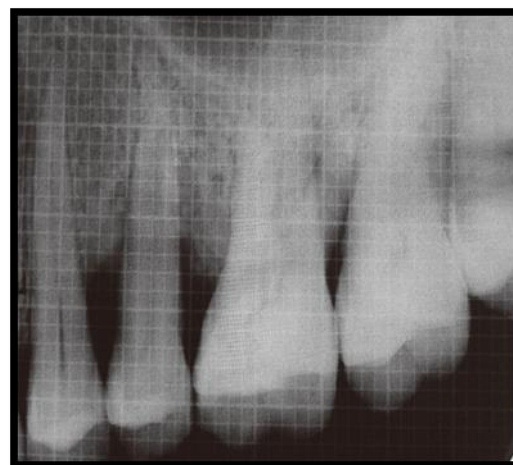
**Fig. 13:** Flap reflection & debridement



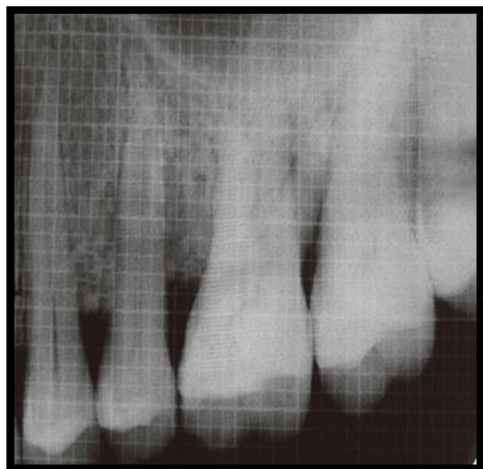
**Fig. 14:** Filling the debrided defect with PRP



**Fig. 15:** Sutures



**Fig. 16:** Pre-operative baseline



**Fig. 17:** Post-operative 6 month

### Postoperative Instructions

1. Patients were prescribed an antibiotic and anti-inflammatory course comprising of Amoxicillin and Clavulanic Acid thrice daily for 5 days, and Ibuprofen 400 mg thrice daily for 3 days.
2. Patients were advised to be on soft and cold liquid diet for first 24 hours and were advised to avoid brushing on the operated site for 10 days.
3. Patients were advised 0.2% Chlorhexidine digluconate mouth rinse for 1 minute three times daily for 14 days starting from the day of surgery.

The subjects were recalled after 7 days for removal of sutures. All the clinical parameters were recorded at the end of 0 and 6 months after surgery. The data thus collected was subjected to statistical analysis.

### Results

The present study comprised sixteen patients with age group of 18 years and older (both males and females) who visited

**Table 2:** Mean plaque index values at baseline and 6 months within the groups

PI	Baseline	6 months	Mean reduction	p-value
Group I (n=8)	1.31	0.44	0.87	P<0.01 (s)
Group 2 (n=8)	1.50	0.64	0.86	P<0.01 (s)

### Bleeding on Probing

There were no statistically significant differences between group I and group II at baseline and at 6 months (Table 3). There were statistically significant differences within the group I and group II at baseline and 6 months (Table 4).

**Table 3:** Mean Bleeding on probing values at baseline and 6 months between group I and group II

BOP	Baseline	6 Months
Group I (n=8)	0.75	0.09
Group 2 (n=8)	0.80	0.09
p-value	p>0.05 (NS)	p>0.05 (NS)

**Table 4:** Mean Bleeding on probing values at baseline and 6 months within the groups

BOP	Baseline	6 months	Mean reduction	p-value
Group I (n=8)	0.75	0.09	0.66	P<0.01 (s)
Group 2 (n=8)	0.80	0.09	0.71	P<0.01 (s)

### Probing Pocket Depth

the Department of Periodontology and Oral Implantology, Himachal dental college, Sundernagar. The study evaluated the effect of bioactive glass graft material (BG) with and without PRP clinically as well as radiographically in intrabony defects.

Group I had 8 (50%) patients who were managed for intrabony defects using PRP alone while Group II had the remaining 8 (50%) patients who were managed for intrabony defects using PRP with bioactive glass.

Evaluation of outcome was done in terms of change in following parameters:

1. Plaque index
2. Bleeding on Probing
3. Probing Pocket depth
4. Clinical attachment level
5. Radiological assessment for bone loss

All the evaluations were carried out regularly at baseline and at the end of six months after the placement of graft.

### Plaque Index

**Table 1:** Mean plaque index values at baseline and 6 months between group I and group II

PI	Baseline	6 Months
Group I (n=8)	1.31	0.44
Group 2 (n=8)	1.50	0.64
p-value	p>0.05 (NS)	p>0.05 (NS)

There were no statistically significant differences between group I and group II at baseline and at 6 months (Table 1). There were statistically significant differences within the group I and group II at baseline and 6 months (Table 2).

There was no statistically significant difference between group I and group II at baseline and 6 months (Table 5). There were statistically significant differences within the group I and group II at baseline and 6 months (Table 6).

**Table 5:** Mean Probing pocket depth values at baseline and 6 months between group I and group II

PPD	Baseline	6 Months
Group I (n=8)	4.88	3.83
Group 2 (n=8)	5.15	3.58
p-value	p>0.05 (NS)	p>0.05 (NS)

**Table 6:** Mean Probing pocket depth values at baseline and 6 months within the groups

PPD	Baseline	6 months	Mean reduction	p-value
Group I (n=8)	4.88	3.83	1.05	P<0.001 (S)
Group 2 (n=8)	5.15	3.58	1.57	P<0.001 (S)

### Clinical Attachment Level

There were no statistically significant differences between group I and group II at baseline and at 6 months (Table 7). There were statistically significant differences within the group I and group II at baseline and 6 months (Table 8).

**Table 7:** Mean Clinical attachment level values at baseline and 6 months between group I and group II

CAL	Baseline	6 Months
Group I (n=8)	5.08	4.02
Group 2 (n=8)	5.42	3.33
p-value	p>0.05 (NS)	p>0.05 (NS)

**Table 8:** Mean Clinical attachment level values at baseline and 6 months within the groups

PD	Baseline	6 months	Mean gain	p-value
Group I (n=8)	5.08	4.02	1.06	P<0.05 (S)
Group 2 (n=8)	5.42	3.33	2.09	P<0.05 (S)

### Radiographic Assessment

There were no statistically significant differences between the group I and group II at baseline and at 6 months (Table 9). There were statistically significant differences within the group I and group II at baseline and 6 months (Table 10).

**Table 9:** Mean Radiological bone level values at baseline and 6 months between group I and group II

RBL	Baseline	6 Months
Group I (n=8)	4.50	2.75
Group 2 (n=8)	5.63	2.38
p-value	p>0.05 (NS)	p>0.05 (NS)

**Table 10:** Mean Radiological bone level values at baseline and 6 months within the groups

PD	Baseline	6 months	Mean difference	p-value
Group I (n=8)	4.50	2.75	1.75	P<0.05 (S)
Group 2 (n=8)	5.63	2.38	3.25	P<0.05 (S)

### Discussion

Successful periodontal regeneration relies on the reformation of an epithelial seal, deposition of new acellular extrinsic fiber cementum and insertion of functionally oriented connective tissue fibers into the root surface, and restoration of alveolar bone height. For decades, filling of periodontal defect with different types of bone graft was used to restore the lost periodontal attachment, but the result showed varying degree of success.

The use of bone grafts for reconstructing osseous defects produced by periodontal disease dates back to Hegedus in 1923 and was reviewed by (Nabers & O' Leary

in 1965). Since that time, a number of techniques and materials have been used for regeneration.<sup>8</sup>

Bioactive glass is a non-resorbable material whose medical use evolved 25 years ago due to its reported advantage of forming a strong bond with living tissues, both bone and soft connective tissue and to its having a modulus of elasticity similar to that of bone. In the presence of body fluids, through a series of ion exchange reactions, bioactive glass forms a surface layer consisting of two parts: inner silica (si)-rich layer and an outer calcium-phosphate (cap)-rich layer. This cap-rich layer is believed to encourage osteoblasts to deposit organic bone matrix. Ionic sites on collagen and mucopolysaccharides of the organic bone matrix cross-link with sites on the cap-rich layer. This cross-

linking achieves a bond between bioactive glass and the surrounding bone (Hench et al 1974).<sup>9</sup>

Autogenous graft is regarded as the gold standard for the repair of the intrabony defect. (Marks in 1998)<sup>10</sup> introduced Platelet rich plasma, an autologous source of growth factor obtained by sequestering and concentrating platelets, in a safe and convenient manner, for enhancing bone and periodontal regeneration.

So the present study was undertaken to determine the clinical and radiographic evaluation in the two groups to determine the efficacy of PRP alone and PRP with bioactive glass in the intrabony defect in sixteen patients who visited the outpatient Department of Periodontology and Oral Implantology, Himachal dental college, Sundernagar.

### Plaque Index

Plaque control is essential to minimize the influence of excessive plaque accumulation for better treatment outcome. This variable is totally dependent on the patient's compliance and his/her efficacy to maintain oral hygiene. In this study mean reduction in plaque index was observed in both groups. The mean reduction in plaque index on intergroup evaluation was found to be statistically non-significant at baseline and 6 months between group I and group II (Table 1). The mean reduction in plaque index within the group I and group II at baseline and 6 months was found to be statistically significant. (Table 2). These results are due to continuous periodic recall, constant motivation, education and oral hygiene instructions revision to the subjects. The results of our study are in agreement with the study by Anton Sculean et al. 2002, Anton Sculean et al. 2005 and Demir B et al. 2007.<sup>3,25,62,11-13</sup>

### Bleeding on Probing

Bleeding on probing (BOP) is a widely used criterion to diagnose gingival inflammation. The mean bleeding on probing in group I and group II at baseline was due to the subgingival deposits which lead to the ulceration in the pocket, which ultimately bleed on probing. The results of our study showed statistically non-significant differences in mean bleeding on probing between the group I and group II at baseline and at 6 months. (Table 3) The mean reduction in bleeding on probing was found to be statistically significant within the groups at baseline and 6 months. (Table 4). These results are in accordance with the studies by Sculean A et al 2002, Okuda K et al 2005.<sup>12,14</sup>

### Probing Pocket Depth

In our study, mean reduction in pocket depth was statistically significant for group I from baseline to 6 months. (Table 6). The results of this study are similar to the findings of Froum et al (1998) and Marianne M.A (1998)<sup>16,17</sup> who demonstrated notable improvement in the reduction of pocket depth. In group II mean reduction in pocket depth was also statistically significant 6 months post-surgery. (Table 6). The results of this study are similar to the findings of Lovelace et al (1998), Mellonig et al (1984)<sup>18,19</sup> who demonstrated reduction in pocket depth. On

comparison between the two groups at 6 months post-surgery, mean reduction in pocket depth was statistically not significant. (Table 5) Results of this study are similar to findings of Lovelace et al (1998).<sup>18</sup> This reduction in probing pocket depth can be attributed to soft and hard tissue improvements and to the osteogenic potential of the bone graft material used in the study.

### Clinical Attachment Level

Reduction in pocket depth and gain in clinical attachment level are the most important clinical outcome of regenerative therapy. It is well documented that gain in clinical attachment level after any type of regenerative conventional periodontal treatment is dependent on the initial pocket depth i.e. deeper the initial pocket depth, the greater the pocket depth reduction and clinical attachment gain (Ramfjord SP et al 1987).<sup>20</sup> In our study, mean gain in clinical attachment level was statistically significant for the Group I at 6 months.(Table 8) The results of this study are similar to the findings of Froum et al (1998).<sup>16</sup> In the Group II at 6 months the mean gain in clinical attachment level was statistically significant. (Table 8). The results of our study are similar to the findings of Lovelace et al (1998),<sup>18</sup> Mellonig et al (1984).<sup>19</sup> On comparison between the two groups at 6 months post-surgery mean gain in clinical attachment level was statistically not significant.(Table.7). Results of this study are similar to findings of Lovelace et al (1998).<sup>18</sup>

### Radiographic Assessment

The mean bone level at baseline in group I is 4.50 and in group II is 5.63. The mean gain in bone level at 6 months in group I was 2.75 and in group II was 2.07. The mean bone fill was found to be significant within the group at 6 months. (Table 10) This is because of the positive effects of PRP on bone formation due to the growth factors present in PRP: PDGF, TGF- $\beta$ ,VDGF, for osteoconduction that is fibrin, fibronectin and vitronectin (Tozum & Demiralp 2003).<sup>21</sup> Therefore, PRP may influence bone formation through different pathways.

### Conclusion

Periodontal repair is healing of the peridontium by tissue that does not fully restore the original functional anatomic and morphologic architecture. The purpose of this prospective study is to provide an overview of the biologic function and clinical application of bone replacement grafts for periodontal regeneration. Clinical outcome parameters consistent with successful regenerative therapy include reduced probing depth, increased clinical attachment level, and radiographic evidence of bone fill.

A total of 16 systemically healthy patients with intrabony defect were treated with PRP alone and PRP along with bioactive glass. Presurgical, clinical and radiographical evaluation along with complete patient examination was done to estimate the prognosis as well as to aid in the treatment planning. The objective of the treatment modality was investigated through statistical

analysis. The results thus obtained are summarized in the tables and figures. The analysis of the hard and soft tissue determined the effectiveness of the bone graft materials used in this study.

In future studies the increase in the sample size and long term studies need to be done. Future bone grafting materials will likely build on innovative polymeric and ceramic platforms with controlled biophysical properties that enable the targeted delivery of drugs, biologics, and cells, thereby improving the degree and predictability of periodontal regeneration.

**Conflict of Interest:** None.

## References

- Newman, Takei, Klokkeveld, Carranza. 10<sup>th</sup> edition. Saunders: *Clin Periodontol* 2010.
- Selcuk Yilmaz, Gokser Cakar, Sebnem Dirikan. 1<sup>st</sup> edition, Intech: Progress in Molecular and Environmental Bioengineering- From analysis and Modeling to Technology Application; 2011.
- Vojislav Lekovic, Paulo M Camarg, Michael Weinlaender. Comparison of Platelet Rich Plasma, Bovine Porous Bone Mineral, and Guided Tissue Regeneration Versus Platelet Rich Plasma and Bovine Porous Bone Mineral in the Treatment of Intrabony Defects: A Reentry Study. *J Periodontol* 2002;73(2):198-205.
- Robert E. Marx. Platelet-Rich Plasma: Evidence to Support Its Use. *J Oral Maxillofac Surg* 2004;62:489-96.
- Robert E. Marx. Platelet Rich Plasma (PRP): What Is PRP and What Is Not PRP. *J Implant Dent* 2001;10(4):225-8.
- Salonen Ji, Arjasmaa M, Tuominen U. Bioactive Glass in Dentistry. *J Minim Interv Dent* 2009;2(4):208-19.
- Keyvan Sohrbi, Veeral Saraiya, Thomas A. Laage. An Evaluation of Bioactive Glass in the Treatment of Periodontal Defects: A Meta-Analysis of Randomized Controlled Clinical Trial. *J Periodontol* 2012;83(4):453-64.
- Paul. S. Rosen, Mark. A. Reynolds, Geral M. Treatment of intrabony defects. *Periodontol* 2000;22:88-103.
- Marriane M.A.Ong, Robert M Eber, Maria I Korsnes. Evaluation of a bioactive glass alloplast in treating periodontal intrabony defects. *J Periodontol* 1998;69:1363-54.
- Marx RE, Carlson ER, Eichstaedt RM. Platelet-rich plasma: growth factor enhancement for bone grafts: *Oral Surg Oral Med Oral Pathol Oral Radiol Endod* 1998;85:638-46.
- Demir B, Rengu D, Berberoglu A. Clinical evaluation of platelet-rich plasma and bioactive glass in the treatment of intra-bony defects. *J Clin Periodontol* 2007;34:709-15.
- Anton Sculean, Giovanni Barbie, Giovanni C. Clinical Evaluation of an Enamel Matrix Protein Derivative Combined With a Bioactive Glass for the Treatment of Intrabony Periodontal Defects in Humans. *J Periodontol* 2002;73(4):401-8.
- Sculean A, Pietruska M, Schwarz F. Healing of human intrabony defects following regenerative periodontal therapy with an enamel matrix protein derivative alone or combined with a bioactive glass. *J Clin Periodontol* 2005;32:111-7.
- Kanoko Yamamiya, Kazuhiro Okuda, Tomoyuki Kawase. Tissue-Engineered Cultured Periosteum Used With Platelet-Rich Plasma and Hydroxyapatite in Treating Human Osseous Defects: *J Periodontol* 2008;79:811-8.
- Stuart J Froum, Mea.A. Weinberg and Dennis Tarnow. Comparison of Bioactive glass synthetic bone graft particles and open debridement in the treatment of human periodontal defects: A clinical study: *Journal of Periodontol* 1998;69:698-709.
- Marriane M.A. Ong, Robert M Eber, Maria I Korsnes, R. Lamont Macneil, Gerald N Glickman, Yu Shye. Evaluation of a bioactive glass alloplast in treating periodontal intrabony defects: *Journal of Periodontol* 1998;69:1363-4.
- Teri Brooks Lovelace, James T. Mellonig A, Roland M. Clinical Evaluation of Bioactive Glass in the Treatment of Periodontal Osseous Defects in Humans: *J Periodontol* 1998;69:1027-35.
- Mengel R, Soffner M, Jacoby LF. Bioabsorbable membrane and bioactive glass in the treatment of intrabony defects in patients with generalized aggressive periodontitis: Results of 12-month clinical and radiological study. *J Periodontol* 2003;74:899-908.
- Ramfjord SP, Caffesse RG, Morrison EC. Four modalities of periodontal treatment compared over five years. *J Periodontol Res* 1987;22:222-33.
- Tozum T.F. and Demiralp B. Platelet rich plasma: a promising innovation in dentistry. *J Can Dent Assoc* 2003;69:664.

**How to cite this article:** Singh P, Kaur K, Dewan M, Kaur S. Comparative evaluation of intrabony defect with platelet rich plasma alone and platelet rich plasma along with bioactive glass. *Int J Periodontol Implantol* 2019;4(2):40-7.