

Socket shield technique for immediate implant placement

Shalu Chandna Bathla^{1,*}, Ramesh Ram Fry², Kriti Goyal³, Samta Goyal⁴, Sanjay Talnia⁵

^{1,2}Professor, ³Senior Lecturer, ^{1,3}Dept. of Periodontology, ²Dept. of oral and Maxillofacial Surgery, ¹⁻³M. M. College of Dental Sciences and Research, Mullana, Haryana, ⁴Private Practitioner, Zirakpur, Punjab, ⁵Private Practitioner, Ambala, Haryana, India

***Corresponding Author:**

Email: periodonticsrevisited@gmail.com

Abstract

The placement of immediate implants in aesthetic anterior region usually possess a challenge in implant dentistry. After tooth extraction, the buccal bone inevitably undergoes remodelling with associated resorption and diminished horizontal and vertical size of the alveolar ridge. To maintain the original buccal bone dimension after tooth extraction practitioners can choose multiple techniques like atraumatic extraction, immediate implant placement, socket preservation, socket augmentation and extensive buccal bone grafts and barrier membranes. However these techniques could partly compensate but not avoid the resorption process thus a better technique called socket shield technique have been proposed. In socket shield technique, a partial buccal root fragment is retained around an immediately placed implant with the aim of avoiding facial tissue alterations after tooth extraction. The literature related to socket shield technique reports promising solution and hold significant potential for immediate implant placement specifically in anterior aesthetic region.

Keywords: Socket Shield, Atraumatic extraction, Immediate implantation

Key Message:

1. Socket Shield physiologically helps to preserve labial and buccal bone.
2. Socket shield technique requires minimal material and is minimal invasive.
3. Socket shield with immediate implant placement reduces the required treatment time and number of surgical procedures as compared to a delayed conventional approach.

Introduction

Successfully osseointegrated implants essentially require adequate quality and quantity of bone at the implant site. But once the tooth is extracted, the buccal alveolar ridge inevitably undergoes remodelling with associated resorption and diminished horizontal and vertical size of the ridge.¹ To maintain the original ridge dimension after tooth extraction different techniques such as atraumatic extraction, immediate implant placement, socket preservation,² socket augmentation³ and extensive buccal bone grafts and barrier membranes⁴ have been proposed. However these techniques could partly compensate but not avoid the resorption process thus a better technique was desired. In an attempt to overcome this challenge socket shield technique was introduced by Hurzeler et al in 2010.⁵ In this procedure, a partial buccal root fragment is retained around an immediately placed implant with the aim of avoiding tissue alterations after tooth extraction.⁶ An immediate implant has been defined as an implant inserted right after tooth extraction at the same surgery.⁷ Immediate implant technique was originally described for osseointegrated implants by Schulte et al.⁸ The implant placement at the time of tooth extraction has several advantages: shortens treatment time due to fewer patient visits; helps to preserve vertical bone height enabling the placement of wider and longer implants; prevents alveolar ridge atrophy and gingival tissue collapse and recession; replicates the position of extracted tooth, thus minimizing the need of angled abutment.⁹ Moreover, immediate implants placement is patient friendly as it

allows the patient to leave the dental office with a fixed provisional on the same day. Immediate implantation is very demanding both in terms of surgically and prosthetically compared to conventional implant placement technique.¹⁰

There are certain indications and contraindications for socket shield immediate implant placement.¹¹

Indications:

1. Vertical fracture of teeth without pulpal pathologies
2. Non restorable asymptomatic tooth with healthy and stable buccal root
3. Tooth with healthy gingival tissue
4. Adequate amount of bone volume apical to the extraction socket to support implant

Contraindications:

1. Absent buccal lamina which develops for instance after vertical root fractures or periodontitis
2. Signs of active infection such as purulent discharge, tenderness related to tooth planned for extraction
3. Large osseous defect in the extraction socket
4. Mobile tooth with inadequate height or width of bone apical to extraction socket
5. Poor quality of bone
6. Inadequate marginal soft tissue around the socket

Rationale behind socket shield technique is to prevent the post-extraction bone resorption and to support the buccal / facial soft and hard tissues, as most of the bone resorption occurs during the first year post extraction and 2/3rd of bone loss occurs within the first 3 months post extraction. The root of a tooth indicated for extraction is prepared in such a manner that the buccal

root section remains in-situ with its physiologic relation to the intact buccal plate. The tooth root section's periodontal attachment apparatus is intended to remain undamaged and unmanipulated.¹²

Steps

Following are the steps for socket shield immediate implantation in the anterior region/ aesthetic zone (Fig. 1-3):

- 1. Root sectioning:** Tooth root is sectioned along its long axis mesiodistally as far apical as possible with hydrated high speed handpiece and long tapered fissure diamond bur into two halves. The root is split vertically into 1/3rd facial and 2/3rd palatal halves.
- 2. Atraumatic root extraction:** Start the extraction of palatal half of the root with thin scalpel blade giving incision within the sulcus around the root, to dissect the connective tissue attachment fibers present above the bone.^[13] Later on, atraumatic extraction is to be done with periostomes, luxators and forceps preserving the facial root section undamaged and attached facial bone and soft tissue to the tooth socket to the greatest possible extent before immediate implantation. Thus, smaller facial root fragment is retained and larger palatal root fragment is removed.
- 3. Socket Shield Preparation:** Buccal socket shield's height is aligned with bone. The rest palatal extraction socket is inspected for any defect under magnification and illumination. Tooth socket's palatal wall and apex should be curetted well to remove any residual infection and granulation tissue. Socket is irrigated with antibiotic (inj Clindamycin 600mg) followed by 0.12% Chlorhexidine.
- 4. Drilling protocol:** In maxillary anterior region, drilling should be done in palatal wall and not in the socket. Round bur is used to prepare the purchase point in the palatal wall. Alternatively, side cutting drill i.e Lindemann drill is used. Initially the drill exit at the incisal edge and subsequently drill is straightened to get palatal access hole and drill exit at the cingulum. It should be done 4 to 5mm beyond the socket. All the osteotomy drill should be used in the same direction and depth. Final drill should not contact the socket shield. Jumping distance is kept purposefully to ensure bone grafting in the area.
- 5. Implant placement:** Root dimensions should be measured to select the implant of appropriate diameter and length. Tapered implants are preferred due to its excellent initial fixation. They require minimal drilling and achieve primary stability even in low density bone. Chances of socket shield perforation is lesser with tapered implants. Cervico-incisally implant should be 3 to 4mm apical to free gingival margin of adjacent teeth. Implant shoulder should be placed 1 to 2mm apical to the labial CEJ of adjacent teeth. If recession is there on adjoining teeth, using CEJ as a guide will provide a poor

aesthetic result. Specifically the coronal position of maxillary canines and central incisor is located 3 to 4 mm apical to the midpoint of the facial free gingival margin. In maxillary lateral incisor, the normal apical distance from free gingival margin is 2 to 3mm.

- 6. Bone grafting:** Grafting is done in jumping distance present between the implant and socket shield. Autograft, allograft, xenograft or synthetic bone graft can be used as graft. Graft acts as a scaffold to maintain hard and soft tissue volume and also maintains blood clot. Slow-resorbing bone graft is preferred to fill the gap between the socket shield and implant to predictably preserve bone volume till new bone is not formed.
- 7. Temporization:** Pre-existing positions of the gingival margin and papillae can be maintained by provisional crown supporting the gingival architecture. Insertion torque of 30 to 40 Ncm should be achieved while placing abutment and provisional crown. The provisional prosthesis should be out of occlusion.
- 8. Postoperative instructions and care:** Following postoperative instructions should be provided to the patient in both verbal and written form: Liquid diet for 2 days and then soft diet for one week. Antibiotics – Amoxicillin with clavulanate potassium 625 mg BID for 7 days; Ibuprofen 600 mg QID for 3 days; 1.2% Chlorhexidine mouth 30 cc BID for 14 days. Avoid biting from the surgical site. Avoid smoking, sucking liquid with straw and carbonated drinks. To avoid some bruising and facial swelling apply ice packs over face; 10 minutes on and 10 minutes off.

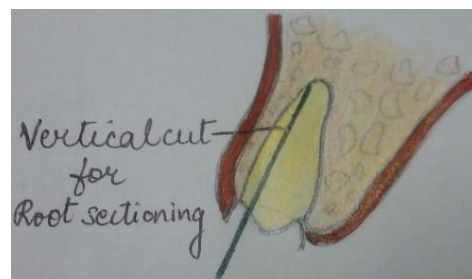


Fig. 1: Vertical cut for root sectioning

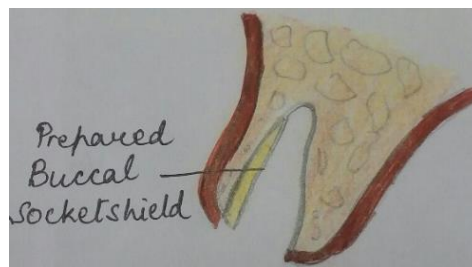


Fig. 2: Prepared buccal socket shield

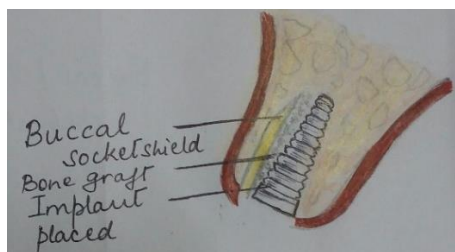


Fig. 3: Buccal socket shield, Bone graft and Implant placed

Discussion

Generally, buccal bone plate is thinner than lingual/palatal bone. The crest of the buccal bone is mainly composed of bundle bone. After tooth extraction, 20% of the blood supply from the periodontal ligament blood vessel is discontinued and with buccal flap elevation the periosteal blood supply also discontinued for 4 to 6 days till new anastomoses occur. The thin cortical buccal plate has no endosteal blood vessels; therefore complete resorption of the buccal plate may occur. This socket shield procedure prevents the resorption of thin buccal bone. However, very few comparative clinical studies have evaluated the fate and stability of the buccal bone over time with or without socket shield.

In socket shield technique, proper case selection is of prime importance. The remaining root and its periodontal ligament must be healthy and sound without mobility and pathology. Impaired periodontal status negatively affect the long term stability of peri-implant tissue and also interfere with implant bed preparation. The simple and clinically relevant classification for extraction socket morphology was given by Elian and Tarnow.¹⁵ Type I- socket with intact buccal plate and soft tissue; Type II- socket with hard tissue loss and without soft tissue loss; Type III- both hard as well as soft tissue loss. For immediate implant placement in the anterior aesthetic zone, type I socket is the ideal one. Thin gingival biotype is when the probe is visible when placed in the sulcus and thick biotype is when the probe is not visible.¹⁶ After implant placement in the aesthetic zone, thin biotype predisposes individuals to marginal tissue recession and loss of papillae.¹⁷ In the aesthetic zone, if the gingival biotype is thin, the implant is placed more palatally and apically. Tapered, self tapping, self cutting implant with deeper threads at the apex is preferred for immediate implantation. At the centre of the implant, threads should be shallow square and threads in the cervical area should be passive to avoid pressure on the crestal bone. Roughened sandblasted and acid etched implant surface should be preferred as it improves the bone implant contact percentage during initial bone healing.¹⁸

Following an extraction, implant positioning in socket shield technique depends on the orientation of the root socket. The 3 D implant positioning

(mesiodistal, faciolingual and cervico-incisal) allows maximum primary stability and restorability.¹⁹ Greater amount of bone resorption occurs in case the implant is placed closer to the buccal plate.^{20,21} Placing narrower implant create a gap of more than 2 mm between the buccal plate and implant allowing greater bone fill after grafting. Greater bone fill, in turn allows greater soft tissue fill on the facial aspect and between the adjacent teeth and the implant. Placement of wider implant encroach the buccal plate resulting in additional bone loss as opposed to retaining bone. Implants placed too buccally manifest 3 times more recession than lingually placed implants.²² This is the reason why slightly narrower implant is usually placed 1mm subcrestally.²³

Accurate assessment of primary stability is very important in the immediate implant placement.²⁴ The common methods of measuring implant stability are Resonance frequency analysis (RFA) and insertion torque.²⁵ RFA values indicate the resistance to bending load while insertion torque values indicate the resistance to shear forces.²⁶ During immediate implantation, overprepare the osteotomy length by extending the osteotomy 3 to 5 mm past the socket apex without encroaching on vital structures for primary stability. Underprepare the osteotomy width due to the relative absence of high density native bone as compared to a healed site. Immediate implantation can be simplified with the use of osteotomes as they causes radial bone compaction.

While Hurzeler et al⁵ described labial shield (Fig. 4), Kan and Rungcharassaeng gave proximal socket shield (Fig. 5) for inter-implant papilla preservation. Root was sectioned into mesial and distal halves and the jump gap was grafted with xenograft.²⁷ Disadvantages associated with the socket shield are its technique sensitivity and long term data related to behaviour of buccal shield are not available and thus not yet reliable or predictable procedure. Moreover, resorption associated with usual biological long term complication that may occur especially in the presence of pre-existing or developing periodontal or endodontic infections or in laminations of the retained root fragments.¹²

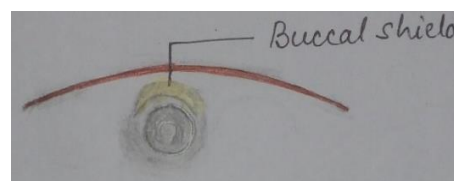


Fig. 4: Buccal/labial socket shield

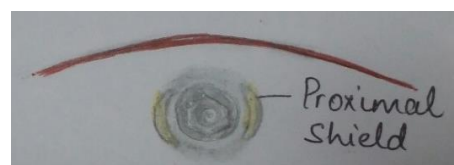

Fig. 5: Proximal socket shield

Conclusion

Socket shield technique prevents the recession of tissue buccofacial to an immediately placed implant in aesthetic region. Thus, socket shield technique offers promising solution to the difficulties encountered while managing the post extraction tissues.

Funding: No funding sources.

Conflict of interest: None declared.

References

1. Araújo MG, Lindhe J. Dimensional ridge alterations following tooth extraction. An experimental study in the dog. *J Clin Periodontol* 2005;32:212-8.
2. Sezavar, M, Bohlouli B, Motamedi MH, Jahanbani J, Hosseini MS. Socket preservation: Allograft vs alloplast. *J Cytol Histol* 2015;S3:009.
3. Nevins M, Mellonig JT. The advantages of localized ridge augmentation prior to implant placement: A staged event. *Int J Periodontics Restorative Dent* 1994;14:96-111.
4. Froum S, Cho SC, Elian N, Rosenberg E, Rohrer M, Tarnow D. Extraction sockets and implantation of hydroxyapatites with membrane barriers: A histologic study. *Implant Dent* 2004;13:153-64.
5. Hurzeler MB, Zuhr O, Schupbach P, Rebele SF, Emmanouilidis N, Fickl S. The socket-shield technique: a proof of principle report. *J Clin Periodontol* 2010;37:855-62.
6. Chen CL, Pan YH. Socket shield technique for ridge preservation: A case report. *J Prosthodont Implant* 2013;2:16-21.
7. Wilson TG Jr, Weber HP. Classification of and therapy for areas of deficient bony housing prior to dental implant placement. *Int J Periodontics Restorative Dent* 1993;13:451-9.
8. Schulte W, Kleineikenscheidt H, Schareyka R, Heimke G. Concept and testing of the Tübingen immediate implant (in German). *Dtsch Zahnärztl Z* 1978;33:319-25.
9. Paolantonio M, Dolci M, Scarano A, Archivio D, Di Placido G, Tumini V, et al. Immediate implantation in fresh extraction sockets. A controlled clinical and histological study in man. *J Periodontol* 2001;72:1560-71.
10. Crespi R, Cappare P, Gherlone E, Romanos GE. Immediate versus delayed loading of dental implants placed in fresh extraction sockets in the maxillary esthetic zone: a clinical comparative study. *Int J Oral Maxillofac Implants* 2008;23:753-8.
11. Swyeta GJ, Vivek G and Amit G. Socket Shield Technique- An Armour & Boon to Implant Dentistry. *J Dental Sci* 2017;2:000152.
12. Gluckman H, Du Toit J, Salama M. The socket-shield technique to support the buccofacial tissues at immediate implant placement. *Int Dent Africa Ed* 2015;5:6-14.
13. Misch CE, Perez HM. Atraumatic extractions: a biomechanical rationale. *Dent Today* 2008;27:100-1.
14. Misch CE. Single tooth implant restoration: Maxillary anterior and posterior regions. In: Misch CE editor. *Dent Implant Prosthet* 2nd ed. Elsevier Mosby; 2015;499-552.
15. Elian N, Cho SC, Froum S, Smith RB, Tarnow DP. A simplified socket classification and repair technique. *Pract Proced Aesthet Dent* 2007;19:99-104.
16. De Rouck T, Eghbali R, Collys K, De Bruyn H, Cosyn J. The gingival biotype revisited: Transparency of the periodontal probe through the gingival margin as a method to discriminate thin from thick gingiva. *J Clin Periodontol* 2009;36:428-33.
17. Lee A, Fu JH, Wang HL. Soft tissue biotype affects implant success. *Implant Dent* 2011;20:e38-e47.
18. Lin GH, Chan HL, Wang HL. Effects of currently available surgical and restorative interventions on reducing midfacial mucosal recession of immediately placed single-tooth implants: A systematic review. *J Periodontol* 2014;85:92-102.
19. Misch CE. Single tooth implant restoration: Maxillary anterior and posterior regions. In: Misch CE editor. *Dent Implant Prosthet* 2nd ed. Elsevier Mosby; 2015. pp 499-552.
20. Becker W, Wikesjö UM, Sennerby L, Qahash M, Hujuel P, Goldstein M, et al. Histologic evaluation of implants following flapless and flapped surgery: a study in canines. *J Periodontol* 2006;77:1717-22.
21. Favero G, Botticelli D, Favero G, García B, Mainetti T, Lang NP, et al. Alveolar bony crest preservation at implants installed immediately after tooth extraction: an experimental study in the dog. *Clin Oral Implants Res* 2013;24:7-12.
22. Evans CD, Chen ST. Esthetic outcomes of immediate implant placements. *Clin Oral Implants Res* 2008;19:73-80.
23. Lin GH, Chan HL, Wang HL. Effects of currently available surgical and restorative interventions on reducing midfacial mucosal recession of immediately placed single-tooth implants: A systematic review. *J Periodontol* 2014;85:92-102.
24. Javed F, Romanos GE. The role of primary stability for successful immediate loading of dental implants. A literature review. *J Dent* 2010;38:612-20.
25. Degidi M, Daprile G, Piattelli A. Determination of primary stability: a comparison of the surgeon's perception and objective measurements. *Int J Oral Maxillofac Implants* 2010;25:558-61.
26. Sennerby L, Meredith N. Resonance frequency analysis: measuring implant stability and osseointegration. *Compend Contin Educ Dent* 1998;19:493-8.
27. Kan JY, Rungcharassaeng K. Proximal socket shield for interimplant papilla preservation in the esthetic zone. *Int J Periodontics Restorative Dent* 2013;33:e24-e31.

How to cite the article: Bathla S, Fry R, Goyal K, Goyal S, Tania S. Socket shield technique for immediate implant placement. *IP Int J Periodontol Implantol* 2018;3(3):87-90.