

Comparison of guided tissue regeneration using an equine bio-absorbable collagen membrane with equine bone graft with bovine bio-absorbable collagen membrane with bovine bone graft in the management of intrabony defects a results of 18 month

Sudhanshu Agrawal¹, Dipti Singh², Pradyumna Misra³, Neeta Misra^{4,*}

^{1,2}Associate Professor, ³Professor, ⁴Professor & HOD, ¹Dept. of Periodontics, ^{2,4}Dept. of Oral Medicine & Radiology, ³Dept. of Endodontics & Conservative, ^{1,2}Chandra Dental College & Hospital, Safedabad Barabanki, ^{3,4}Babu Banarasi Das College & Dental Sciences, Lucknow

***Corresponding Author:**

Email: neeta4lko@gmail.com

Abstract

Background: Successful periodontal regeneration is considered a gold standard for periodontists. Several GTR materials and bone grafts have been attempted but showed variable success rates.

Objective: The present randomized clinical and radiographic study was undertaken to compare the effectiveness of guided tissue regeneration (GTR) by using equine bioabsorbable collagen membrane with equine bone graft and bovine bioabsorbable collagen membrane with bovine bone graft and in the treatment of periodontal intrabony defects with grade II furcation involvement which are endodontically treated.

Materials and Methods: Ten systemically healthy patients with 20 periodontal intrabony defects were enrolled as a split mouth design. These defects were affected with grade II furcation involvement which are endodontically treated. The recorded measurements included plaque index, gingival bleeding index, gingival recession, PPD, clinical attachment level, radiographic defect depth and radiographic density. The defects were randomly distributed either as a control group (equine bioabsorbable collagen membrane combined with equine bone graft) or a test group (bovine bioabsorbable collagen membrane combined with bovine bone graft).

Results: At 12-month examination, PPD reduction was significantly greater in equine based GTR + bone graft group (3.80 ± 1.33 mm) compared with bovine based group (2.60 ± 1.57 mm), and clinical attachment level gain were 3.60 ± 1.15 and 2.20 ± 1.26 respectively. Radiographic DD reduction was similarly greater in equine GTR + bone graft group (3.30 ± 0.84 mm) compared with bovine based group (2.40 ± 1.09 mm). Also, the change in the radiographic density indicated a significant greater gain of mean gray level as (19.90 ± 16.00) in group 2 whereas 7.10 ± 10.65 in group 1.

Conclusion: Use of equine GTR bioresorbable membrane with bone graft showed significant improved outcomes when compared to use of bovine bioresorbable membrane with bone graft in treating grade II furcation defects. However, the studied groups showed significant improvement within each group when baseline & 12 month data were compared.

Keywords: Equine Bone Graft; Guided Tissue Regeneration; Intrabony Defect.

Introduction

The aim of successful periodontal therapy is a trial to arrest inflammatory process, suppress microbial growth, control infection and attempt to restore the tissues destroyed due to periodontal disease. Different regenerative techniques may be used for such purposes, but the treatment or elimination of the infection should be the most important goal especially in patients having intra bony defects.^(1,2)

The predictable complete periodontal regeneration remains a major goal in the planned therapy. Despite several procedures such as usage of guided tissue regeneration (GTR), grafting materials, growth factors and/or host modulating agents have been attempted, the outcomes are not always predictable.⁽³⁻⁶⁾ However, there is a great variation caused by many factors, for example; type of periodontitis, patient characteristics, anatomy of defect site and the surgical intervention.⁽⁷⁾

In general, the most successful documentation of periodontal regeneration is GTR since it acts as an effective principal therapy for the treatment of different

anatomic defects associated with periodontitis.⁽⁵⁾ Some earlier animal^(8,9) and human studies^(10,11) indicated a predictable reconstruction of the periodontium by using either non-bioabsorbable or bioabsorbable membranes.⁽¹²⁾ However, bioabsorbable GTR membranes were developed to avoid the second surgery needed to retrieve the non-resorbable barrier⁽¹³⁻¹⁶⁾ These bioabsorbable devices have two main products, natural (collagen membrane) and synthetic (copolymers) like Guidor, Vicryl periodontal mesh, Resolut and Atrisorb GTR barriers.

Use of GTR through the use of equine barrier and equine bone graft material showed a favorable clinical outcome and an effective periodontal therapy in the regenerative treatment of intrabony defects.⁽¹⁷⁾ Also, these equine collagen membranes and equine bone acts as an effective therapy for guided bone regeneration in the treatment of bone defect consequent to removal of periapical cyst in clinical & histological report.⁽¹⁸⁾

Some previous literature reports⁽¹³⁻¹⁶⁾ were found, in which the efficacy of bio-absorbable membranes

alone or combined with graft materials were evaluated and compared for regenerative purposes. However, to our knowledge, there are no available studies comparing the efficacy of using an equine bio-absorbable collagen barrier (Biocollagen®) alone or combined with equine graft (Bio-Gen®), in treating intrabony defects of chronic or aggressive periodontitis.

Subjects and Methods

Inclusion criteria

Aggressive or chronic periodontitis with grade II furcation involvement in mandibular first molars.

Intrabony periodontal defect sites with probing pocket depth > 5mm, as assessed by clinical and radiographic evaluation.

Radiographic evidence of vertical/angular bone loss.

Age ranged from 17 to 47 years.

Good general health.

Exclusion criteria

Periodontal treatment received during the last 6 months at least.

Hopeless teeth or evident grade-III mobile teeth.

Any relevant systemic diseases.

Smokers and/or alcoholics.

Pregnancy and/or lactation for female patients.

Hypersensitivity to any of the tested research materials.

Study Design: Ten patients (seven males & three females) were selected to be enrolled in this study and gathered from the out-patient clinic of the Department of, Periodontology Chandra Dental College and Hospital. Verbal and written informed consent forms were obtained from all subjects and an ethical clearance was also get from the institution.

Ten patients with bilateral intrabony periodontal defects were selected. Thus, a total of twenty affected sites were chosen as noticed primarily on the radiographs and confirmed clinically as well as within the reconstructive surgical intervention. These defects were distributed into two groups as follows:-

Group 1 (the control group): Ten sites received flap debridement followed by the application of the bioabsorbable collagen membrane of equine origin but combined with equine bone graft material as xenograft† (Bio-Gen®).

Group 2 (the test group): Ten sites received flap debridement followed by the application of the bioabsorbable collagen membrane of bovine origin but combined with bovine bone graft material as xenograft).

Primary Assessment and Patient's Preparation:

Patients were subjected to pre-surgical, clinical and radiographic interpretation. The patients completed a thorough plaque control regimen and a strict oral hygiene instruction. Full-mouth phase I therapy was done using periodontal Gracey curettes and an ultrasonic apparatus. The reevaluation period was determined according to each individual response, with an average period of about 6 weeks. Thereafter, a treatment plan was defined and an additional non-surgical therapy and/or dental extractions were done whenever needed. However, the surgical interventions were started when the subject's plaque and gingival index had achieved at least 20% levels, according to instructions of some previous reports.⁽¹⁹⁻²¹⁾

Clinical Measurements: Plaque index (PI), gingival bleeding index (BI), gingival recession (GR); probing pocket depth (PPD) and clinical attachment level (CAL) were recorded. An acrylic stent with reference points was used to localize the measurement sites at baseline and 18 months postoperatively. The periodontal measurements were recorded using a graduated William's periodontal probe. Tooth mobility was also graded,⁽²²⁾ scored and evaluated.

Surgical Procedures: Accesses to the defects were done using full-thickness flaps and sulcular incisions through the bottom of the crevice, extending mesial and distal to the adjacent teeth and including the flap papillae. No releasing incisions needed on either sides of the flap. Granulomatous tissues were curetted and thorough root planning was performed. EDTA with a concentration of 24%, at neutral pH, was used then washed with saline irrigation.

Randomly, one defect treated with equine bioabsorbable collagen membrane combined with equine bone graft as a control group whereas the other defect was treated with the collagen membrane of bovine origin & combined with bovine bone graft (the test group). Graft material was soaked with sterile saline and condensed gently in the defects to the adjacent crestal walls. The collagen membrane was adapted to obtain precise application to the interproximal area of the affected site. The membrane was then adjusted to completely cover the defect, overlapping at least 2-3 mm of the residual bone and sutured adequately with bioabsorbable sutures. Flaps were repositioned coronally during wound suturing, if required. The surgical site was covered with a non-eugenol periodontal dressing% on the buccal and lingual aspects.

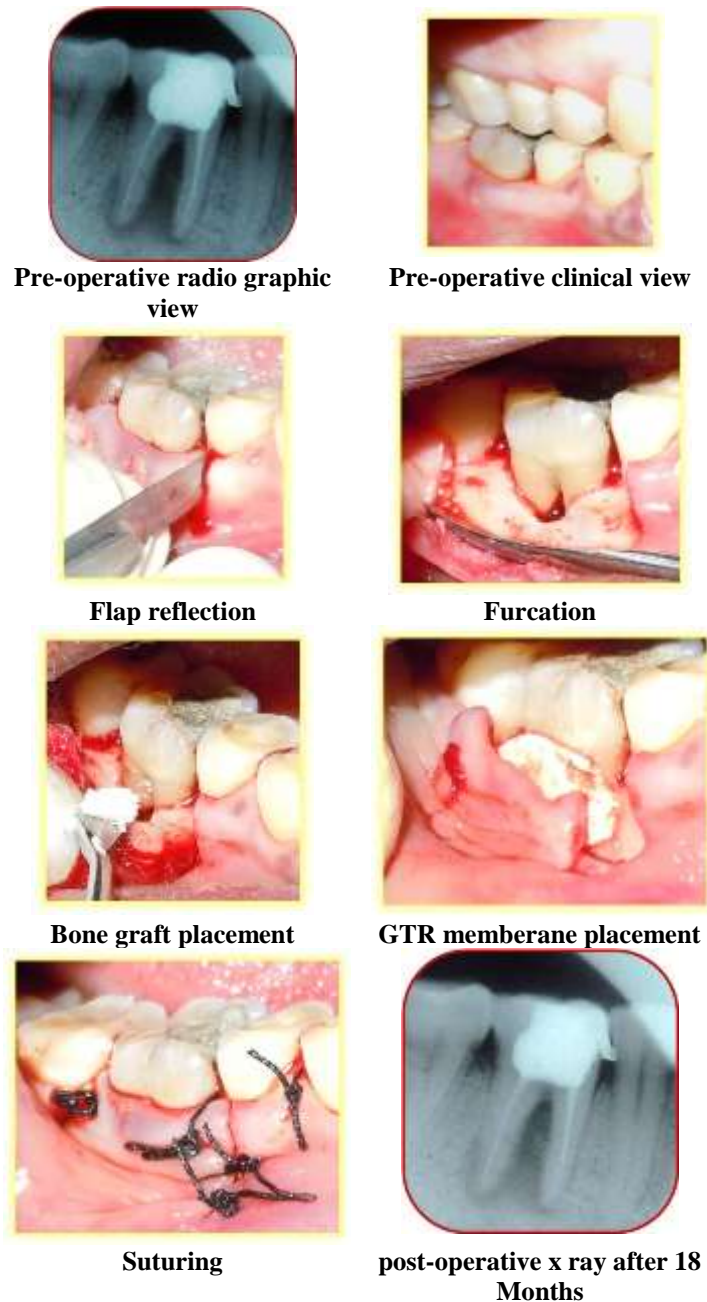
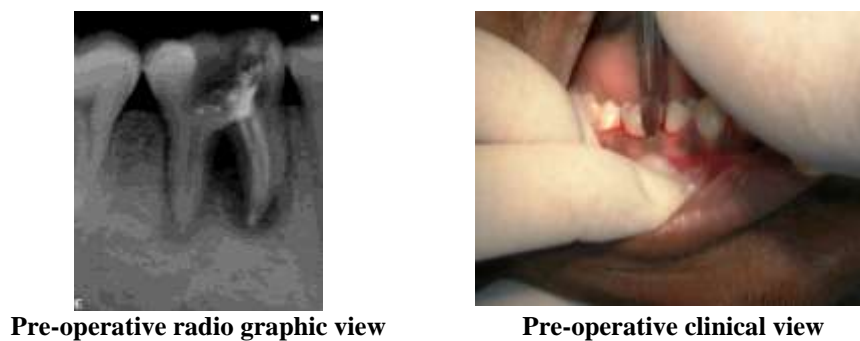


Fig. 1: Furcation treatment with equine bone graft & GTR



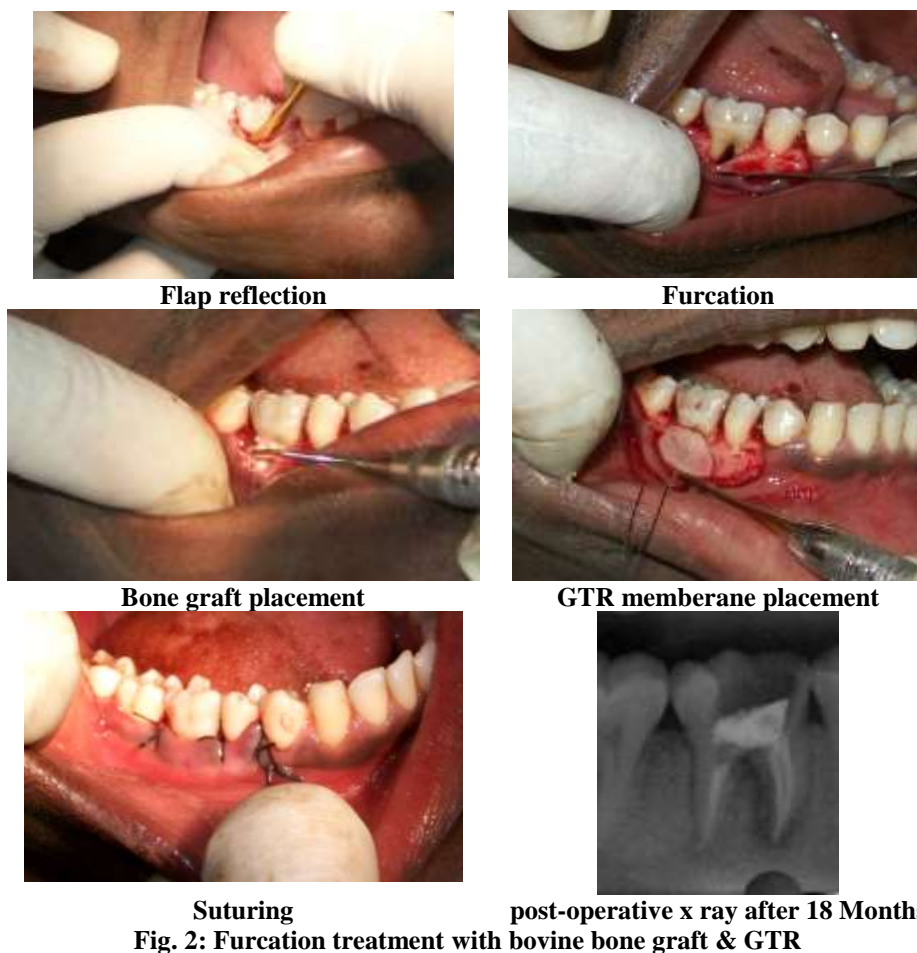


Fig. 2: Furcation treatment with bovine bone graft & GTR

Post-Operative Care: Chlorhexidine digluconate mouth rinse (0.12%) was used as two times daily for one month postoperatively. Amoxicillin trihydrate 375 mg/clavulanic acid as potassium salt 125 mg, was prescribed as two times daily for 10 days. Also, a non-steroidal anti-inflammatory drug (Ibuprofen 600 mg) was also prescribed twice per day, for 7 days.

Postoperative care was performed weekly in the first month, monthly up to six months and then every 3 months. In cases of membrane exposure, Doxycycline 100 mg was prescribed 2 times per one day then once for 5-7 days, and the surgical sites were carefully cleaned with a cotton swab soaked with 0.12% chlorhexidine digluconate two times daily.

Assessment of radiographic parameters and radiographic interpretation: Standardized intra-oral periapical radiographs (Kodak X-ray film, USA) were obtained at baseline and 12 months postoperatively. These radiographs were taken using long cone/extension cone paralleling technique with a positioning device mounted on a roentgen machine, operating at 70 Kilo Voltage Power.

Radiographs were scanned using a digital scanner at an input of 300 dpi and 100% scale, then they were

analyzed using a software@. The images had 768×512 pixels and 256 gray scale level. The alignment of images, in the pairs of radiographs, was applied to correct small geometric misalignments. Gray level was then calibrated to indicate changes in the radiographic density (RD).

In addition, the following measurements were obtained in millimeters: distance from cementoamel junction (CEJ) to base of the defect (BD) and from CEJ to alveolar crest (AC). The differences between baseline and 18-month postoperative values for CEJ-BD indicated the change in the radiographic defect depth (RDD), whereas the differences for CEJ-AC suggested the possible occurrence of crestal bone resorption (CBR).

Statistical Analysis: The present study had parametric variables. Thus, student's paired t-test was used to compare the changes in the data from baseline up to 18 months postoperatively within each treatment group. On the other hand, the intergroup comparison was accomplished by independent sample t-test. A 'P' value of 0.05 or less was considered statistically significant.

Results

Table 1: Comparison of clinical and radiographic parameters within and among study groups

Parameters	Groups	Group 1 (N=10)			Group 2 (N=10)			Students paired t test (Comparison within each group)				Independent sample t test (Comparison Between Experimental)	
		M	SD	SEM	M	SD	SEM	Group 1		Group 2		P Value	Sign.
								P Value	Sign.	P Value	Sign.		
PI	Base Line	1.20	.63	.20	1.20	.65	.21	.23	NS	.09	NS	1.00	NS
	18 Month	1.03	.36	.11	.93	.37	.12					.55	NS
BI	Base Line	1.23	.85	.27	1.20	.79	.25	.32	NS	.07	NS	.95	NS
	18 Month	1.10	.54	.17	.90	.43	.14					.37	NS
PPD	Base Line	7.80	1.75	.55	7.90	1.66	.53	.000	S	.000	S	0.90	NS
	18 Month	5.2	1.40	.44	4.1	.99	.31					.05	S
GR	Base Line	.80	.79	.25	.70	.82	.26	.04	S	.17	NS	.79	NS
	18 Month	1.20	.42	.13	.90	.74	.23					.28	NS
CAL	Base Line	8.6	1.26	.40	8.6	1.35	.43	.000	S	.000	S	.74	NS
	18 Month	6.4	1.26	.40	5.0	.94	.30					.01	S
RDD	Base Line	5.9	1.10	.35	5.9	.99	.31	.000	S	.000	S	1.00	NS
	18 Month	3.5	1.08	.34	2.6	.70	.22					.04	S
RD	Base Line	92.4	12.38	3.92	94.10	14.32	4.53	.000	S	.03	S	.78	NS
	18 Month	99.5	10.91	3.45	114	17.68	5.59					.04	S

Group1: treatment done by using bioabsorbable equine collagen membrane and equine bone graft. (control group)

Group 2: treatment done by using bioabsorbable bovine collagen membrane and bovine bone graft. (test group)

P Value: Statistically significant as ($P \leq 0.05$).

Sig: significance; NS: Statistically not significant; S: Statistically significant.

M: Mean; SD: Stand Deviation; SEM: Stand error mean.

PI: Plaque index; BI: Bleeding index; PPD: Probing pocket depth; GR: Gingival Recession; CAL: Clinical attachment level; RDD: Radiographic defect depth; RD: Radiographic Density.

Using student's paired t-test, the intra-group comparison showed comparable outcomes in the experimental groups regarding plaque index, gingival bleeding index as well as gingival recession, when comparing baseline scores to 12 months postoperative data. This is because there were no statistically significant differences noticed for these parameters, except only gingival recession within group 1 where P value recorded as 0.04. In addition, using independent sample t-test for intergroup comparison there were no statistically significant differences found between the two groups for these clinical parameters (PI, BI & GR). (Table 1). On the other hand, by using student's paired t-test, statistically significant differences were found when comparison was done from baseline up to 12 month postoperatively within both groups (1 & 2) regarding PPD, CAL, RDD & RD. Furthermore, using independent sample t-test for intergroup comparison there were also statistically significant differences found between the two groups for these clinical and radiographic parameters PPD.

The probing depth is reduced from (7.80±1.75 mm) at baseline to (5.20±1.40 mm) at 18 month with a mean difference of (2.60±1.57 mm) in group 1, whereas from (7.90±1.66 mm) to (4.10±.99 mm) with a mean difference of (3.80±1.33 mm) in group 2. This was statistically significant ($P = 0.000$). The intergroup comparison indicated that the difference was statistically significant with a P value of 0.05 (Table 1).

The clinical attachment level is changed from (8.60±1.26 mm) at baseline to (6.40±1.26 mm) at 18 month postoperative with a mean CAL gain of (2.20±1.26 mm) in group 1, whereas from (8.60±1.35 mm) to (5.00±.94 mm) with a mean CAL gain of (3.60±1.15 mm) in group 2. This was statistically significant ($P = 0.000$). The intergroup comparison indicated that the difference was statistically significant with a P value of 0.01 (Table 1).

The radiographic defect depth was reduced from (5.90±1.10 mm) at baseline to (3.50±1.08 mm) at 18 month postoperative with a mean difference of (2.40±1.09 mm) in group 1, whereas from (5.90±.99 mm) to (2.60±.70 mm) with a mean difference of (3.30±0.84 mm) in group 2. This was statistically significant ($P = 0.000$).

The radiographic density was changed from (92.40±12.38) at baseline to (99.50±10.91) at 18 month postoperative with a mean difference of (7.10±10.65) in group 1, whereas from (94.10±14.32) to (114±17.68) with a mean gain of (19.90±16.00) in group 2. This was statistically significant ($P = 0.000$ & 0.03 respectively). In addition, the intergroup comparison regarding both RDD and RD showed that the difference between the studied groups was statistically significant with a P value of 0.04 (Table 1).

Two cases are presented in figures with clinical photographs during surgical intervention and pre- & post-operative radiographic images. Case 1 is presented

in Fig. 1 and was treated by using bio absorbable equine collagen membrane with equine bone graft granules, for covering and treatment of selected intrabony defect site between teeth No. 36. Case 2 is presented in (Fig. 2) and was treated by the application of the same bio absorbable collagen membrane and graft granules of bovine origin xenograft material, for covering and treatment of selected intrabony defect site of teeth No.36.

Discussion

It has been established in the previous literature^(10,23) that the exclusion of epithelial and gingival connective tissue cells by using GTR barriers is important for periodontal wound healing, in order to achieve regeneration of the attachment apparatus. However, the non-restorable barriers have some disadvantages, such as higher cost, membrane exposure, need of a second intervention for their retrieval, complexity and bacterial accumulation.^(24,25) Several restorable barriers are therefore developed to decrease such drawbacks. These are preferable and widely used for guided tissue and/or bone regeneration.^(26,27)

Collagen membranes are selected frequently as restorable barriers, especially they possess some advantageous properties. These are a low toxicity due to a low immune response, the ability of collagen to reconstitute into the natural tissues and to enhance cell growth and attachment.^(28,29) In addition, collagen membranes are absorbed quickly to provide the needed integrity during regenerative process.

Bone grafts are used to treat different types of alveolar bone defects. They have a function to act with osteoconductive or osteoinductive properties. They can maintain a space and play an evident role by preventing membrane from collapse in the bone defect.^(30,31) They can also support the flap, facilitate the wound stability process and enhance the regenerative procedure.⁽³²⁾ Equine bone graft showed a favorable clinical and histological outcomes and an effective therapy for periodontal guided tissue and bone regeneration of intrabony defects, especially when combined with equine resorbable membranes.^(17,18)

Regeneration of periodontal defects is considered as a real challenge. Some earlier studies^(33-36,13) used different graft materials and barrier membranes, either alone or in combination, to achieve periodontal regeneration. However, the treatment outcome showed the combination therapy (GTR membrane + bone graft) as more effective than using GTR membrane or graft alone. Most of these studies showed a combination of GTR membrane with either allograft (DFDBA), xenograft (Bio-Oss), hydroxyapatite, or enamel matrix proteins. However, in recent years, some evidence^(17,18) suggested that equine bone graft and equine membrane are also capable of supporting the periodontal regenerative healing capacity. The present study was

therefore planned to evaluate and compare the efficacy of using equine bio absorbable barrier with equine bone graft granules over bovine absorbable barrier with bovine bone graft granules, in treating intrabony defects of chronic or aggressive periodontitis.

It has been noticed that the clinical measurements have a critical role in evaluating regenerative process since they can provide reliable information regarding probing depth reduction and clinical attachment level gain. The studied groups of the present study showed significant improvement of PPD & CAL parameters when comparing baseline with 12 month post-operative data (Table 1), thus signifying the significant improvement of the combined therapy in of equine over bovine. In this context, some studies^(14,40) suggested that treatment of periodontal intrabony defects with graft materials lead to significantly greater gain in clinical attachment level and better defect fill, by promoting osteogenesis and allowing rapid and quick formation of new bone. Also, it appears that the graft material has a critical role in preventing collapse of the membrane and/or flap during initial healing periods, thus can potentiate regeneration.⁽³²⁾

Regarding the positive findings obtained in the present study and as a significant point of view, it has been noticed that the ten involved cases were selected carefully with a complete patient desire to treat the affected defects, to strictly follow instructions to maintain oral hygiene and to attend needed follow up visits in due times with almost a complete compliance. The subjects had comparable bilateral intrabony defects. Mobility did not has any worsening in their grades throughout the whole study interval. Regarding pocket depth reduction, the number of defects that showed a successful resolution were four in Group 1 (equine group) and seven in group 2 (bovine group), whereas the remaining defects (six in group 1 and three in group 2) still had a severe probing periodontal pocket depths. These remaining defects ranged in their depths from 5 to 8 mm in group 1 but from 5 to 6 mm in group 2. Regarding radiographic defect depth resolution and radiographic density gain, group 2 showed favored significant results, but no defects showed complete fill radiographically.

Conclusion

In final conclusion, although the present split-mouth clinical study had some given constraints, the combined therapy of using graft material (equine bone, Bio-Gen®) with GTR bio absorbable membrane (equine collagen, Biocollagen®) showed enhanced and significant clinical outcomes (PPD & CAL) over using bovine materials. Also, the radiographic assessment that evaluated defect fill (RDD) and bone density (RD) showed significantly greater results of the equine combined therapy. However, the studied groups showed significant improvement of these parameters when

comparing baseline data with results of 12 month postoperatively within each group.

References

- Oly JC, Palioto DB, de Lima AF, Mota LF, Caffesse R (2002) Clinical and radiographic evaluation of periodontal intrabony defects treated with guided tissue regeneration. A pilot study. *J Periodontol* 73(4):353-359.
- Zucchelli G, Bernardi F, Montebugnoli L, De SM (2002) Enamel matrix proteins and guided tissue regeneration with titanium-reinforced expanded polytetrafluoroethylene membranes in the treatment of infrabony defects: a comparative controlled clinical trial. *J Periodontol* 73(1):3-12.
- Int. Rapp GE, Pineda Trujillo N, McQuillin A, Tonetti M (2010) Genetic power of a Brazilian three-generation family with generalized aggressive periodontitis. *Braz Dent J* 21:137-141.
- Murphy KG, Gunsolley JC (2003) Guided tissue regeneration for the treatment of periodontal intrabony and furcation defects. A systematic review. *Ann Periodontol* 8(1):266-302.
- Wang HL, Cooke J (2005) periodontal regeneration techniques for treatment of periodontal diseases. *Dent Clin North Am* 49(3):637-659.
- Bottino MC, Thomas V, Schmidt G, Vohra YK, Chu TM, et al. (2012) Recent advances in the development of GTR/GBR membranes for periodontal regeneration – a materials perspective. *Dent Mater* 28(7):703-721.
- Ribeiro FV, Nociti FH, Sallum EA, Sallum AW, Casati MZ (2010) Use of enamel matrix protein derivative with minimally invasive surgical approach in intra-bony periodontal defects: clinical and patient-centered outcomes. *Braz Dent J* 21(1):60-67.
- Nyman S, Gottlow J, Karring T, Lindhe J (1982) the regeneration potential of the periodontal ligament. An experimental studies in monkeys. *J Clin Periodontol* 9(3):257-265.
- Aukhil I, Pettersson E, Suggs C (1986) Guided tissue regeneration. An experimental procedure in beagle dogs. *J Periodontol* 57(12):727-734.
- Nyman S, Lindhe J, Karring T, Rylander H (1982) New attachment following surgical treatment of human periodontal disease. *J Clin Periodontol* 9(4):290-296.
- Gottlow J, Nyman S, Lindhe J, Karring T, Wennstrom J (1986) New attachment in human periodontium by guided tissue regeneration. *J Clin Periodontol* 13(6):604-616.
- Nygaard ostby P, Bakke V, Nesdal O, Susin C, Wikesjo UM (2010) Periodontal healing following reconstructive surgery effect of guided tissue regeneration using a bioresorbable barrier device when combined with autogenous bone grafting: A randomized controlled trial. 10 year follow-up. *J Clin Periodontol* 37(4):366-373.
- Becker W, Becker BE, Mellonig J, Caffesse RG, Warrer K, et al. (1996) A prospective multi-center study evaluating periodontal regeneration for Class II furcation invasions and intrabony defects after treatment with a bioabsorbable barrier membrane: 1 year results. *J Periodontol* 67(7):641-649.
- Mengel R, Soffner M, Flores de Jacoby L (2003) Bioabsorbable membrane and bioactive glass in the treatment of intrabony defects in patients with generalized aggressive periodontitis – Results of a 12 month clinical and radiological study. *J Periodontol* 74(6):899-908.
- Gaffaney TE (2004) Guided tissue regeneration using a bioabsorbable membrane: A 21 – case series. *J Periodontol* 75(12):1728-1733.
- Pretzl B, Kim TS, Steinbrenner H, Dorfer C, Himmer K, et al. (2009) Guided tissue regeneration with bioabsorbable barriers. III 10 years results in infrabony defects. *J Clin Periodontol* 36(4):349-356.
- Dogan GE, Demir T, Orbak R (2014) Effect of low-level laser on guided tissue regeneration performed with equine bone and membrane in the treatment of intrabony defects: a clinical study. *Photomed Laser Surg* 32(4):226-231.
- Di Stefano DA, Andreasi Bassi M, Cinci L, Pieri L, Ammirabile G (2012) Treatment of a bone defect consequent to the removal of a periapical cyst with equine bone and equine membranes: clinical and histological outcome. *Minerva Stomatol* 61(11-12):477-490.
- Loe H & Silness J (1963) periodontal disease in pregnancy (I) prevalence and severity. *Acta Odontol Scand* 21:533-551.
- Loe H (1967) the gingival index, the plaque index and the retention index systems. *J Periodontol* 38(6) Suppl: 610-616.
- O Leary TJ, Drake RB, Naylor JE (1972) the plaque control record. *J Periodontol* 43(1):38.
- Lindhe J (1983) Reattachment-new attachment. Text book of Clin Periodontol (2nd edn) Munksgaard, Copenhagen, Europe pp. 410.
- Stahl SS, Froum S, Tarnow D (1990) Human histologic responses to guided tissue regenerative techniques in intrabony lesions. Case reports on 9 sites. *J Clin Periodontol* 17(3):191-198.
- Cortellini P, Pini Prato G, Tonetti MS (1996) periodontal regeneration of human intrabony defects with bioresorbable membranes. A controlled clinical trial. *J Periodontol* 67(3):217-23.
- Wang HL, Yuan K, Burgett F, Shyr Y, Syed S (1994) Adherence of oral microorganisms to guided tissue membranes: an in vitro study. *J Periodontol* 65(3):211-215.