

Idiopathic Root Resorption with Generalized Aggressive Periodontitis: A Case Report

Purnita Goyal^{1,*}, Bansal Rajat²

^{1,2}Reader, ¹Dept. of Pedodontics, ²Dept. of Periodontics, Kothiwal Dental College & Research Centre, Moradabad, Uttar Pradesh, India

***Corresponding Author:**

Email: dr.purnitagoyal@gmail.com

Abstract

An 17 year old girl visited in our Department of Pedodontics with chief complaint of multiple loose teeth. On examination, there was generalized inflamed gingivae, deep periodontal pocket and severe mobility in incisors and molars. The family history revealed that her mother and her maternal uncle had lost all the teeth by the age of 30 years.

Radiographs showed almost generalized apical root resorption of different severity with marked horizontal and vertical bone loss. No local cause for root resorption was found. Laboratory analyses like serum calcium and alkaline phosphatase, thyroid and parathyroid function tests were performed to correlate with any systemic factor but were negative.

Neither local nor systemic etiological factor was found, so case was diagnosed as Idiopathic Root Resorption with Generalized Aggressive Periodontitis and managed.

Keywords: Idiopathic, Multiple Resorption, Root Resorption, Aggressive Periodontitis.

Introduction

Root resorption of permanent teeth was first described by Bates (1856),⁽¹⁾ who considered trauma to the periodontal membrane as the main cause. Root resorption is classified as external and internal, the former being reported more often. Cohen & Burns 2007.⁽²⁾

It is a rare condition, reported in a single tooth and/or multiple teeth. First reported by Mueller & Rony in 1930.⁽³⁾ This exists without a known etiology. There are two types of resorption: apical and cervical (Yusof & Ghazali 1989).⁽⁴⁾ In apical form- the resorption starts at apex, progresses coronally, there is a gradual shortening and rounding of the roots. In cervical form resorption starts in the cervical region from lateral aspect and approaches the pulp (Postlethwaite & Hamilton 1989, Rivera & Walton 1994).⁽⁵⁾

External resorption result from the activity of multinucleated clastic cells in the periodontal ligament. As regard bone, under normal conditions there is a dynamic balance between osteoclastic and osteoblastic activities. A imbalance may result in external root resorption.

Various causes of external root resorption are: Trauma, Inflammation, Tumors, Cysts, Occlusal stress, Orthodontic movement, Periodontitis (Rodriguez-Pato 2004),⁽⁶⁾ Hyperparathyroidism (Goultchin et al. 1982),⁽⁷⁾ Hypoparathyroidism (Sunde & Hals 1961),⁽⁸⁾ Hypophosphatemia, Hyperphosphatemia (Eyring & Eisenberg 1968),⁽⁹⁾ Paget's disease of bone (Smith 1978),⁽¹⁰⁾ Papillon-Lefevre Syndrome (Rudiger & Berglundh 1999).⁽¹¹⁾

No association has been found with aggressive periodontitis in the presently available literature. Aggressive periodontitis generally affects otherwise

systemically healthy individuals, less than 30 years of age, although patients may be older (AAP 1999).

This case report depicts a female with multiple idiopathic apical root resorption with generalized aggressive periodontitis.

Case Report

A female patient aged 17 years, referred to Department of Pedodontics, Kothiwal Dental College and Research Centre Moradabad with complaint of generalized mobility of the teeth since last one year. History of present illness depicts initially, there was frequent but transient bleeding from gums while brushing and slight mobility in her front teeth which became generalized after some time. Past medical, dental, and personal history was unremarkable. Family history was significant which revealed that her mother and maternal uncle had lost their teeth by the age of 30 years. Now they are wearing complete dentures.

On oral examination 11, 12, 16, 36 were missing. There was generalized gingival recession. Gingiva was inflamed, soft, edematous and fiery red in color, generalized bleeding on probing with evidence of supragingival calculus. There was generalized pocket present of more than 5mm in most of the teeth. Mobility was generalized with Grade III in 21 & 26, Grade II in lower anteriors, and Grade I in remaining teeth.

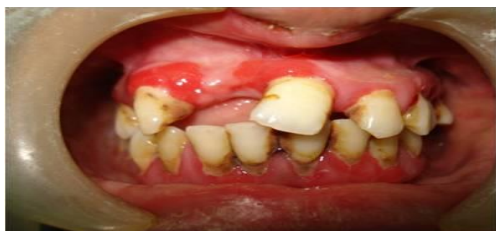

Fig 1: preoperative photograph

Panoramic radiographic (OPG) revealed evidence of generalized apical root resorption, which was more severe in maxillary teeth as compared to mandibular teeth. In lower anteriors, there was very less or no resorption. Radiograph also shows both horizontal as well as vertical bone loss.

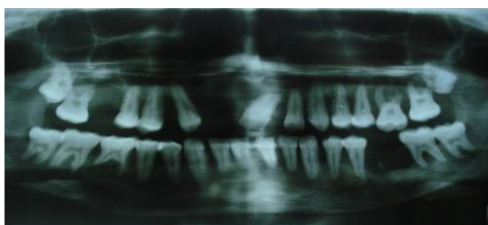


Fig. 2: Preoperative OPG

Hematological and biochemical screening such as T.L.C., D.L.C, Blood sugar, Serum calcium, Serum alkaline phosphatase, Thyroid and parathyroid function test all were within normal range.

From the history, clinical, radiographic and hematological examination a diagnosis of Idiopathic Root Resorption with Generalized Aggressive Periodontitis was made.

Extraction of Grade III mobile # 21, 26 was done. Extracted teeth clearly showed apical root resorption. Oral hygiene instructions, Scaling and root planing, Curettage, Splinting of lower anteriors with light cure composite resin, Doxycycline for two weeks was given. Prosthesis was given for maxillary anterior teeth.

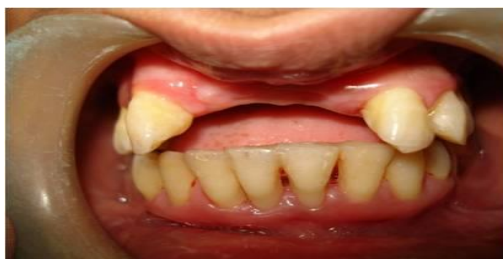

Fig. 3: Postoperative after 1 week

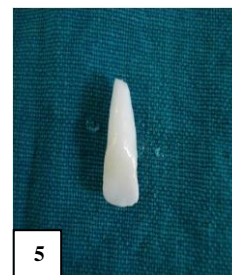
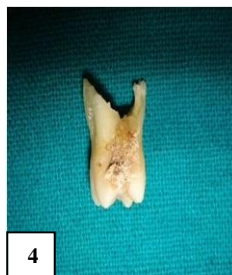

Fig. 4 & 5: Resorbed roots of extracted teeth

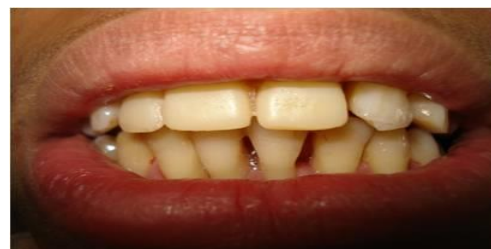

Fig. 6: Removable Prosthesis Placed

Patient was evaluated after 8 months post operative. Gingiva was inflamed under the prosthesis because of uncleanliness, but there was reduction in pocket depth, no further loss of attachment and OPG revealed no further root resorption.

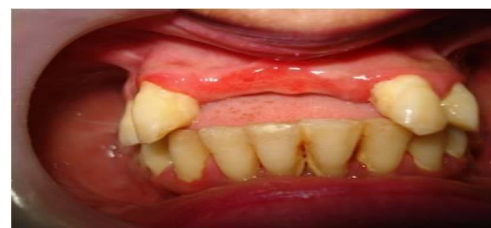

Fig. 7: Postoperative after 8 months of treatment

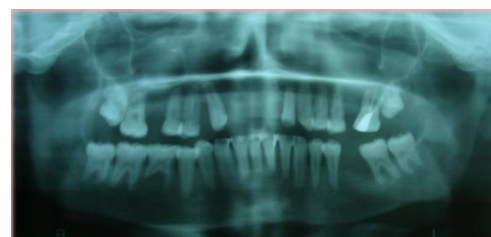


Fig. 8: Postoperative OPG no further bone loss seen

Discussion

This case is a rare example of idiopathic apical root resorption, almost generalized in nature. Only few cases have been reported since 1970.

In the present case the mandibular anterior teeth apices were not clearly involved, and this is similar to previously illustrated cases. This might be due to less blood supply to the anterior segment of the mandible which provides less odontoclastic components as compared to maxilla (Moazami and Karami 2007). Idiopathic apical root resorption does not seem to be mediated from the pulp space. It is suspected that some

triggering factors might exist for root resorption (Rivera & Walton 1994).⁽⁵⁾

Periodontal ligament cells are found to produce paracrine factors that inhibit mineralized tissue resorption and capable of regulating bone and cementum formation (Beertsen et al. 1997, McCulloch et al. 2000).^(12,13) Schatzle et al. (2005) suggested that root resorption might occur due to disturbance in the regulation of mineralization within the periodontal ligament. Since root resorption is not mediated from within the pulp space, so interceptive endodontic procedures are not indicated (Moazami & Karami 2007).

Aggressive Periodontitis (AP) was redefined (AAP 1999) as “a complex entity of microbial alterations and cellular dysfunctions that differentiate the underlying molecular mechanisms from chronic periodontal disease”. *Aggregatibacter. actinomycetemcomitans* is regarded as the key etiological agent. Once AP has been diagnosed, a comprehensive periodontal treatment plan must be developed.

Conclusion

This has been chosen as case report due to the rare anomaly. Such defects will complicate the periodontal diseases. The present case with: Age - 2nd decade of life, Rapid progression of disease, No correlating etiology for root resorption; and Sparing of mandibular anterior teeth for root resorption are suggestive of “Idiopathic Root Resorption with Generalized Aggressive Periodontitis”.

Future consideration: Although some potential factors (dietary habits and changes in the oral flora) have been suggested for idiopathic root resorption, many have yet to be discovered. It seems that there might be some correlation existing between apical root resorption and aggressive periodontitis. Since there is no known preventive or therapeutic regimen for this condition at the moment, so further studies are needed to identify the underlying mechanism. It is hoped that the discovery of the molecular and cellular mechanism for root resorption will yield new methods for treatment.

References

1. Bates S. Absorption. *Br J Dent Science*. 1856;1
2. Cohen & Burns 2002. pathways of the pulp. 8th edition
3. Mueller & Rony 1930. Laboratory studies of an unusual case of reorption. *JADA* 11,2.326-334
4. Yusof & Ghazali 1989. Multiple external root resorption. *Journal of American Dental Association*. 118, 453-455
5. Rivera & Walton 1994. Extensive idiopathic apical root resorption. A case report. *OOO Nov*;78(5):673-677.
6. Rodriguez-Pato 2004. Root resorption in chronic periodontitis; a morphometrical study. *Journal of Periodontology* 75, 1027-32
7. Goultschin et al. 1982. Root resorption. *Oral surgery*,

- Oral Medicine & Oral Pathology 54, 586-90
8. Sunde & Hals 1961. Dental changes in a patient with hypoparathyroidism. *British Dental Journal* 111, 112-117. Abstract
9. Eyring & Eisenberg 1968). Congenital hyperphosphatasia: a clinical, pathological and biochemical study of 2 cases. *Journal of Bone and Joint Surgery*. (Abstract)
10. Smith 1978. Monostotic Paget’s disease of mandible presenting with progressive resorption of the teeth. *Oral surgery, Oral Medicine & Oral Pathology* 46. 246-53 (abstract).
11. Rudiger & Berglundh 1999. Root resorption and signs of repair in Papillon-Lefevre syndrome. A case study. *Acta Odontol Scand Aug*;57(4):221-4
12. Beertsen et al. 1997. The periodontal ligament: a unique multifunctional connective tissue. *Periodontology* 2000 13, 20-40.
13. McCulloch et al. 2000. Role of physical forces in regulating the form and function of periodontal ligament. *Periodontology* 2000 24. 56-72.