

Peizosurgery: From basics to its application in implantology

Gayathri Muralidaran^{1,*}, Nagarathna D.V.², NarasimhaRao Bharadwaz³

¹Senior Lecturer, ²Profossor, ³Post Graduate, ^{1,2}Dept. of Periodontics, ³Dept. of Pathology, ¹Mamta Dental College, Telangana, ²A. J. Dental College, Mangaluru, Karnataka, ³Mamta Medical College, Telangana

***Corresponding Author:**

Email: drgayathri19@gmail.com

Abstract

Recent era has witnessed diverse changes in treatment options. Peizosurgery is one among them which has made the clinicians practice easier. Peizosurgery was first developed by Italian physician Tomaso Vercellotti. Since it's invent it has been used in various fields including periodontology especially in the field of implants. It is based on principle of ultrasound. Peizosurgery has been tried in various surgical procedures including implant site preparation, bone harvesting, ridge split, sinus lift etc. Though the major disadvantage is expensive and technique sensitive. Yet, further research has to be conducted to evaluate its efficacy in periodontology and implant dentistry.

Keywords: Effects, Peizosurgery, Unit, Working principle.

Introduction

Past two decades in dentistry have made headway towards a newer mechanization, which brought different modalities in treatment. Traditionally, osseous surgery has been performed either by manual or motor-driven instruments. Manual instruments offer good control when used to remove small amounts of bone in areas with relatively less dense mineralization. However, manual instruments are difficult to control in manipulating bone, particularly where precise osteotomies are essential. Motor-driven instruments transform electric or pneumatic energy into mechanical cutting action using the sharpened edge of burs or saw blades. These instruments generate significant amount of heat in the cutting zone that must be minimized by water irrigation. Motorized cutting tools also decrease tactile sensitivity.⁽¹⁾ In the last decade, a novel family of ultrasonic devices has been created to dissect hard tissue in various maxillofacial surgical operations. This surgical technique is known as Piezosurgery and uses an adapted ultrasonic transducer and generator that are capable of driving a range of cutting inserts.⁽²⁾ The concept of Piezosurgery was founded by Italian physician Tomaso Vercellotti (Fig. 1). Vercellotti teamed up with Mectron Medical Technology, a company founded by Italian engineers Fernando Bianchetti and Domenico Vercellotti dedicated to producing medical devices.⁽³⁾



Fig. 1: Dr. Tomaso Vercellotti

Principle: Pierre Curie discovered piezoelectricity in 1881 which gave the basis of piezosurgery.⁽⁴⁾ The piezoelectric effect is the creation of electrical tension on some crystal such as quarts, Rochelle salt and ceramic materials to which a mechanical pressure is subsequently applied. The material in question will expand and then contract leading to an ultrasonic vibration. Also known as 'pressure electrification', it has been defined by the term 'piezo' derived from 'piezein', meaning pressure in Greek language. The piezosurgery device is essentially an ultrasound machine with modulated frequency and a controlled tip vibration range. The ultrasonic frequency is modulated from 10, 30 and 60 cycles/s (Hz) to 29 KHz. The low frequency enables cutting of mineralized structures, not soft tissues. Power can be adjusted from 2.8 to 16 W, with preset power settings for various type of bone density. The piezosurgery tip vibrates within a range of 60-200mm, which allows clean cutting with precise incisions.⁽⁵⁾

Due to the deformation caused by the electrical current, a cutting – hammering movement is produced at the tip of the instrument. These micro movements are in the frequency range of 25 to 29 kHz and, depending on the insert, with amplitude of 60 to 210 μm. This way only mineralized tissue is selectively cut. Neurovascular tissue and other soft tissue would only be cut by a frequency of above 50 kHz.⁽⁶⁾

Effects of peizosurgery on the tissues:⁽⁷⁾

Peizosurgery effects are similar to ultrasound:

- 1. Thermal Effects:** As a wave of ultrasound passes through tissues its energy is reduced and is dissipated as heat, leading to an elevation of tissue temperature.
- 2. Cavitation:** Cavitation activity is a continuous spectrum of bubble activity in a liquid medium. The energy generated within these bubbles may

result in shock waves or hydrodynamic shear fields which may disrupt biological tissues. Cavitation can result in a thrombogenic effect and cause lysis of erythrocytes and platelets thus there is reduction in hemorrhage (Fig. 2).

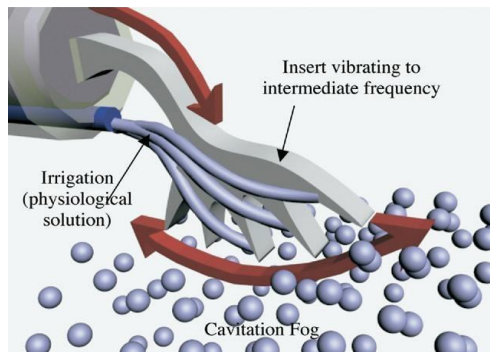


Fig. 2: Cavitation effect

- Acoustic Microstreaming:** The rapid cyclical volume pulsation of a gas bubble results in the formation of a complex steady state streaming pattern within the liquid close to the bubble surface. The gradients due to the rate of change of velocity will produce large hydrodynamic shear stresses close to the oscillating object (i.e., probe or gas bubble) which may disrupt or damage biological cells or tissues (Fig. 3).




Fig. 3: A theoretical prediction of acoustic microstreaming field generated around a solid cylinder oscillating within a stationary fluid

- Chemical Effects (Sonochemicals):** When ultrasonic cavitation (similar to ionizing radiation) acts on aqueous solutions of certain compounds, including dissolved air, oxygen, and nitrogen, free radicals produced due to water molecules decomposition reacts with these compounds or gases.
- Radiation Forces:** Any medium or object in the path of an ultrasonic beam is subjected to a radiation force, which tends to push the material in the direction of the propagating wave.

Basic piezoelectric model^(8,9,10)

Piezoelectric devices typically consist of a handheld device (handpiece), a base unit and a foot pedal. There

are different-shaped inserts that correspond to different applications that can be screwed into the handpiece.

Parts

Unit: The unit consists of handpiece, foot switch, ultrasound, control, dynamometric wench and peristaltic pump (Fig: 4)

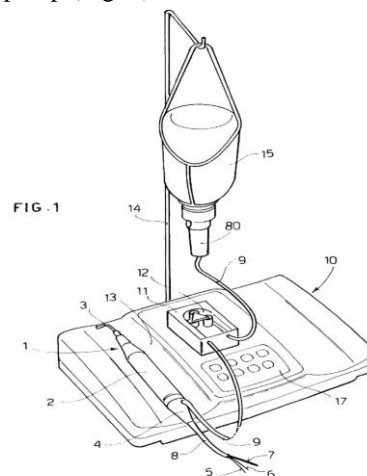


Fig. 4: Axonometric view of surgical device

1 shows Handpiece comprising a body , 2 shows Cylindrical in shape for easy grip, 3 shows Tip of suitable shape, 4 shows External connector, 5 shows Electrical supply cable, 6 shows Electrical supply cable, 7 shows First hydraulic supply tube, 8 shows Sheath around first hydraulic supply, 9 shows Second hydraulic supply, 10 shows Console that takes the electrical supply from mains, 11 shows Peristaltic pump connected to second hydraulic supply, 12 shows Rotor which controls the speed of rotation, 13 shows Housing in which handpiece is positioned, 14 shows Supporting rod for the container, 15 shows Bottle or bag containing sterile fluid, 80 shows Outlet, 17 shows Control keyboard.

Operation of the device: As based on the illustration (Fig. 5) the device can be operated as follows:

The electrical supply taken from the electrical supply mains 21 is sent to a power supply 22 provided inside the console 10. The power supply 22 provides electrical power to the microprocessor unit 20, to a power stage 23 and to a control unit 24 of the peristaltic pump 11.

The power stage 23 is able to generate an adequate output current and voltage signal to supply the handpiece 1. The control unit 24 of the peristaltic pump 11 gives out a control signal to operate the rotor 12 of the peristaltic pump 11 so as to feed the sterile fluid from the container 15 toward the handpiece 1. The keyboard 17 generates control signals S1 toward the input of the microprocessor unit 20. The microprocessor unit 20, on the basis of the control signals S1 received, sends out output control signals S2

and S3 respectively toward the power stage 23 and the control unit 24 of the peristaltic pump 11. The power stage 23, on the basis of the control signal S2 received, sends the electrical supply to the handpiece 1. The control unit 24 of the peristaltic pump 11, on the basis of the control signal S3 received, regulates the speed of the rotor 12 of the peristaltic pump 11.

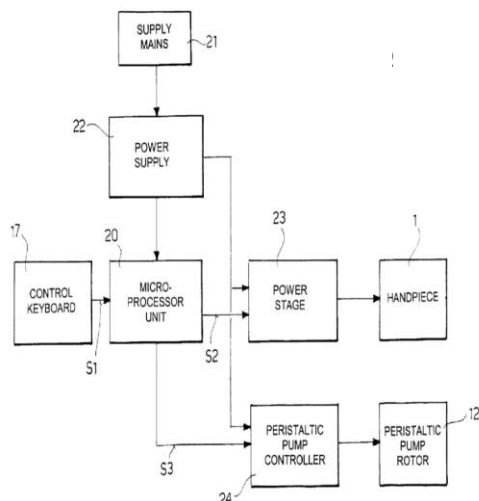
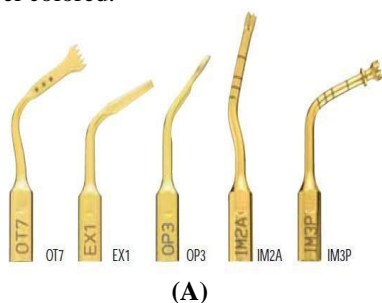


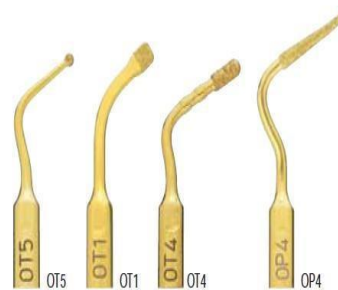
Fig. 5: Block diagram illustrating operation of the surgical device according to the invention

The Insert Kits

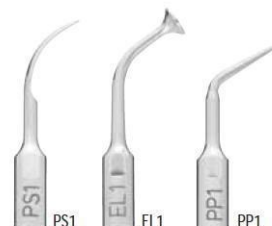Kit containing the insert tip can be used for various procedures. The tips have been classified as sharp, smoothing and blunt tips (Fig. 6). The tips are either gold or steel colored.



(A)



(B)



(C)

Fig. 6: A- Sharp insert tips; B- Smooth insert tips; C- Blunt insert tips

Clinical classification of insert tips:

OT: The identification code for inserts used to perform osteotomy is OT followed by number.

OP: The identification code for inserts used to perform osteoplasty is OP followed by number.

EX: The identification code for inserts used to perform extraction EX followed by number.

IM: The identification code for inserts used to perform implant site preparation IM followed by number.

The periodontal surgeries like sinus lift (crestal and lateral approach), Implant site preparation, mini implant placement, ridge expansion, bone block grafting, bone chip grafting, osteotomy close to nerves, corticotomy technique and various other periodontal surgeries are performed with various insert tips (Table1).⁽¹¹⁾

Table 1: Insert tips according to their indications

Indication	Standard tips	Optional tips
Sinus lift technique-crestal approach	IM1SP, IM2P, OT9, CS1, PIN IM1, PIN 2-2.4	
Sinus lift technique- Lateral approach	OP3, OT1, EL1	OT1A, OT5, OT5A, OT5B, EL2, EL3
Implant site preparation	IM1S, IM2A, IM3A, IM4A, IM2P, IM3P, IM4P, OT4, P2-3, P3-4	IM1AL, IM2A-15, IM3A-15, IM2P-15, IM3P-15, PINS
Mini dental implant site preparation	IM1S, MDI1.9, MDI2.2, MDI2.5	
Ridge expansion	OT7, OT4, OP5	OT2, OT7A, OT7S-4, OT7S-3, OT7-20
Block bone grafting	OT7, OP5, OT8R, OT8L	OT6, OT7A, OT7S-4, OT7S-3, OT7-20

Bone chip grafting	OP3, OP1	OP2, OP3A
Osteotomy close to nerves	OT1, OT5	OT9
Corticotomy technique	OT2, OT7, OT7A, OT7S-4, OT7S-3, OT7-20	
Other periodontal surgeries	PS2, OP5, OP3, PP1	PS1, PS6, PP10, PP11, PP12, OP2, OP3A, OP4, OP6, OP6A, ICP+IC1

Power levels:⁽³⁾

Low mode: Indicated for apical endocanal cleaning in orthodontic surgery;

High mode: Useful for cleaning and smoothing the radicular surface;

Boosted mode: Indicated in bone surgery, necessary in performing osteotomy and osteoplasty.

Cutting characteristic of a device: The cutting characteristics of piezosurgery are dependent upon degree of bone mineralization (density), design of the insert, pressure applied on handpiece during use and speed of movements during use. The frequency of ultrasonic vibrations (Hz), the level of power (W) and the water spray are three adjustable settings that should be set in accordance with the intended procedure.⁽⁸⁾

Biological effect of the device:^(12,13,14)

1. Provide favourable osseous repair and remodeling.
2. Earlier increase in BMP-4 and TGF-β2 proteins as well as a reduction in proinflammatory cytokines.
3. Smallest increase in intraosseous temperature.

Indications:⁽⁸⁾

1. Implantology
 - a. Implant socket preparation
 - b. Alveolar ridge splitting and expansion
 - c. Re-contouring of alveolar crest
 - d. Mental nerve reposition
 - e. Distraction osteogenesis followed by implant placement
 - f. For retrieval of blade implants
 - g. For insertion of implant
 - h. For harvesting block grafts
2. Maxillary sinus bone grafting surgery
 - a. Preparation of bone window with lateral approach
 - b. Atraumatic dissection of sinus mucosa
 - c. Internal sinus floor elevation
3. Periodontal treatment procedures:
 - a. Supragingival and subgingival scaling and root planning
 - b. Periodontal pocket lavage
 - c. Crown lengthening
 - d. Soft tissue debridement
 - e. Resective and regenerative surgeries

Contra indications:⁽¹⁰⁾

1. Electrical implants such as pacemakers, in either patient or the clinician.
2. Certain systemic diseases such as cardiovascular diseases, diabetes and bone disease or in patients undergoing radiotherapy, all of which can hinder the dental implant surgery.
3. Alterations that may or may not be related to systemic diseases, bone structure and vascularization. Verifying the bone structure and the healthy vascular condition of the patient are fundamental elements for good integration and healing.
4. Behaviors such as smoking and excessive drinking.

Advantages:^(15,16)

1. Precise cutting and safety.
2. Selective cutting and minimal operative invasion.
3. Greater control of surgical device.
4. Bleeding-free surgery site.
5. Faster bone regeneration and healing process.
6. No risk of emphysema.
7. Decrease post-operative pain.
8. Reduced traumatic stress.
9. Ease of use.
10. No overheating.
11. Effective cutting and cleaner.

Disadvantage:⁽¹⁷⁾

1. Dense bone cutting can take four times longer than with rotary.
2. Expensive
3. Technique sensitive.
4. Frequent tip breakage.

Application in Implantology:

1. **Implant site preparation:** In vitro study was done to evaluate the intraosseous temperature changes during ultrasonic and conventional implant site preparation with respect to the effect of load and irrigation volume. Ultrasonic implant site preparation is more time consuming and generates higher bone temperatures than conventional drilling. However, with the levels of irrigation, ultrasonic implant site preparation can be an equally safe method.⁽¹⁸⁾
2. **Immediate implant placement:** Atraumatic tooth extraction and subsequent implant site preparation. Extraction consisted of cutting the fibers of the

periodontal ligament with vibrating tips of up to 10 mm in depth; the teeth or roots were mobilized afterward with an elevator. Hence obtained a successfully loaded osseointegrated implants for 12 months.⁽¹⁹⁾

3. Periimplant bone density: Evaluation of peri-implant bone density, between implant insertion using traditional surgical technique and piezoelectric technique. Results of this pilot study demonstrated that (1) piezoelectric implant site preparation promotes better bone density and osteogenesis, and (2) the piezoelectric technique is predictable, with a 100% success rate in this study.⁽²⁰⁾

4. Micromorphological changes: Study comparing material attrition and micromorphological changes after ultrasonic and conventional implant site preparations was conducted. In conventional osteotomy, partially destroyed trabecular structures of the cancellous bone that were loaded with debris were observed, whereas after ultrasonic implant site preparations, the anatomic structures were preserved. So, it was concluded ultrasonic implant site preparation is associated with the preservation of bone microarchitecture and with the increased attrition of metal particles. Therefore, copious irrigation seems to be even more essential for ultrasonic implant site preparation than for the conventional method.⁽²¹⁾

5. Nerve mobilization for implant placement: A case report was published in which a new surgical approach to Inferior alveolar nerve mobilization was performed using a specifically engineered device for simplified bone surgery. It enabled the surgeon to cut hard tissue without injuring the soft tissues. Therefore, there is a lower risk of damaging the Inferior Alveolar Nerve, and it is possible to reduce overstretching of the mental nerve by creating a smaller bone window and using an apico-coronal inclination of instruments to capture the neurovascular bundle.⁽²²⁾

6. Distraction osteogenesis for implant placement: A case report for Distraction Osteogenesis followed by Implant placement who had severe maxillary anterior bony defects that were restored by means of piezoelectric distraction osteogenesis, followed by dental implant placement. Clinical, radiological, and histological results showed that the reconstruction was successful.⁽²³⁾

7. Implant relocation: Implant relocation is a new surgical technique for correcting the alignment of mal-positioned implants by mobilizing them with the surrounding bone until the desired position is achieved. In a case report 25-year-old woman was treated for the malposition of an implant in the maxillary left canine site. The results suggest that inadequately axially inclined implants can be

successfully reconfigured using segmental piezoelectric osteotomies.⁽²⁴⁾

8. Sinus lift procedure (Fig. 7)

a. A study observed no differences in the occurrence of Schneiderian membrane perforation between palatal versus vestibular piezosurgical open-sinus lift. They concluded that the palatal approach provided greater postoperative comfort, especially for edentulous patients, because full dentures could be delivered directly after surgery with an almost perfect fit.⁽¹⁶⁾

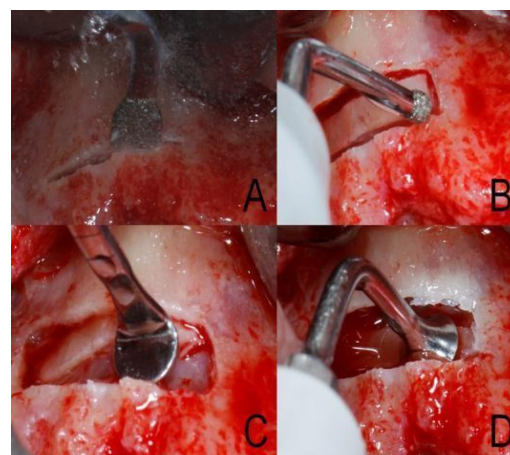


Fig. 7: Sinus lift procedure

b. A new surgical technique, the piezoelectric bony window osteotomy and sinus membrane elevation (PBWO and PSME), was discussed to simplify surgery of the maxillary sinus that reduces the possibility of postoperative complications and making the results comparable to those obtained using a standard implant technique. The new surgical protocol, using piezoelectric instruments to perform the PBWO and PSME, radically reduces the incidence of membrane perforation.⁽²⁵⁾

c. A comparative study to investigate the performance of rotary instruments compared with a piezoelectric device during maxillary sinus floor elevation. This study concluded that piezosurgery and conventional instruments did not show any differences in the clinical parameters investigated for maxillary sinus floor elevation.⁽²⁶⁾

9. Bone splitting (Fig. 8): A pilot study was done to present a new surgical technique, modulated-frequency piezoelectric energy scalpels, to permits the expansion of the ridge and the placement of implants in single-stage surgery in positions that were not previously possible with any other method. A careful evaluation of the site when reopened after 3 months revealed that the ridge was

mineralized and stabilized at a thickness of 5 mm

and the implants were osseointegrated.⁽⁴⁾

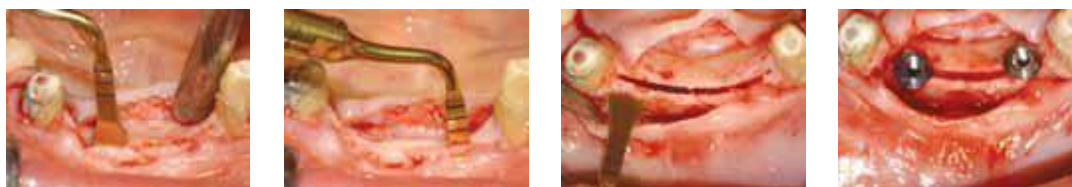


Fig. 8: Ridge expansion technique

10. Bone osteotomy or corticotomy: A comparative study was conducted to establish the differences between 3 osteotomy techniques and to perform a quantitative roughness analysis of the osteotomized bone surfaces. The ultrasonic technique preserved the original structure of bone.⁽⁴⁾

11. Harvesting bone block and bone grafting (Fig. 9): An in vivo study was conducted to describe the efficacy and safety of piezoelectric surgery during intraoral bone harvesting of anterior maxilla. This device does not cause soft tissue lacerations or burns during osteotomy. It produces less vibration and noise because it uses microvibrations in contrast to macrovibration and extreme noise that occurs with surgical burs or saws.⁽²⁷⁾



Fig. 9: Block bone grafting

Conclusion

Piezosurgery is accompanied by minimal intra-operative bleeding. The method does not traumatize bone thermally and post-surgical wound healing is rapid. In contrast, traditional cutting or drilling osteotomes are relatively crude tools, with rotating instruments capable of producing excessive high temperature during osseous drilling. It results in marginal osteonecrosis and impaired bony regeneration. Piezosurgery has limitations like different learning curve, difficulty in performing the deeper osteotomies and also the economic aspects of the device. The biologic effect of piezosurgery on bone has been reported to be more favourable for osseous repair and remodelling than conventional motorized instruments. It has helped surgeons to make the results of bone surgery more predictable and has improved healing, minimized the trauma and provide greater safety for the patients. Many more studies have to be conducted to know in detail the influence of piezosurgery on hard and soft tissue, and its post-operative healing.

References

1. Seshan H, Konuganti K, Zope S. Piezosurgery in periodontology and oral implantology. *J Indian Soc Periodontol* 2009;13(3):155-56.
2. Parmar D, Mann M, Walmsley AD, Lea SC. Cutting characteristics of ultrasonic surgical instruments. *Clin Oral Impl Res* 2011(22):1385-90.
3. <https://www.wisegeek.com/what-is-piezosurgery.htm#didyouknowout>
4. Rahnama M, Czupkallo L, Czajkowski L, Graszka J, Wallner J. The use of piezosurgery as an alternative method of minimally invasive surgery in the authors' experience. *Videosurg Miniinv* 2013;8 (4):321-26.
5. Agarwal, Esha, Sujata Surendra Masamatti, and Ashish Kumar. "Escalating Role of Piezosurgery in Dental Therapeutics." *Journal of clinical and diagnostic research: JCDR* 8.10 (2014).
6. Varghese, Litty, et al. "Research and reviews: journal of dental sciences."
7. Bains V, Mohan R, Bains R. Application of ultrasound in periodontics: Part I. *J Indian Soc Periodontol* 2008;12(2): 29-33.
8. Yaman Z, Suer BT. Piezoelectric surgery in oral and maxillofacial surgery. *Ann Oral Maxillofac Surg* 2013 Feb 01;1(1):5.
9. Bianchetti et al. United states patent; 2004.
10. Carranza, Fermin A., and Michael G. Newman, eds. *Clinical periodontology*. WB Saunders Company, 1996.
11. <https://www.mectron.com> (Piezosurgery: The new dimension in bone surgery. Mectron medical technologies).
12. Vercellotti T, Nevins ML, Kim DM, Nevins M, Wada K, Schenk RK, Fiorellini JP. Osseous Response following Resective Therapy with a Piezosurgery®. *Int J Periodontics Restorative Dent* 2005;25:543-49.
13. Preti G et al. Cytokines and Growth Factors Involved in the Osseointegration of Oral Titanium Implants Positioned Using Piezoelectris Bone Surgery Versus a Drill Technique: A Pilot Study in Minipigs. *J Periodontol* 2007;78:716 -22.
14. Harder S, Wolfart S, Mehl C, Kern M. Performance of ultrasonic devices for bone surgery and associated intraosseous temperature development. *Int J Oral Maxillofac Implants* 2009;24:486 -90.
15. Chiriac G, Herten M, Schwarz F, Rothamel D, Becker J. Autogenous bone chips: influence of a new piezoelectric device (Piezosurgery®) on chips morphology, cell viability and differentiation. *J Clin Periodontol* 2005;32:994-99.

16. Pavlikova G, Foltan R, Horka M, Hanzelka T.. Piezosurgery in oral and maxillofacial surgery. *Int J Oral Maxillofac Surg* 2011;40:451–57.
17. Alberto G. Ultrasonic osteotomy in oral surgery and Implantology. *Oral Surg Oral Med Oral Pathol Oral Radiol Endo* 2009;108:360-67.
18. Rashad A, Kaiser A, Prochnow N, Schmitz I, Hoffmann E, Maurer P. Heat production during different ultrasonic and conventional osteotomy preparations for dental implants. *Clin Oral Impl Res* 2010;22:1361–65.
19. Blus C, Szmukler-Moncler S. Atraumatic Tooth Extraction and Immediate Implant Placement with Piezosurgery: Evaluation of 40 Sites after at Least 1 Year of Loading. *Int J Periodontics Restorative Dent* 2010;30:355-63.
20. Alberti D. L, Donnini F, Alberti D. C, Camerino M. A comparative study of bone densitometry during osseointegration: Piezoelectric surgery versus rotary protocols. *Quintessence Int* 2010;41:639-44.
21. Rashad A, Sadr-Eshkevari P, Weuster M, Schmitz I, Prochnow N, Maurer P. Material attrition and bone micromorphology after conventional and ultrasonic implant site preparation. *Clin Oral Impl Res* 2011;17:1-5.
22. Bovi M. Mobilization of the Inferior Alveolar Nerve with simultaneous implant insertion: A New Technique. A Case Report. *Int J Periodontics Restorative Dent* 2005;25:375-83.
23. Lee HJ, Ahn MR, Sohn DS. Piezoelectric Distraction Osteogenesis in the Atrophic Maxillary Anterior Area: A Case Report. *Implant Dent* 2007;16:227–34.
24. Claudio Stacchi, Fulvia Costantinides, Matteo Biasotto, Roberto Di Lenarda. Relocation of a Malpositioned Maxillary Implant with Piezoelectric Osteotomies: A Case Report. *Int J Periodontics Restorative Dent* 2008;28(5):489-95.
25. Vercellotti T, De Paoli S, Nevins M. The Piezoelectric Bony Window Osteotomy and Sinus Membrane Elevation: Introduction of a New Technique for Simplification of the Sinus Augmentation Procedure. *Int J Periodontics Restorative Dent* 2001;21:561–67.
26. Barone A, Santini S, Marconcini S, Giacomelli L, Gherlone E, Covani U. Osteotomy and membrane elevation during the maxillary sinus augmentation procedure: A comparative study: piezoelectric device vs. Conventional rotative instruments. *Clin Oral Implant Res* 2008;19:511-15.
27. Sohn DS, Ahn MR, Lee WH, Yeo DS, Lim SY. Piezoelectric Osteotomy for Intraoral Harvesting of Bone Blocks. *Int J Periodontics Restorative Dent* 2007;27:127-31.