

The pertinacious dilemma –endo-perio lesion

MV Ramoji Rao¹, PV Prasanna Kumar^{2,*}, M. Sathish³, P Lakshmi Preethi⁴, D. Rachita Rao⁵

¹Professor & HOD, ^{2,5}PG Student, ^{3,4}Reader, Dept. of Periodontology, NTRUHS

***Corresponding Author:**

Email: prasannapvk@gmail.com

Abstract

Periodontal disease affects the supporting tissues of the teeth and endodontic lesions effects pulpal and periapical tissues. These lesions provide many challenges to clinicians in day to day life in the diagnosis, treatment and management, particularly when both the lesions appear in a single tooth. Similar to other diseases, diagnosis can be made by obtaining history and by through clinical and radiographic examination. The diagnosis is essential in determining the type of treatment needed. The success of the therapy mainly depends on removing the cause and elimination of risk factors for developing the disease.

Introduction

Modern dentistry comprises of various specialties and it appears that all these specialties are interconnected to offer the best treatment to the patients. Embryonically, anatomically and functionally the pulpo-periodontal tissues are closely related to each other as they have single source of development that is from the mesoderm of the developing tooth bud.⁽¹⁾ The papilla and follicle develop from the cells of the developing tooth bud from which pulp tissue develops from dental papilla and periodontal ligament from the later and are separated from each other by Hertwigs epithelial root sheath.⁽²⁾ For many decades, investigators have conducted studies on the inter-relation between endodontics and periodontics that are intimately connected to each other to offer better treatment options to people who have combined lesions of dental caries leading to pulpal and periodontal disease.

In 1919 Turner and Drew are the first to identify the effects of periodontal tissues on pulpal tissues.⁽³⁾ Simring and Goldberg first described the interrelationship between periodontal and pulpal tissues in 1694.⁽⁴⁾

The endodontic periodontal lesions have been characterized by the spread of the lesion from pulp to periodontal tissues and vice versa, in a single tooth even though the disease may be the result of pulpal or periodontal tissues.

Endodontic-periodontal lesions persists as two different diseases entities but show signs of both the disease process in single tooth making the diagnosis difficult and makes the clinical diagnosis and treatment a challenge for clinician. Therefore knowledge of both disease processes and pathogenesis is essential for proper diagnosis and treatment planning.

Classification of endodontic- periodontal lesion

Simon et al (1972): Based on etiology and progression of the disease:

- a. Endodontic lesion
- b. Primary endodontic lesion with secondary periodontal involvement
- c. Periodontal lesion

- d. Primary periodontal lesion with secondary endodontic involvement
- e. True combined lesion
- f. Concomitant endodontic and periodontal lesion (Belk and Guntmann).⁽⁵⁾

Guldener and Langeland (1982)

1. Based on possible pathologic relationships:
 - a. **Endodontic – periodontal lesions:** In endodontic-periodontal lesions, pulpal changes are seen more rapidly than periodontal changes. The first pulpal change is necrosis of the pulp tissue. This causes drainage of periapical infection into the periodontal ligament and alveolar bone. This demonstrated clinically as may a localized, deep, periodontal pocket extending to the apical area of the tooth.
 - b. **Periodontal – endodontic lesions:** In periodontal-endodontic lesions, the pulpal necrosis is caused by the bacterial infection from periodontal pocket communicate the pulp tissue pulp by way through the accessory canals and through apical foramen. As scaling and root planning removes so part of cementum and underlying dentin, this may also cause pulpitis through bacterial penetration into dentinal tubules.
 - c. **Combined lesions:** The tooth which contains both pulpal necrosis and periapical lesion pulpal necrosis is referred as a combined lesion. These lesions could display involvement of specific bacteria responsible for causing pulpal and periodontal disease.⁽⁶⁾

Etiologic Factors

Specific microorganisms play an important role in the endodontic-periodontal lesions. Various microorganisms act in association with each other or alone in promoting the disease process.

Bacteria: Endodontic periodontal lesions are most commonly occurred by bacterial infections.⁽⁷⁾ In several

studies on bacteria, demonstrated that a single bacteria is responsible for both the lesions.⁽⁸⁾ Spirochetes are found in both pulpal and periodontal tissues hence found in both endodontic and periodontal diseases, but more frequently identified in subgingival plaque than compared in the root canals.⁽⁹⁾ The most commonly identified species in root canal are *treponema denticola*⁽¹⁰⁾ and *treponema maltiphilium*.⁽¹¹⁾

Fungi: Endodontic infections are most commonly associated with fungi have been documented.⁽¹²⁾ *Candida albicans* are the most identified forms that invade the root canals. The exact mechanism for the colonization of the species is not known but it was demonstrated that the aseptic conditions in the root canals during treatment or post treatment or low nutrient levels helps these species to grow and cause the endodontic lesion.⁽¹³⁾ It has been suggested that approximately 20% of adult periodontitis patients harbor subgingival yeasts, of which *candida albicans* are the one that are frequently identified.⁽¹⁴⁾ Fungal re-infection can be prevented by maintaining proper aseptic conditions and integrity of dental hard tissues.

Viruses: Viruses may also play a role in pathogenesis of endo perio diseases. In patients with periodontal disease, the viruses found are

1. Herpes simplex viruses in gcF.
2. Cytomegalo viruses (65%) in periodontal pockets and (85%) in gingival tissues.
3. Epstein barr virus 1- (40%) in periodontal pockets (80%) in gingival tissues.⁽¹⁵⁾

Some viruses such as herpes viruses may increase the occurrence of bacterial growth that is *porphyromonas gingivalis*, *bacteroids forsythus*, *prevotella intermedis*, *prevotella nigrescenes* suggesting a role in growth of periodontal pathogens.⁽¹⁶⁾ Recent data suggest that certain viruses may also be involved in pulpal disease and associated periapical pathoses. Cytomegalo virus and however, more research is needed further to clarify the relationship between viral infections and pulpal and/or periodontal diseases.

Contributing Factors: The contributing factors in the development of endodontic-periodontal lesions can be of varied nature. Along with many non-pathogens, the factors such as inadequate endodontic treatment, coronal leakage, traumatic injuries, root perforations and developmental anomalies, all these factors play an important role in the development of the endodontic periodontal lesions.

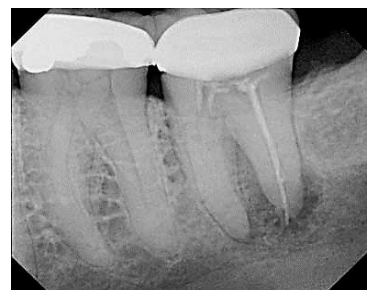Inadequate Endodontic Treatment: Root canals that are not shaped or inadequately obturated or incompletely filled leads to the failure of the treatment.⁽¹⁷⁾ In order to prevent the progression of the lesions, endodontic retreatment should be done and this have shown a high success rate in recent times.

Coronal Leakage: Coronal leakage refers to leakage of microbes and other irritants from the coronal aspect of the tooth to the root canal filling. Fracture of crown or delayed cementation or defective restoration causes the

coronal leakage.⁽¹⁸⁾ So care must be taken to prevent from this type of failures. Hence it is essential that root canal system be protected by good endodontic obturation and well sealed coronal restoration.⁽¹⁹⁾

Traumatic Injuries: Traumatic injuries of teeth such as enamel fracture, crown fractures with and without pulp involvement may involve the pulp and surrounding periodontal attachment apparatus and leads to development of endodontic and periodontal lesions.⁽²⁰⁾

Root Perforations: Endodontic failures may also result from root perforations that further lead to periodontal disease by involving the surrounding supporting structures. Teeth that have extensive carious lesions, over obturation or furcation involvement leads to failure of the treatment and development of endodontic lesions. The size, location, time of diagnosis, degree of tissues damaged and ability to prevent or arrest the lesion play a key role in the prognosis of the effected teeth.⁽²¹⁾



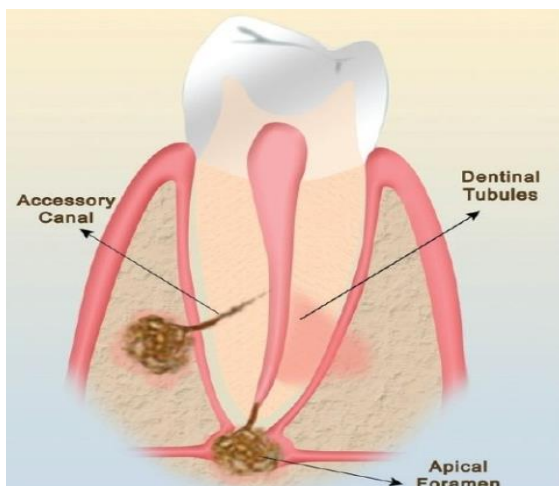
Mandibular second molar showing radiolucency on the periapical region of distal root due to perforation of gutta percha.

Pathways of Communication

As the etiology suggest that microbial composition of both the infected pulpal and periodontal lesions have demonstrated similarities. Not only in the microbial composition but also in the cellular infiltrates.⁽²²⁾ This suggests that one disease process may leads to the development of the other either directly or indirectly. These findings infer that cross contamination between the pulp and periodontal tissues is possible.⁽²³⁾

The pathways of communication for endodontic and periodontal lesions are broadly divided into:

1. Anatomical and
2. Non-physiological pathways



Apical Foramen

The apical foramina and lateral canals provide nutrition for pulp and periodontal tissues for their growth. Through the blood supply from apical foramina and lateral canals the infection from pulp, enters into periodontal tissues and vice versa. The damage caused by periodontal tissues on the pulpal tissues are very less, whereas effected endodontic tissues have more impact on the periodontal tissues. The periodontal infection effects pulp only when the bacterial infection involves the main apical foramina. Various products which help in disease progression like enzymes, metabolites, antigens etc. leads to necrosis of pulp and effect the periodontium through the apical foramen, initiating and perpetuating an inflammatory response there resulting in destruction of periodontal attachment apparatus and resorption of the adjacent alveolar bone, external root resorption.

Lateral Canals

Preiswerk (1901) was the first one to describe root canal ramifications. The root ramifications are also called as lateral canals or accessory canals. Lateral canals normally harbor connective tissue and vessels which connect the circulating system of the pulp with that of the periodontal ligament. Most commonly accessory canals are found near the apical part of the root and in the molar furcation region. The frequency of the ramifications on the root surface are as follows:

- Apical third 17%, body of the root 8.8% coronal third 1.6%, furcation 46% in first molars and 50 to 60% in any multi-rooted teeth.

Non Physiological Pathways

These include root canal perforations, iatrogenic trauma during treatment or due to improper manipulation of endodontic instruments can also lead to perforation of the root. Not only through the apical foramina, pulpal and periodontal tissues are effected by trauma caused by vertical root fractures in both vital and non-vital tooth. Therapeutic procedures such as lateral condensation

technique and the teeth restored with intracanal posts are more prone for risk of root fractures caused during or immediately after treatment.⁽²⁴⁾

Treatment

Primary Endodontic Disease: The endodontic diseases are commonly associated with carious tooth. This is clinically observed as abscess that drains through the sulcus through the periodontal ligament. The sinus tract can be evident in chronic cases in radiographs by placing a gutta percha in the sinus tract. Healing of the endodontic lesion is often faster and can be achieved only after root canal therapy. The signs of endodontic lesions disappear when the infected pulp is removed and the canals are cleaned and shaped properly.

Primary Periodontal Diseases: The first preference for primary periodontal lesions is hygiene phase. The prognosis of primary periodontal diseases is affected by various factors. Primary periodontal lesions often become difficult when associated with poor restorations and developmental grooves that are involved in the lesion. Only after the completion of non-surgical therapy, the surgical therapy is performed if necessary. The prognosis of periodontal lesions is poorer than that of endodontic lesions and depends on various factors such as apical extension of the lesion and also on the efficacy of periodontal treatment and the time of amount of tissue that is lost at the time the diagnosis is made.

True Combined Diseases: Most commonly true combined lesions are treated initially as primary endodontic lesion with secondary periodontal involvement. After completion of endodontic therapy planning should be made for treating the periodontal disease. However the prognosis of a true combined lesion is often poor or even hopeless, when there is extensive periodontal attachment loss. Different biomimetic materials such as the use of bone grafts and membranes have showed predictability in regeneration of lost tissues. Thus the prognosis of combined diseases rests on the efficacy of periodontal therapy.

Conclusion

In conclusion, as endodontic periodontal disease is not a single entity and its simultaneous occurrence in a single tooth makes the diagnosis and treatment planning difficult. Hence complete understanding of the etiology, pathogenesis and pathways of spread of the endodontic and periodontal lesions is necessary for better success of the endodontic periodontal diseases.

References

1. Sujatha Gopal, Kalwa Pavan kumar, Krishna Prasad Shetty, Vikas Jindal, Saritha M- Interrelationship of endodontic periodontal lesions- An overveiw. IJDS 2011;2(3):55-9.
2. Preetinder singh - Endo-perio Dilemma: a brief review. Dent Res J 2011;8(1): 39-47.

3. Turner JH, Drew AH - Experimental injury into bacteriology of pyorrhea, Proc R Soc.Med (Odontol) 1919;12:104-118.
4. Simring M., Goldberg M - The pulpal pocket approach: retrograde periodontitis, J Periodontol 1964;35(1):22-48.
5. J.H. Simon, D. H. Glick, and A. L. Frank, "The relationship of endodontic-periodontic lesions". J periodontol, 1972; 43(4):202-8.
6. Guldener PHA- Die Beziehung zwischen Pulpa- und Parodontalerkrankungen. Dtsch Zahnarzt Z 1975;3:377-9.
7. Van Winkelhoff AJ, Boutaga K. Transmission of periodontal bacteria and models of infection. J Clin Periodontol 2005; 32 (Suppl. 6): 16-27.
8. Rupf S, Kannengießer S, Merte K, Pfister W, Sigusch B, Eschrich K. Comparison of profiles of key periodontal pathogens in periodontium and endodontium. Endod Dent Traumatol. 2000;16:269-75.
9. Lars Fabricus, Gunnar Dahlen, Alf E. Ohman and Ake J. R. Moller. Predominant indigenous oral bacteria isolated from infected root canals after varied times of closure. Scand J Dent Res. 1982;90(2):134-44.
10. Rôças IN, Siqueira JF Jr, Santos KR, Coelho AM. "Red complex" (*Bacteroides forsythus*, *Porphyromonas gingivalis*, and *Treponema denticola*) in endodontic infections: a molecular approach Oral Surg Oral Med Oral Pathol Oral Radiol Endod. 2001;91(4):468-71.
11. Jung IY et al. Identification of oral spirochetes at the species level and their association with other bacteria in endodontic infections. Oral Surg Oral Med Oral Pathol Oral Radiol Endod. 2001;92(3):329-34.
12. Siqueira JF, Jr., Sen BH. Fungi in endodontic infections. Oral Surg Oral Med Oral Pathol Oral Radiol Endod 2004;97(5):632-41.
13. Siren EK, Haapasalo MP, Ranta K, Salmi P, Kerosuo EN. Microbiological findings and clinical treatment procedures in endodontic cases selected for microbiological investigation. Int Endod J. 1997;30(2):91-5.
14. G.Dahlen and M. Wikstrom. Occurrence of enteric rods, staphylococcus and candida in subgingival samples. Oral microbiol Immunol 1995;10(1):42-6.
15. Contreras A, Nowzari H, Slots J. Herpes viruses in periodontal pocket and gingival tissue specimens. Oral Microbiol Immunol. 2000;15(1):15-8.
16. Contreras A, Umeda M, Chen C, Bakker I, Morrison JL, Slots J. Relationship between herpes viruses and adult periodontitis and periodontopathic bacteria. J Periodontol. 1999;70(5):478-84.
17. Rotstein I, Salehrabi R, Forrest JL- Endodontic treatment outcome: survey of oral health care professionals. J Endod. 2006;32(5):399-403.
18. Saunders WP, Saunders EM. Coronal leakage as a cause of failure in root canal therapy: a review. Endod Dent Traumatol. 1994;10(3):105-8.
19. Ray HA, Trope M. Periapical status of endodontically treated teeth in relation to the technical quality of the root filling and the coronal restoration. Int Endod J. 1995;28(1):12-8.
20. Bakland LK, Andreasen FM, Andreasen JO. Management of traumatized teeth. In: Walton RE, Torabinejad T, editors. Principles and Practice of Endodontics. 3rd ed. Philadelphia: WB Saunders; 2002:445-65.
21. Torabinejad M, Lemon RL. Procedural accidents. In: Walton RE, Torabinejad M, editors. Principles and Practice of Endodontics. 2nd ed. Philadelphia: W.B. Saunders; 1996:306-23.
22. Kipioti A, Nakou M, Legakis N, Mitis F. Microbiological findings of infected root canals and adjacent periodontal pockets in teeth with advanced periodontitis. Oral Surg Oral Med Oral Pathol. 1984;58(2):213-20.
23. Bergenholtz, Lindhe J. Effect of experimentally induced marginal periodontitis and periodontal scaling on the dental pulp. J Clin Periodontol. 1978;5(1):59-73.
24. Zehnder M, Gold SI, Hasselgren G. Pathologic interaction in pulpal and periodontal tissues. J Clin Periodontol. 2002;29(8):663-71.