

Treatment of altered passive eruption by surgical gingivectomy: A case report

Pooja Darakh^{1,*}, Yogesh Khadtare², Pramod Waghmare³, Amita Mali⁴

¹PG Student, ²Assistant Professor, ³Professor, ⁴Professor & HOD, Dept. of Periodontology,

***Corresponding Author:**

Email: ppojjadarakh@gmail.com

Abstract

In recent times, dentists, as well as patients, have developed greater awareness about the impact of teeth and gingiva in the attractiveness of smile. Short clinical crowns are considered unaesthetic and bring patients' to the dentist to rectify their gummy smile. The gingival complex plays a vital role in the overall beauty of an individual's smile. Altered passive eruption is a clinical situation that occurs due to excessive gum overlapping the enamel, thus contributing to a gummy smile. Many techniques are available to correct the problem of gummy smile due to altered passive eruption. However, there has to be a sound knowledge about the classification and treatment options of altered passive eruption so as to treat patients' accurately. Careful consideration of biologic width and the dentogingival junction is needed to adequately diagnose the true etiology and plan an effective treatment. In the current case report, altered passive eruption was treated with surgical gingivectomy.

Keyword: Altered passive eruption, Esthetic smile, Gingivectomy

Introduction

An esthetic smile is considered as an important aspect of person's beauty. The periodontal tissues are considered as an important factor to achieve this esthetic smile. To achieve excellent periodontal esthetics it requires treatment planning with evolution of all factors that interfere with the symmetry of smile elements.

A smile may be considered as pleasant when the upper teeth are completely exposed, and approximately 1mm of buccal gingival tissue is visible. However, a gum exposure not exceeding 2-3mm is also considered pleasant, whereas an excessive exposure (> 3 mm) is generally considered not attractive by many patients [Allen, 1988].⁽¹⁾ Excessive gingival display is a condition characterized by excessive exposure of the maxillary gingiva during smiling, commonly called a "gummy smile".⁽²⁾ Gummy smile or excessive gingival display may be because of several factors such as gingival enlargement, altered passive eruption, insufficient clinical crown, vertical maxillary excess and short lip.⁽³⁾ Evaluation of crown length is important because it may be principal cause of excessive gingival display.⁽⁴⁾

Altered passive eruption (APE) is characterized by excessive gingiva in relation to the crown of the tooth. This condition can be localized or generalized and should be considered while planning orthodontic, restorative and esthetic treatment.

Tooth eruption can be active or passive[Fig. 1]. Active eruption is the movement of teeth in occlusal direction while passive eruption is exposure of teeth by apical migration of gingiva.⁽⁵⁾

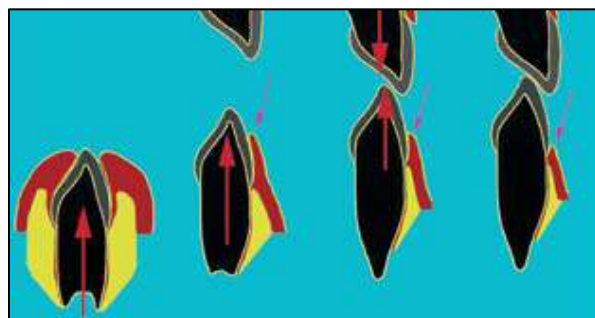


Fig. 1: Active and passive phases of dental eruption

Passive eruption can be divided into 4 stages according to the relationship between the epithelial attachment and the CEJ[Fig. 2].⁽⁶⁾

In stage 1, the epithelial attachment —the junctional epithelium — rests on the enamel surface.

In stage 2, the epithelial attachment rests on the enamel surface and the cemental surface apical to the CEJ.

In stage 3, the epithelial attachment rests on the cemental surface, and

In stage 4, inflammation causes the epithelial attachment to migrate apically

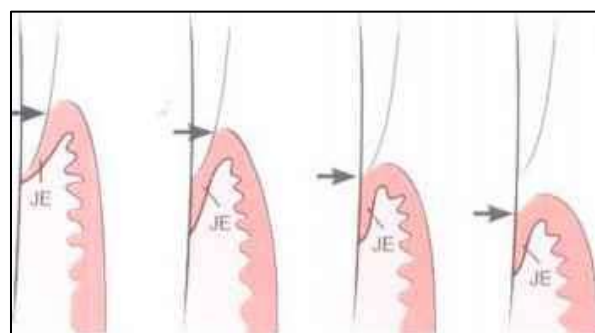


Fig. 2: Stages of passive eruption (Gottlieb and Orban)

When passive eruption does not progress stage 1 or stage 2, it is referred to as altered passive eruption (APE).

APE is classified into two types [Coslet et al]:⁽⁷⁾

APE TYPE 1- It is determined by exclusive failure of passive eruption, giving rise to excessive gingival overlap on the anatomical crown of the tooth, while in contrast the distance from the bone crest to the cemento enamel junction would be normal.

APE TYPE 2- It is determined by primary failure of active eruption phase, as a result of which the tooth will not emerge sufficiently from the alveolar bone, thereby leaving cemento enamel junction very close to bone crest. This would prevent apical migration of gums during passive eruption phase.

Both types are in turn classified into subtypes A and B [Table 1]. In subtype A, the distance between the

bone crest and cemento enamel junction is 1.5- 2 mm (which allows a normal dimension of connective fiber attachment in the root cement), while in subtype B the bone crest lies very close to, or even at the same level as the cemento enamel line [Fig 3].

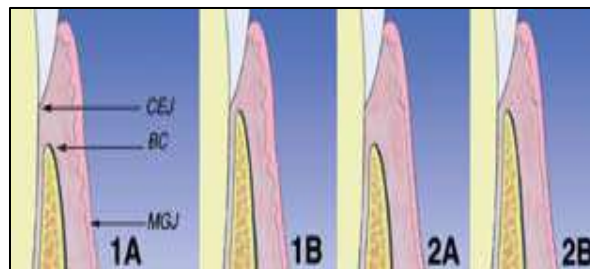


Fig. 3: Morphological classification of altered passive eruption (APE) according to Coslet

Table 1: Classification of altered passive eruption

Type	Description	Treatment
1A	Osseous crest apical to the cemento enamel junction (CEJ) Adequate amount of attached gingiva Gingival margin incisal to the CEJ	Gingivectomy
1B	Osseous crest at the CEJ Inadequate amount of attached gingiva Gingival margin incisal to the CEJ	Gingivectomy and osseous surgery
2A	Osseous crest at the CEJ Inadequate amount of attached gingiva Gingival margin incisal to the CEJ	Apically positioned flap
2B	Osseous crest at the CEJ Inadequate amount of attached gingiva Gingival margin incisal to the CEJ	Apically positioned flap and osseous surgery

The occurrence of altered passive eruption is unpredictable, but the frequency in the general population is about 12%.⁽⁸⁾ To diagnose altered passive eruption, clinical examination is required. The common clinical signs are

- The square appearance of the crowns. The gums positioned coronally over the tooth produce a square clinical crown silhouette, when the actual anatomical shape may be ovoid or elliptic, and thus esthetically much more attractive.
- On smiling, the gums are exposed by the upper lip. When such gum exposure exceeds 2-3 mm, it can produce a poor esthetic effect known as gummy smile.⁽⁹⁾
- Flattened gingival festooning.

Normally the CEJ lies just apical to gingival margin of the crown. Sulcus depth is usually 2 to 3mm. In APE, the CEJ might be from 5 to 10mm apical to gingival margin.⁽¹⁰⁾

This problem can be corrected by various periodontal surgeries like gingivectomy, gingivoplasty, apically displaced flap with or without osseous resection and undisplaced flap.⁽¹¹⁾

The present case report describes the patient with APE treated with gingivectomy.

Case Report

A 23 year old female patient reported to the Department of Periodontology with the complain of bleeding gums since last 6months. She also complained of display of gingiva when she smiles.

There was no history of any systemic illness. Furthermore, there was no history of any adverse habits. Clinically, intraoral examination showed that gingiva was pink with slight melanin pigmentation with soft and edematous consistency and bleeding on probing was present. The probing depths were in the range of 3-5mm. Routine blood investigations were carried out and it showed normal values. The bone sounding was carried out in order to determine the level of bone and position of CEJ in relation to gingival margin and gingival biotype. The gingiva was of thick flat biotype.

The case was diagnosed as delayed passive eruption of Type I Subtype A in relation to tooth upper right second premolar to upper left second premolar. Since the tissue from bone to gingival crest was more than 3mm and there was adequate zone of attached gingiva, gingivectomy was planned.

The patient was explained about the surgical procedure and informed consent was obtained. Thorough scaling and polishing was done and oral hygiene instructions were given. The diagnostic cast were made and used to prepare stents. The stent was used as a guideline for creating a new gingival margin and the markings were made on the gingiva. After administration of LA, external bevel incision was given in the region of upper right second premolar to upper left second premolar.

The curettes were used to remove marginal collar of the tissue and debridement was done. The periodontal dressing was then placed in that area. The patient was given antibiotics and analgesics and was recalled after 7days, 1 month and 3 month for follow up.

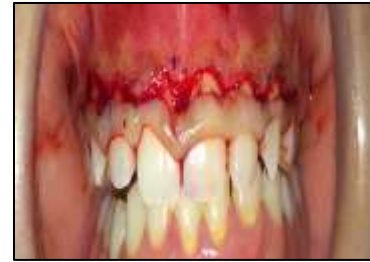

Fig 7: Excision of the tissue

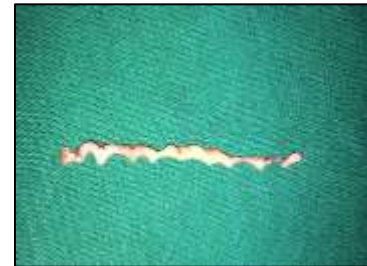

Fig 8 : Excised tissue

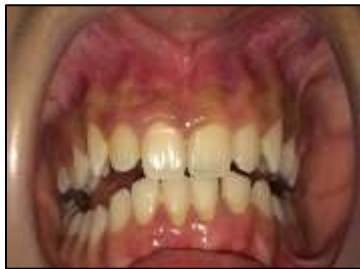

Fig 4: Pre –operative

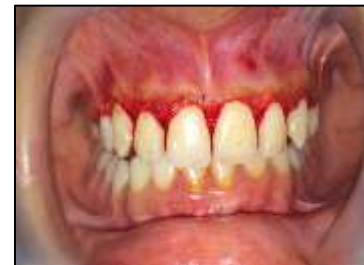

Fig 9: Immediately after treatment

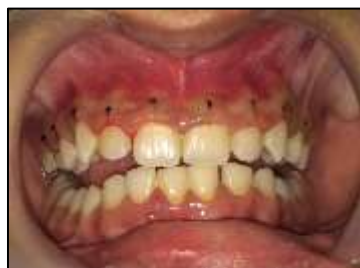

Fig 5: Pocket marking done

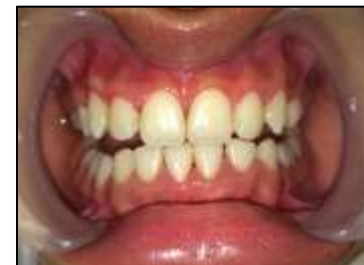

Fig 10:1 week post-operative view

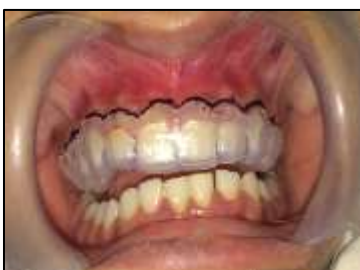

Fig 6: The stent used as a guideline

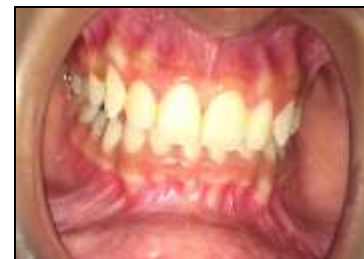

Fig 11: 1month post-operative view

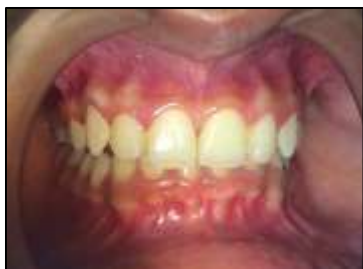

Fig 12: 3months post-operative view

Discussion

Altered passive eruption is an uncommon occurrence that is diagnosed by clinical observation. It is defined as dentogingival relationship wherein the margin of the gingiva is positioned incisally/ occlusally on the anatomic crown in adulthood and does not approximate the CEJ [Volchansky 1974].⁽¹²⁾ The first step in diagnosing altered passive eruption is observing the patient while smiling naturally.⁽¹³⁾ Several authors^(14,15) have suggested evaluating the smile for the amount of incisor and gingival display and the transverse dimension of the smile, whereas Sarver [2001]⁽¹⁶⁾ suggested evaluating the patient with a posed (voluntary) and unposed (involuntary) smile. If there is an excessive display of gingiva during the smile, further diagnostic data are required. First, the length and activity of the upper lip must be evaluated. If the gummy smile is due solely to inadequate lip length or hyperactivity, no treatment is indicated.⁽¹⁷⁾ Some degree of gingival display may be esthetically pleasing and, according to Sarver, may be considered youthful (one characteristic of aging is to show less of the maxillary incisors, so a greater incisal display may indicate youth). With the lips in repose, males typically show less of the maxillary incisors and more of the mandibular incisors than females.

The CEJ should be located to determine the presence or absence of altered passive eruption. If the CEJ is located in a normal position in the gingival sulcus, then the patient does not have altered passive eruption. In this situation, the short teeth are due to incisal wear or a variation of normal anatomy.⁽¹⁸⁾

In altered passive eruption the smile looks “gummy”. After evaluating the presence of “gummy smile” the tooth smile components can be analysed. Usually, maxillary central incisors have width to length ratio of 0.75 to 0.80. The gingival margin of maxillary lateral incisors is normally 1.00 mm below that of adjacent maxillary central/canines. The margins of central incisors should be at the same level of the canine. The contour of the labial gingival margins should follow the CEJs of teeth, and there should be a papilla between each tooth.

In case of APE the treatment modalities are conventional gingivectomy (external-beveled) and flap (internal-beveled) with the removal of bone tissue. More invasive techniques can be used to treat APE such

as orthognathic surgery and plastic surgery. These invasive techniques are considered in cases with excess vertical maxillary excess and hypermobile/short upper lip.

The choice of the surgical procedure is based on the gingival architecture, the level of crestal bone and the amount of keratinized gingiva. If it is anticipated that 2-3mm of keratinised gingiva will be present after surgery than external bevel gingivectomy is preferred. In the present study the patient showed APE type 1 because she had an increase in gingiva when free gingiva from mucogingival junction was measured. Hence the gingivectomy procedure was planned. The procedure gave successful and desired results with uneventful healing.

Conclusion

The gummy smile due to altered passive eruption poses challenge to the dentist but with correct diagnosis and appropriate therapy for excessive gingival display, dental esthetics can be improved. The harmony in the smile was obtained through correct diagnosis and treatment planning. External bevel gingivectomy is an important choice of treatment because it is less invasive technique and it is possible to establish esthetic smile through it.

References

1. Allen EP. Use of mucogingival surgical procedure to enhance esthetics. *Dent Clin North Am* 1988;32:307-330.
2. Allen EP. Surgical crown lengthening for function and esthetics. *Dent Clin North Am* 1993;37(2):163-79.
3. Lang NP. Periodontal considerations in prosthetic dentistry. *Periodontol* 2000 1995;9:118-31.
4. Wolffe GN, van der Weijden FA, Spanauf AJ, de Quincey GN. Lengthening clinical crowns - a solution for specific periodontal, restorative, and esthetic problems. *Quintessence Int* 1994;25(2):81-8.
5. Stephen Brown, D.D.S. 220 South 16th Street, Suite 300, Philadelphia, PA 19102 (215):735-3660.
6. Gargiulo AW, Wentz FM, Orban B. Dimensions and relations of the dentogingival junction in humans. *J Periodontol* 1961; 32(3):261-7.
7. Coslet GJ, Vanarsdall R, Weisgold A. Diagnosis and classification of delayed passive eruption of the dentogingival junction in the adult. *Alpha Omegan*. 1977; 10:24-28. PMID:8409000.
8. Evian CI, Cutler SA, Rosenberg ES, Shah RK. Altered passive eruption: the undiagnosed entity. *J Am Dent Assoc* 1993; 124(10):107-10.
9. Vig R, Brundo G. The kinetics of anterior tooth display. *J Prosthet Dent*. 1978;39:502-04.
10. Alpiste-Illueca F. Altered passive eruption (APE): A little-known clinical situation. *Med Oral Patol Oral Cir Bucal*. 2011 Jan 1;16. doi:10.4317/medoral.16.e100.
11. Arnett GW, Kreasho RG, Jelic JS. Correcting vertically altered faces: orthodontics and orthognathic surgery. *Int J Adult Orthodon Orthognath Surg* 1998;13(4):267-76.
12. Volchansky A, Cleaton-Jones P. Delayed passive eruption – A predisposing factor to Vincent’s infection. *J Dent Assoc S Africa* 1974;29:291-4.

13. Kokich VG. Esthetics: the orthodontic-periodontic restorative connection. *Semin Orthodont* 1996;2(1):21–30.
14. Miller C.J. The smile line as a guide to anterior esthetics. *Dent Clin North Am* 1989;33(2):157–64.
15. Levine RA, McGuire M. The diagnosis and treatment of the gummy smile. *Compend Contin Educ Dent* 1997;18(8):757–62, 764.
16. Sarver DM. The importance of incisor positioning in the esthetic smile: the smile arc. *Am J Orthod Dentofacial Orthop* 2001;120(2):98–111.
17. Dolt AH 3rd, Robbins JW. Altered passive eruption: an etiology of short clinical crowns. *Quintessence Int* 1997;28(6):363–72.
18. Kokich V. Esthetics and anterior tooth position: an orthodontic perspective. Part I: Crown length. *J Esthet Dent* 1993;5(1):19–23.