

Comparative evaluation of cryosurgery and electrosurgery in gingival depigmentation

Krupa H. Pathak^{1*}, Vijay R. Waghmode²

^{1,2} MDS Periodontology & Oral Implantology

***Corresponding Author:**

Email: krupahpathak@gmail.com

Abstract

Gingival hyperpigmentation is a major aesthetic concern for many people. Although it is not a medical problem, many people complain of dark gums as unaesthetic. Gingival depigmentation is a periodontal plastic surgical procedure, whereby the hyperpigmentation is removed or reduced by various techniques. For depigmentation of gingiva, different treatment modalities have been reported, such as scalpel, cryosurgery, electrosurgery, lasers, etc., this article compares the management with electrosurgery and cryosurgery and also highlights the relevance of cryosurgery.

Keywords: Cryosurgery, Electrosurgery, Gingiva, Lasers, Melanin, Pathologic, Physiologic, Pigmentation.

Introduction

We live in a beauty conscious society, wherein aesthetics is an inseparable part of today's dental treatment.⁽¹⁾ Aesthetic considerations have influenced the management of dental maladies in varying degrees for many years. Patient awareness and expectations have increased recently to the point that less than optimal aesthetics are no longer an acceptable outcome.⁽²⁾

The color of the gingiva is an integral part of many epidemiological evaluations of gingival health, ranging from pale pink and coral pink to deep red and violet.⁽³⁾ The attached and marginal gingiva is generally described as coral pink and is produced by the vascular supply, the thickness and degree of keratinization of the epithelium and the presence of pigment containing cells (melanocytes). Pigmentation is present in buccal, palatal and lingual gingiva⁽²⁾ and is more frequently observed in the anterior region.⁽⁴⁾ Gingival depigmentation is the treatment modality used to remove the melanin hyperpigmentation for esthetic concerns. It is a procedure which has been carried out from several years, with the first procedure dating back to 1950.⁽⁵⁾

Methods aimed at removing the pigment layer:⁽⁶⁾

- Surgical method of de-pigmentation.
- Scalpel surgical technique
- Cryosurgery
- Electrosurgery
- Lasers.
- Neodymium; aluminum-Yttrium-Garnet (Nd-YAG) laser
- Erbium-YAG lasers
- Carbon-di-oxide CO₂ laser.
- Chemical methods of de-pigmentation.

Methods aimed at masking the pigmented gingiva with grafts from less pigmented area.

- Free gingival graft
- Acellular dermal matrix allograft.

The requisites for an ideal treatment modality include minimum discomfort to the patient, minimal or no anesthesia, operator friendliness, less technique sensitivity, minimal or no bleeding during surgery, controlled destruction of the tissues, minimum postoperative complications and finally a pleasing outcome sustaining over a long period of time. Cryosurgical applications offer a simple, economically viable technique because they are relatively inexpensive, easy to handle and do not require the strict protocol as required for laser application.⁽⁷⁾ Regarding the advantages of this method, this technique is easy and rapid to apply, does not require anesthesia or suturing, and finally it does not cause any bleeding or scars.^(8,9)

Electrothermal methods to correct tissue contours prior to prosthetic dentistry or to prepare sulcular tissue for restorative impressions have been used for many years. Early advocates of electrosurgery in dentistry claimed definite advantages over conventional techniques of tissue preparation.⁽²⁾ Electrosurgery was purported to be better controlled because less pressure was needed to sever tissue. The operation was claimed to be much less hemorrhagic due to simultaneous coagulation of blood vessels. No differences in clinical wound healing were observed.⁽¹⁰⁾

However, no study till date has compared these two modalities in the treatment of gingival pigmentation. Hence this article demonstrates a comparative evaluation of managing gingival pigmentation using Cryosurgery and Electrosurgery techniques.

Materials and Methods

The study population consisted of 30 systemically healthy subjects (at 95% confidence interval) aged between 18 to 50 years who reported to Department of Periodontology, Dr. D. Y. Patil Dental College & Hospital, Pimpri, Pune with complaints of bilateral gingival melanin pigmentation in maxillary anterior region were selected with inclusion criteria of an age

group between 18-50 years, systemically and periodontally healthy subjects and subjects having bilateral melanin pigmentation in the maxillary anterior region evaluated as either moderate or heavy clinical pigmentation according to the criteria given by Dummett (DOPI), 1964.65. The exclusion criteria were tobacco consumption in any form, low lip line, thin gingival biotype⁽¹¹⁾ or pregnant and lactating women.

Presurgical Therapy: The initial preparatory phase consisted of implementation of specific oral hygiene regime along with scaling and polishing. Following phase-I therapy and achievement of satisfied oral hygiene, written informed consent was signed by all subjects with bilateral gingival melanin pigmentation participating in this study. The selected (maxillary right anterior and maxillary left anterior) sites were assigned randomly (by using a coin-toss randomization) into Cryosurgery group and Electrosurgery group.

After the evaluation of phase-I therapy the following clinical parameters were recorded: Gingival Index,⁽¹²⁾ Dummett Oral Pigmentation Index (DOPI)⁽¹³⁾ and Gingival Wound Healing Index.⁽¹⁴⁾

Procedure: An intraoral antiseptis was ensured with a pre procedural rinse of 0.2% chlorhexidine gluconate, and povidone-iodine solution was used to ensure extraoral antiseptis.

Cryosurgery Technique: In the first step, surgical site was isolated using suction and cotton rolls; then melanin pigmented areas were dried by air spray. Local anesthesia was not required since the removal of pigmented tissue was by deep-freezing method. Normal saline was applied to gingiva. Nitrous oxide (with the temperature of -750C) was applied using a bevel edge dermprobe D-8 L-15 and D-5 L-15. Tissue was frozen for three cycles of 20 seconds & then, surgical areas were covered with a periodontal dressing. After 1week, all clinical parameters were recorded and above mentioned procedure was repeated on pigmented areas which were left, if any, during the procedure that was performed at the 1st time.

Electrosurgery Technique: Local anesthetic solution was administered in form of infiltration at the site to be treated by electrosurgery. Ablation of the pigmented tissue was carried out by means of loop electrode of the electrosurgery unit under standard protective measures. It was used in a light brushing strokes, tip was kept in motion all the time to avoid excessive heat buildup and destruction of the tissues. Remnants of ablated tissue were removed using sterile gauze dampened with saline. Surgical area was covered with a periodontal dressing.

Postoperative care: Post-surgically, mechanical maintenance of oral hygiene was avoided for 1 week at the surgical sites. Oral hygiene was maintained by using

0.2% chlorhexidine solution for 1 minute twice a day for 7 days. Removal of periodontal dressing was done after 7 days and subjects were advised to resume manual oral hygiene measures. Subjects were assessed at baseline, 1 week, 1, 3, 6 and 9 months for Gingival Index,⁽¹²⁾ DOPI,⁽¹³⁾ Gingival Wound Healing Index.⁽¹⁴⁾

Statistical Analysis: Data was analyzed using Wilcoxon signed-rank test for intragroup comparison of Gingival Index & DOPI. Mann Whitney U test for intergroup comparison of Gingival Index & DOPI. Chi square test for intergroup comparison of Gingival Wound Healing Index. The software used was SPSS (statistical package for social science).

Case 1: Using Cryosurgery

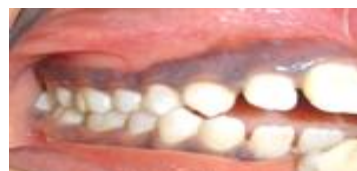

Fig. 1: Pre-Operative

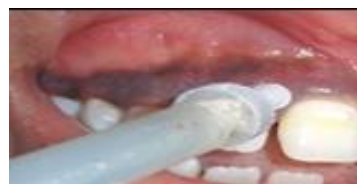

Fig. 2: Freezing probe tip

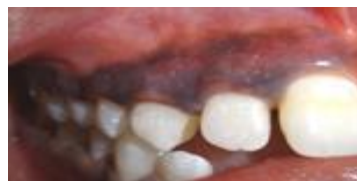

Fig. 3: Immediate postoperative

Using Electrosurgery

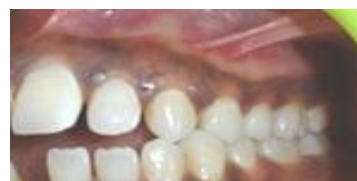

Fig. 4: Preoperative view

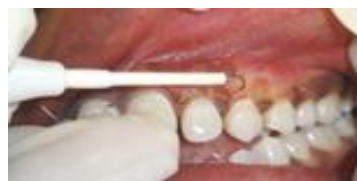

Fig. 5: Abrasion with loop Electrode

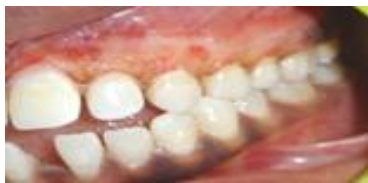

Fig. 6: Immediate postoperative

Right Side using Cryosurgery and Left Side using Electrosurgery

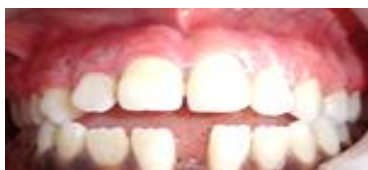

Fig. 7: 1 Week Postoperative

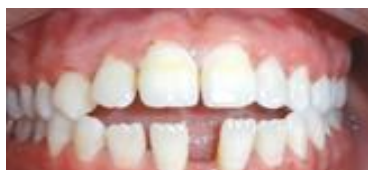

Fig. 8: 1 Month Postoperative

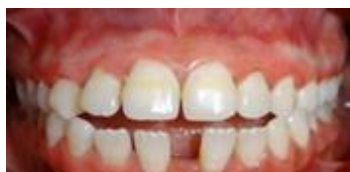

Fig. 9: 3 Months Postoperative

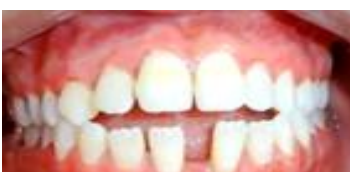

Fig. 10: 6 Months Postoperative

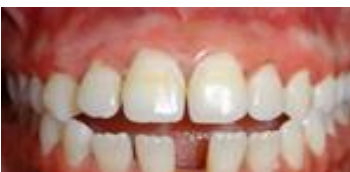

Fig. 11: 9 Months Postoperative

Case II
Right Side using Cryosurgery and Left Side using Electrosurgery

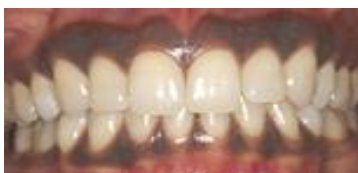

Fig. 12: Preoperative

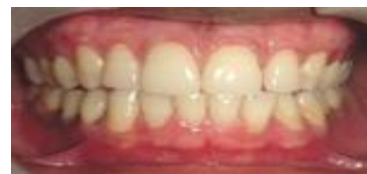

Fig. 13: 1 Week Postoperative

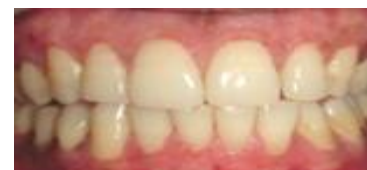

Fig. 14: 1 Month Postoperative

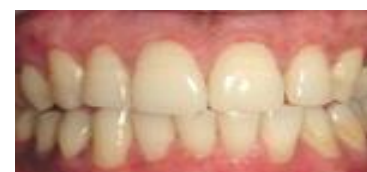

Fig. 15: 3 Months postoperative

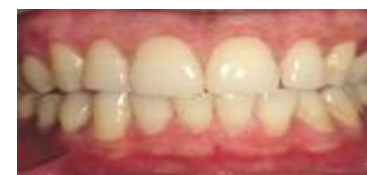

Fig. 16: 6 Months postoperative

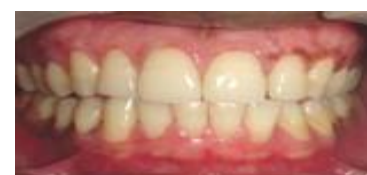

Fig. 17: 9 Months postoperative

Results

On comparison between the Cryosurgery and Electrosurgery groups, there was a statistically significant increase in gingival index at one week interval. Post-surgically at 1 month, 3 months, 6 months and 9 months interval, gingival index score remained same as that of baseline which was statistically not significant. The DOPI between Cryosurgery and Electrosurgery group at 1 week, DOPI reduction was more in Electrosurgery group than the Cryosurgery group. However, at 1 month and 3 months, there was no significant difference in between the groups. Also, at 6 months and 9 months interval, there was statistically highly significant difference in between the groups because of recurrence of pigmentation in Electrosurgery group. The gingival wound healing index between Cryosurgery group and Electrosurgery group at 1 week interval, Cryosurgery group showed higher Gingival

wound healing index which was statistically highly significant with P-value of $p < 0.0001$.

Table 1: Comparison of gingival index (GI) at different time intervals in cryosurgery group

Gingival index	Cryosurgery (n=30)		Wilcoxon Z Value	P-value
	Mean	SD		
Baseline - 1 Week	0 3	0 0	5.48	<0.0001
Baseline - 1 Month	0 0	0 0	0	>0.05
Baseline - 3 Months	0 0	0 0	0	>0.05
Baseline - 6 Months	0 0	0 0	0	>0.05
Baseline - 9 Months	0 0	0 0	0	>0.05

Table 2: Comparison of gingival Index (GI) at different time intervals in electro surgery group

Gingival index	Gingival index (n=30)		Wilcoxon Z Value	P-value
	Mean	SD		
Baseline - 1 Week	0 1	0 0	4.78	<0.0001
Baseline - 1 Month	0 0	0 0	0	>0.05
Baseline - 3 Months	0 0	0 0	0	>0.05
Baseline - 6 Months	0 0	0 0	0	>0.05
Baseline - 9 Months	0 0	0 0	0	>0.05

Table 3: Comparison of gingival index score between cryosurgery group and electrosurgery group at different time intervals

Gingival index	Cryosurgery (n=30)		Electrosurgery (n=30)		MW test Z Value	P Value
	Mean	SD	Mean	SD		
1 Week	3	0	1	0	7.68	<0.0001
1 Month	0	0	0	0	0	>0.05
3 Months	0	0	0	0	0	>0.05
6 Months	0	0	0	0	0	>0.05
9 Months	0	0	0	0	0	>0.05

Table 4: Comparison of Dummert oral pigmentation index (DOPI) at different time intervals in cryosurgery group

DOPI	DOPI (n=30)		Wilcoxon Z Value	P-value
	Mean	SD		
Baseline - 1 Week	2.17 0.32	0.555 0.407	5.48	<0.0001
Baseline - 1 Month	2.17 0	0.555 0	5.48	<0.0001
Baseline - 3 Months	2.17 0	0.555 0	4.58	<0.0001
Baseline - 6 Months	2.17 0	0.555 0	5.01	<0.0001
Baseline - 9 Months	2.17 0.02	0.555 0.076	4.93	<0.0001

Table 5: Comparison of Dummert oral pigmentation index (DOPI) at different time intervals in electrosurgery group

DOPI	DOPI (n=30)		Wilcoxon Z Value	P Value
	Mean	SD		
Baseline - 1 Week	2.26 0	0.451 0	5.48	<0.0001
Baseline - 1 Month	2.26 0	0.451 0	5.48	<0.0001
Baseline - 3 Months	2.26 0.01	0.451 0.055	4.95	<0.0001
Baseline - 6 Months	2.26 0.21	0.451 0.225	4.86	<0.0001
Baseline - 9 Months	2.26 0.33	0.451 0.250	4.87	<0.0001

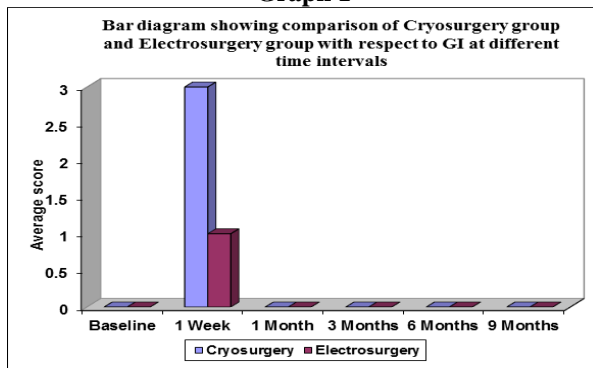
Table 6: Comparison of DOPI score between cryosurgery and electrosurgery group at different time intervals

Time	Group	Mean	SD	P-value
Baseline - 1 Week	Cryosurgery Group	0.32	0.407	<0.0001
	Electrosurgery Group	0	0	
Baseline - 1 Month	Cryosurgery Group	0	0	>0.05
	Electrosurgery Group	0	0	
Baseline - 3 Months	Cryosurgery Group	0	0	>0.05
	Electrosurgery Group	0.01	0.055	
Baseline - 6 Months	Cryosurgery Group	0	0	<0.0001
	Electrosurgery Group	0.21	0.2225	
Baseline - 9 Months	Cryosurgery Group	0.02	0.76	<0.0001
	Electrosurgery Group	0.33	0.250	

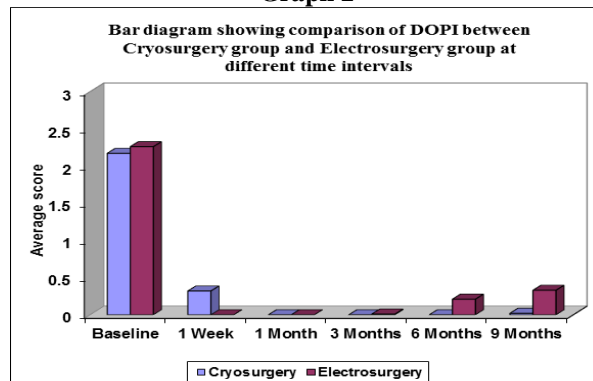
Table 7: Comparison of gingival wound healing index between cryosurgery group and electrosurgery group at different time intervals

Time	Cryosurgery	Electrosurgery	Total no. of patients	Chi-square	P-value
Baseline	A	A	30	0	>0.05
1 Week	C	B	30	60	<0.0001
1 Month	A	A	30	0	>0.05
3 Months	A	A	30	0	>0.05
6 Months	A	A	30	0	>0.05
9 Months	A	A	30	0	>0.05

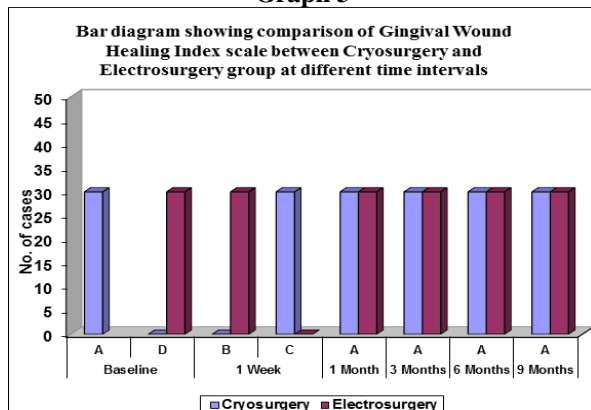
Graph 1



Graph 2



Graph 3



Discussion

In Cryosurgery group, mean gingival index at baseline was 0. One week post-surgically, the gingival index increased to 3 which was statistically highly significant with p-value of $p < 0.0001$. This is in accordance with Tal H (1987)⁽¹⁵⁾ where the frozen site thawed spontaneously within one min and mild erythema was developed. After one week, superficial necrosis became apparent and a whitish slough separated from the underlying tissue, leaving a clean granulating surface. After 2 weeks, the treated site was covered by the epithelium. Keratinization was completed after 3 weeks which did not present clinical pigmentation. Hence, post-surgically at 1 month, 3 months, 6 months and 9 months interval, gingival index score remained 0, same as that of the baseline because of subject maintenance of good oral hygiene which was statistically not significant with p-value of $p > 0.05$ (Table 1).

In Electrosurgery group, mean gingival index at baseline was 0. 1 week post-surgically, the gingival index increased to 1, showing an increase of 1 which was statistically highly significant with p-value of $p < 0.0001$ (Table 2). Post-surgically at 1 month, 3 months, 6 months and 9 months intervals, gingival index score remained 0, as same as that of the baseline which was statistically not significant with P-value of $p > 0$ (Table 3). This is in agreement with Schneider & Zari (1974)⁽¹⁶⁾ where they have found signs of inflammation evident clinically and consisted of redness and swelling through the 4-7 days period. These investigators speculated that the delay in healing of Electrosurgery wounds may be due to a delay in the formation of a fibrin clot. Epithelial migration was observed at 16 hours. There was always a vital connective tissue base beneath the migrating epithelium. Migration seemed to cease between 4-7 days when the epithelial edges were observed to be in contact.

In the present study, there was statistically significant increase in gingival index in both the groups at 1 week but reduced to the value, same as that of the baseline at 1 month and remained same as that of baseline throughout the study of 9 months.

In Cryosurgery group, the mean DOPI at baseline was 2.17 ± 0.56 . At 1 week post-surgically, the DOPI

reduced to 0.32 ± 0.40 , showing the reduction of 1.85 ± 0.148 which was statistically highly significant with p-value of $p < 0.0001$ (Table 4). At 1 week follow-up, it was observed that in some areas, residual pigments were present (mean DOPI 0.32 ± 0.40), it was because of areas unexposed to the cold temperature. So, second course of cryosurgical treatment was done after 1 week of recording the clinical parameter. This is in accordance with the study by Chin – Jyh Yeh⁽¹⁷⁾ who suggested a second course of cryosurgical treatment after 1 week to remove any residual pigments.

Post-surgically at 1 month, 3 months and 6 months interval, DOPI score remained 0 compared to baseline, with the reduction of 2.17 ± 0.56 which was statistically highly significant with P value of $p < 0.0001$ (Table 4). These were in accordance with the study of Narsimha Rao et al. (2015)⁽¹⁸⁾ in which they have mentioned that pigmentation score was reduced to 0 at 1 month and the same was maintained throughout the study period of 9 months with no clinically expressive recurrence being observed, and this difference of score from baseline to 1, 3, 6 and 9 months were statistically significant. The possible reason for this non recurrence of pigmentation was explained by Bandish LK et al. (1985),⁽¹⁹⁾ Tal H (1987).⁽¹⁵⁾ According to them, it may be speculated that either the "migration" of melanocytes did not occur during the follow-up period, or the melanocytes that migrated were in an inactive state due to the inhibition of their tyrosinase system. They were thus, unable to produce melanin pigmentation during the observation period which is 9 months in our study. In this study, at the end of nine months, two cases reported with limited areas of repigmentation but without any esthetic significance that is even not of any statistical significance.

In Electrosurgery group, mean DOPI at baseline was 2.26 ± 0.46 . Post-surgery, after 1 week & 1 month, the DOPI was reduced to 0, showing reduction of 2.26 ± 0.46 which was statistically highly significant with P value of $p < 0.0001$ (Table 5, Graph 3). This is in accordance with the study by Jagjit Singh Khurana (2012)⁽²⁰⁾ & Gupta et al (2014)⁽²¹⁾ where they reported no pigmentation post-surgically after 1 month.

Postsurgically at 3 months, DOPI score was 0.01 ± 0.05 , showing reduction of 2.25 ± 0.39 compared with baseline which was statistically highly significant with P-value of $p < 0.0001$ (Table 5). There were limited areas of repigmentation in one subject but without any esthetic significance. This is in accordance with the study by Sucheta A et al (2014),⁽²²⁾ in which the repigmentation was assessed at the end of 3 months with the mean DOPI score of 0.8 ± 0.447 at the end of three months. Repigmentation refers to the clinical reappearance of melanin pigment following a period of clinical depigmentation. The one of the possible mechanism suggested for the spontaneous repigmentation is that the melanocytes from the normal skin proliferate and migrate into the depigmented areas.

Mean DOPI at baseline was 2.26 ± 0.46 . 6 months post-surgery, the DOPI score reduced to 0.21 ± 0.23 , showing reduction of 2.05 ± 0.23 which was statistically highly significant with P-value of $p < 0.0001$ (Table 5). This was in accordance with the study of Gupta et al (2014)⁽²¹⁾ in which they have mentioned that the mechanism of repigmentation is not understood and there is little information on the behavior of melanocytes after surgical injury, but according to migration theory, active melanocytes from the adjacent pigmented tissues migrate to treated areas, causing repigmentation. Repigmentation may also be attributed to the melanocytes which are left during surgery, as stated by Ginwalla et al (1966).⁽²³⁾ These may become activated and start synthesizing melanin.

Mean DOPI at baseline was 2.26 ± 0.46 . 9 months post-surgery, the DOPI score reduced to 0.33 ± 0.26 , showing reduction of 1.93 ± 0.21 which was statistically highly significant with P-value of $p < 0.0001$ (Table 5). According to Oringers (1975)⁽²⁴⁾ "**Exploding cell theory**", it is predicted that the electrical energy leads to molecular disintegration of melanin cells present in basal and suprabasal cell layers of operated and surrounding sites. Thus, Electrosurgery has an influence in retarding migration of melanin cells from the locally situated cells, which were detected clinically to be removed.

The intergroup comparison between Cryosurgery and Electrosurgery shows that at 1 week, the mean value of DOPI of Cryosurgery was 0.32 ± 0.41 and that of Electrosurgery was 0 with the difference of 0.32 ± 0.41 which was statistically highly significant with P-value of $p < 0.0001$ (Table 6, Graph 2). This statistical difference may be due to the areas unexposed to cold temperature, resulting in residual pigments so second course of cryosurgical treatment was done after 1 week. This is in accordance with the study by Chin – Jyh Yeh⁽¹⁷⁾ who suggested a second course of cryosurgical treatment after 1 week to remove any residual pigments.

At 1 month, it was found that the mean value of DOPI of Cryosurgery was 0 and that of Electrosurgery was 0 which was not significant with P-value of $p > 0.05$ (Table 6, Graph 2).

At 3 months, the mean value of Cryosurgery was 0 and Electrosurgery was 0.01 ± 0.055 with the difference of 0.01 ± 0.055 . Hence there was difference at 3 months which was not significant statistically with P-value of $p > 0.05$ (Table 6, Graph 2). At the end of three months, one case reported with limited areas of repigmentation which was statistically not significant and without any esthetic significance.

At 6 months, it was found that the mean value of DOPI of Cryosurgery was 0 and that of Electrosurgery was 0.21 ± 0.23 with the difference of 0.21 ± 0.23 which was highly significant with P-value of $p < 0.0001$ (Table 6, Graph 2). In Electrosurgery group, 16 subjects showed mild recurrence of pigmentation. This statistical difference is due to the recurrence of pigment without any esthetic significance in Electrosurgery group.

At 9 months, it was found that the mean value of DOPI in Cryosurgery group was 0.02 ± 0.076 and that of Electrosurgery was 0.33 ± 0.250 with the difference of 0.31 ± 0.51 which was highly significant with P-value of $p < 0.0001$ (Table 6, Graph 2). The Cryosurgery group showed mild recurrence of pigmentation in two cases but without any esthetic significance. In Electrosurgery group, 24 subjects showed mild recurrence of pigmentation without any esthetic significance at the end of 9 month follow period. According to Jagjit Singh Khurana (2012)⁽²⁰⁾, the possible reasons for repigmentation at 3 months, 6 months & 9 months in area where Electrosurgery was done may be due to:

- Presence of remaining melanocytes at the site during depigmentation procedure because of minimal depth of removal in order to avoid thermal necrosis of bone.
- Faster migration of melanocytes at the area of depigmentation.

This is the first kind of study where the Cryosurgery and Electrosurgery techniques were compared for gingival depigmentation. So there is no literature available for direct comparison of DOPI results of our study.

In present study, in Cryosurgery group, the Gingival wound healing index at baseline was **A** postoperatively after 1 week it increased to **C** in all 30 subjects hence showing statistically increase in Gingival wound healing index at the end of one week post-surgery. Clinically, one week post-surgery, the areas treated with Cryosurgery showed ulcerations. This was in accordance with Tal H (1987)⁽¹⁵⁾ where the frozen site thawed spontaneously within one min and mild erythema was developed. After one week, superficial necrosis became apparent and a whitish slough separated from the underlying tissue leaving a clean granulating surface. After 2 weeks, the treated site was covered by epithelium. Keratinization was complete after 3 weeks. However, at one month postoperatively, Gingival wound healing index was found to be same as that of baseline and remained same throughout the study period.

In Electrosurgery group, the Gingival Wound Healing Index at baseline was **A** postoperatively after 1 week it increased to **B** in all 30 subjects hence showing statistically increase in Gingival wound healing index at the end of one week post-surgery. Clinically, one week post-surgery the areas treated with Electrosurgery showed incomplete or partial epithelialization. This was in accordance with Schneider, Zari (1974)⁽¹⁶⁾ as according to them, signs of inflammation were evident clinically and consisted of redness and swelling through the 4-7 day period. Two weeks postoperatively, the gingival tissues showed no signs of inflammation. However, at one month postoperatively, Gingival wound healing index was found to be same as that of baseline and remained same throughout the study period.

On comparison of Gingival wound healing index between Cryosurgery group and Electrosurgery group at

1 week interval, Cryosurgery group showed higher Gingival wound healing index which was statistically highly significant with P-value of $p < 0.0001$.

(Table 7, Graph 3). This is in accordance with Tal H (1987)⁽¹⁵⁾ and Schneider, Zaki (1974).⁽¹⁶⁾ According to Tal H (1987)⁽¹⁵⁾, the frozen site thawed spontaneously within one min and mild erythema was developed. After one week, superficial necrosis became apparent and a whitish slough separated from the underlying tissue leaving a clean granulating surface. According to Schneider, Zaki et al (1974)⁽¹⁶⁾ signs of inflammation were evident clinically and consisted of redness and swelling through the 4-7 day period. Two weeks postoperatively, the gingival tissues showed no signs of inflammation. Post-surgically at 1 month, 3 months, 6 months and 9 months interval, the comparison of Gingival Wound Healing Index between Cryosurgery and Electrosurgery was not statistically significant with P-value of $p > 0.05$ (Table 7, Graph 3).

Conclusions

Within the limits of the study, it can be concluded that both Cryosurgery and Electrosurgery techniques yielded statistically significant reduction in gingival pigmentation when compared to respective baseline values. But on follow up, subjects treated with Electrosurgery techniques started showing recurrence of pigments from the 3rd month onwards and 24 subjects showed recurrence at the end of 9 months with the statistical significance but without any esthetic significance. However, results of Cryosurgery were stable even up to 9 months except for 2 subjects where they showed very mild recurrences of pigmentation without any statistical and esthetic significance. The gingival depigmentation which was achieved by using the Cryosurgery was more acceptable (Local anesthesia was not required) and suitable as compared to the Electrosurgery method.

References

1. Goldstein R. "Change your smile." 3rd Ed. Quintessence. (1997),1-36.
2. Morley J. "The role of cosmetic dentistry in restoring a youthful appearance." J Am Dent Assoc (1999) 130,1166-72.
3. Jones J. "A photometric study of the color of the healthy gingiva." J Periodontol (1977) 48(1),21-26.
4. Tal H, Oegiesser D, Tal M. "Gingival depigmentation by erbium: YAG laser: clinical observations and patient responses." J Periodontol (2003) 74(11),1660-7.
5. Freiman A, Bouganim N. "History of cryotherapy." Dermatol Online J (2005) 11(2),9.
6. Deepa. D, Chawla. A, Srivastava. P. "Gingival depigmentation by scalpel, diode laser and electrosurgery - A case report." Indian J Dent Sci (2013) 5(1),62-64.
7. Ahmed SK, George JP, Prabhuji ML. "Cryosurgical treatment of gingival melanin pigmentation - A 30-month follow-up case report." Clinic Adv Periodontics (2012) 2,73-78.
8. Shirazi AR, Taghavi AM, Khorakian F. "Treatment of gingival physiologic pigmentation in adolescent using

9. cryosurgery technique with liquid nitrogen: one year follow up." J Mash Dent Sch (2010) 33(4),331-42.
9. Kanakamedala AK, Geetha A, Ramakrishnan T, Emadi P. "Management of gingival hyperpigmentation by the surgical scalpel technique - Report of three cases." J Clin Diag Res (2010) 4,2341-6.
10. Kenneth L. Kalkwarf et al. "Healing of electrosurgical incisions in gingiva: Early histologic observations in adult men." J Prosthet Dent (1981) 86(6),662-72.
11. Rahmati S, Darijani M, Nourelahi M. "Comparison of surgical blade and cryosurgery with liquid nitrogen techniques in treatment of physiologic gingival pigmentation: Short term results." J Dent Shiraz Univ Med Sci (2014)15(4),161-166.
12. Clifton O, Dummet, Gupta O. "Estimating the epidemiology of oral pigmentation." J Natl Med Assoc (1964) 56(5),419-420.
13. Loe H, Silness J. "Periodontal disease in pregnancy I: Prevalence and severity." Acta Odontol Scand (1963) 21,533-51.
14. Ishii S, Aoki A, Kawashima Y, Watanabe H, Ishikawa I. "Application of an Er:YAG laser to remove gingival melanin hyperpigmentation: treatment procedure and clinical evaluation." J Jpn Soc Laser Dent (2002) 13,89-96.
15. Tal H. "A novel cryosurgical technique for gingival depigmentation." J Am Acad Dermatol (1987) 24,292-293.
16. Schneider A, Zari A. "Gingival wound healing following experimental electrosurgery: A light microscopic and macroscopic investigation." J Periodontol (1974) 45(7),459-67.
17. Yeh CJ. "Cryosurgical treatment of melanin-pigmented gingiva." Oral Surg Oral Med Oral Pathol Oral Radiol Endod (1998) 86(6),660-663.
18. Rao PV, Penmetsal GS, Dwarakanath CD.: Gingival depigmentation by cryosurgery and laser application - A comparative clinical study." Br J Med Med Res (2015) 5(11),1403-12.
19. Bandish LK. "Pertinent considerations in oral pigmentation." Brit Dent J (1985) 158(5),158.
20. Khurana JS, Khurana A, Mathur S, et al. "Depigmentation to repigmentation - A comparison of two different techniques: A case series." Indian J Stomatol (2012) 3(2),135-38.
21. Gupta G, Ashish K, Khatri M, Puri K, Jain D, Bansal M. "Comparison of two different depigmentation techniques." J Indian Soc Periodontol (2014) 18(6),705-709.
22. Sucheta A, Prasad R, Laksmi P, Apoorva SM, Bhat D, Bhopale D. "Depigmentation: To beautify a smile." Annals Dent Res (2014) 3(2),52-59.
23. Ginwalla TM, Gomes BC, Varma BR. "Surgical removal of gingival pigmentation." J Indian Dent Assoc (1966) 38(6),147-50.
24. Oringer MJ. "Electrosurgery in dentistry." 2nd Ed. Philadelphia: WB Saunders (1975),32-46.