



Original Research Article

Evaluation of patient perception and intraoperative bleeding in labial frenectomy: A comparison of diode laser and conventional scalpel techniques

Mutthineni Ramesh Babu^{1*}, Arpita Paul¹, Amula Vinay Sagar¹, Mandem Harshini Sai¹

¹Dept. of Periodontics, Mamata Dental College, Khammam, Telangana, India



ARTICLE INFO

Article history:

Received 01-05-2024

Accepted 21-06-2024

Available online 10-07-2024

Keywords:

Frenectomy

Diode laser

Scalpel

ABSTRACT

Background: High frenal attachments are abnormalities corrected by surgical procedure called frenectomies. The scalpel technique is associated with pain, bleeding and postoperative discomfort. To overcome these shortcomings, in the recent times, diode lasers are gaining popularity due to less bleeding, pain during the procedure, healing outcome, and need for analgesics

Aim: To compare the bleeding during the procedure and postoperative pain in patients requiring labial frenectomy using conventional scalpel and diode laser techniques.

Materials and Methods: Twenty patients with high labial frenum attachment requiring frenectomy were included in this study. Patients were randomly divided into Group A: scalpel group and Group B: diode laser group. Pain assessment using VAS, severity of intraoperative bleeding and number of analgesics used were recorded

Results & Observation: The analysis showed that VAS score for pain was significantly lower in the laser group as compared to the scalpel group Bleeding was mild in laser group, where as in scalpel group showed moderate or severe bleeding scores Post operative use of analgesics was more in scalpel group than laser group

Conclusion: Laser was found to be an effective alternate to scalpel in performing frenectomy procedures, more importantly it showed less bleeding, less pain perception and more patient acceptance during the procedure.

This is an Open Access (OA) journal, and articles are distributed under the terms of the [Creative Commons Attribution-NonCommercial-ShareAlike 4.0 License](https://creativecommons.org/licenses/by/4.0/), which allows others to remix, tweak, and build upon the work non-commercially, as long as appropriate credit is given and the new creations are licensed under the identical terms.

For reprints contact: reprint@ipinnovative.com

1. Introduction

A frenectomy involves the complete removal of the frenulum, including its attachments to the underlying alveolar process. Abnormalities in the size and location of the frenulum can cause functional and aesthetic issues, necessitating surgical excision.¹ The most common sites for frenum abnormalities are the maxillary and mandibular central incisors, as well as the canine and premolar areas.^{2,3} These abnormalities can result in gingival recession, development of midline diastema, and speech

difficulties. The blanch test is the most commonly used method for diagnosing high frenum attachment. It involves applying tension to the frenum by pulling it and visually detecting any movement of the papillary tip or blanching produced. Frenectomy can be performed using conventional techniques, electrosurgery, or soft tissue lasers. Patients who undergo conventional frenectomy procedures with a scalpel often experience postsurgical pain and discomfort, which is exacerbated when sutures come into contact with food. A viable alternative is a laser-assisted frenectomy, which can reduce these postoperative issues. Lasers, such as the neodymium doped:yttrium aluminum

* Corresponding author.

E-mail address: rameshbabu297@gmail.com (M. R. Babu).

garnet (Nd:YAG), carbon dioxide (CO₂), and erbium-doped (Er):YAG lasers, enable minimally invasive dentistry for soft tissue procedures.⁴ Diode lasers are semiconductors indicated for soft tissue surgeries, as their wavelength closely matches the absorption coefficient of pigmented tissues containing hemoglobin, melanin, and collagen chromophores.⁵

Hence, this study was conducted with the aim to compare scalpel and diode laser-assisted frenectomy for the amount of intraoperative bleeding, post operative pain and need for analgesics. These clinical parameters were studied as they determine the ease for the patient during the procedure and their acceptance for the method.

2. Materials and Methods

The present in-vivo study was conducted in the Department of Periodontics, Mamata Dental College and Hospital, Khammam, Telangana from October 2022 to March 2023. Ethical clearance (EC/IRB: MDC-KT-) was obtained from Ethical Review Committee and Institutional Review Board of Mamata Dental College and Hospital, Khammam, Telangana.

For this study, twenty patients scheduled for frenectomy due to a high frenum in the maxillary anterior region were selected. Patients were randomly divided into two groups randomly, and written consent was obtained from each patient/guardian.

1. Group A: Ten patients selected for the conventional scalpel technique.
2. Group B: Ten patients were taken for the diode laser technique.

The entire procedure was explained and informed consent was taken from patients. A single operator performed all the frenectomies.

2.1. Conventional scalpel technique

After thorough clinical and hematological examinations, a frenectomy was performed using the conventional approach. A hemostat was used to grasp the frenum and was inserted into the depth of the vestibule. Incisions were then made on both the upper and lower surfaces of the hemostat. A blunt dissection was carried out down to the bone to release the fibrous attachment. The edges of diamond-shaped wound were sutured with interrupted sutures (nonresorbable 3-0 braided silk). The area was covered with a periodontal pack. After surgery, the patients were advised to take soft foods for 1 week. Post 1 week, sutures and Coe-pak were removed. Tablet Ibuprofen 400 mg + paracetamol TID and tablet amoxicillin 500 mg (Novamox, Cipla Limited, India) TID for 5 days were prescribed.

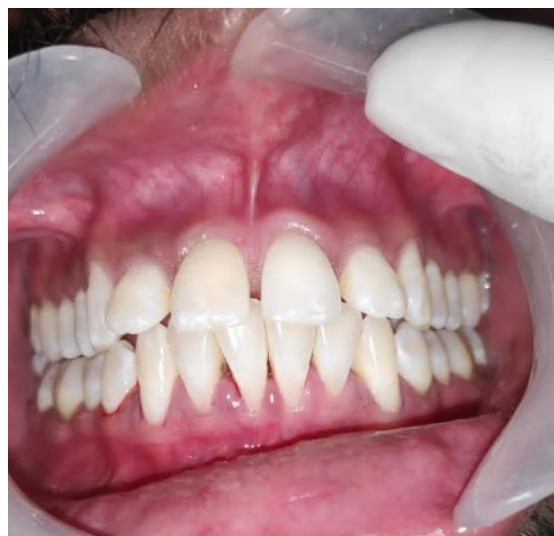

Figure 1: Pre operative

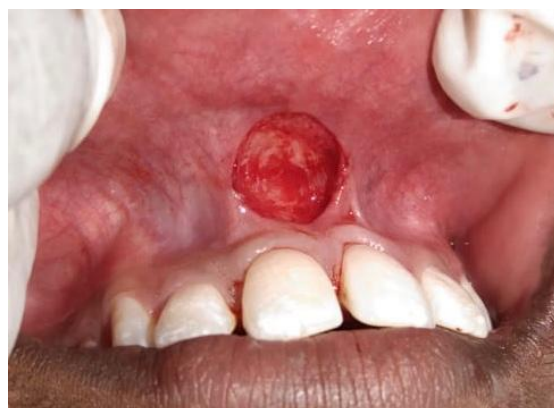

Figure 2: Intra operative

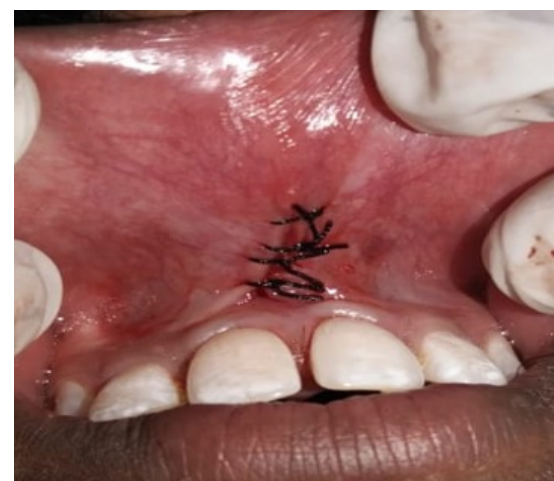

Figure 3: Immediate post operative

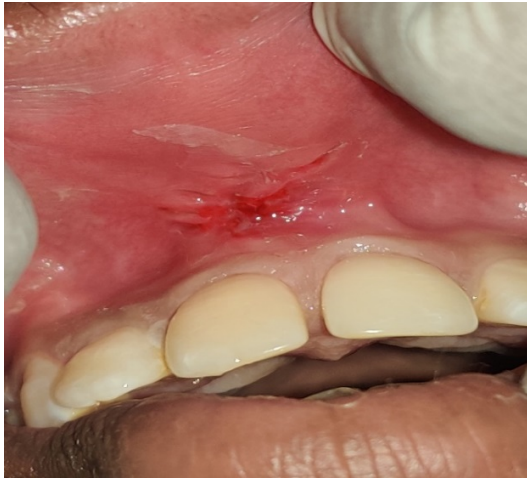


Figure 4: 7 day post operative

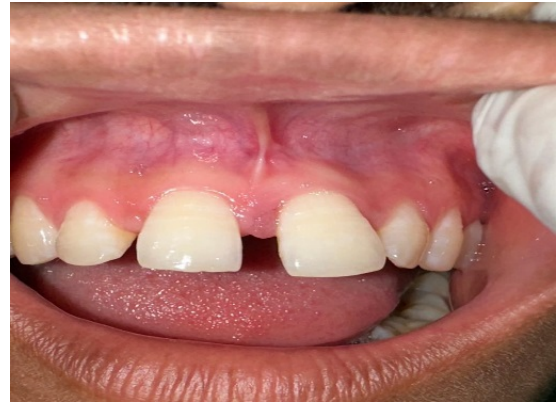

Figure 6: Pre operative

2.2. Laser technique

For the laser group, diode laser with 808nm wavelength was used. A 400- μ m fiber tip was used at power setting of 1.5 W in contact mode and moved with a paint brush stroke, from the base to the apex of the frenum, thereby excising it. Sutures were not used in this group. Similar postoperative instructions were delivered to the patients of both the groups. The use of analgesic containing Ibuprofen 400 mg + paracetamol was left to the patient's discretion and to be taken as and when needed. Each of the patients was recalled 3 months after the surgery to determine the healing outcome.

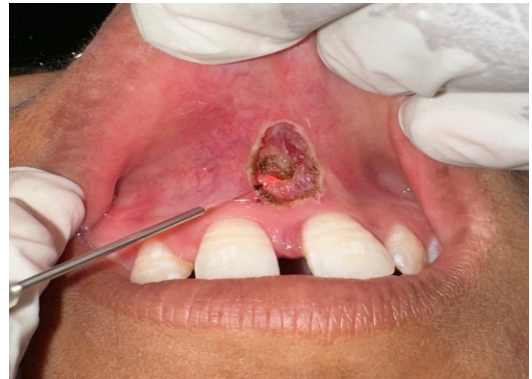

Figure 7: Intra operative



Figure 5: Diode laser

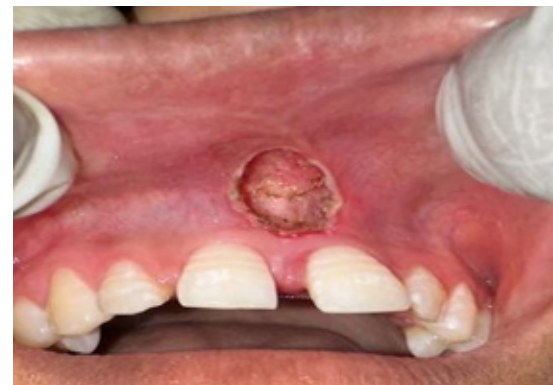

Figure 8: Immediate post operative

2.3. Scoring of pain

The pain experienced by each patient was rated using the Visual Analog Scale (VAS). Patients were asked to place a vertical mark on a 10-cm VAS, with the left end indicating "no pain" and the right end indicating "worst pain imaginable."⁶

2.4. Severity of bleeding

The operator recorded the severity of bleeding for each patient during the procedure, using a scoring system: 1 for none, 2 for mild, 3 for moderate, and 4 for severe bleeding.⁷

2.5. Number of analgesics

During the recall appointment, each patient was asked about the number of analgesics they used during the healing phase.

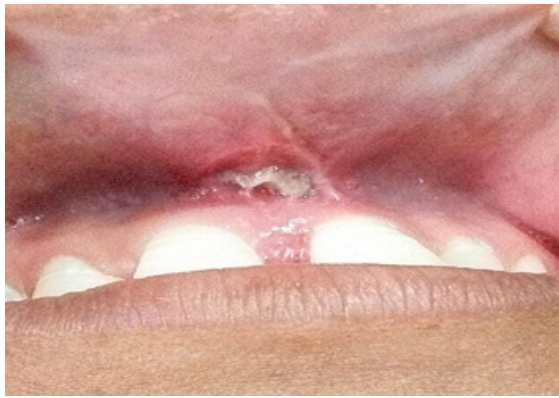

Figure 9: 7 day post operative

2.6. Statistical analysis

Statistical analysis was conducted using the Statistical Package for the Social Sciences (SPSS) software version 19 (IBM Corporation, Armonk, New York, USA). Due to the non-normal distribution of the data, nonparametric tests were employed. For intergroup comparisons, the Mann–Whitney U-test was used. Results were presented as median and range, with $P < 0.05$ considered statistically significant.

3. Results

Median and range were used for each parameter to compare both the groups. Comparison of the median and range for VAS score, intraoperative bleeding, and number of analgesics used is summarized in Table 1. The analysis revealed a significant difference in the Visual Analog Scale (VAS) pain scores between the laser group and the scalpel group, with the laser group experiencing significantly lower pain scores compared to the scalpel group ($P = 0.016$). Intraoperative bleeding scores were found to be significantly higher for Group A than Group B ($P = 0.019$). Furthermore, the number of analgesics used by patients in Group A was significantly higher ($P = 0.151$) than by patients in Group B.

Table 1: Mean comparison of pain score between groups

Pain	Test group	Control group
Mean	1.40	3.40
SD	0.89443	1.14018
Median	2	3
Range	0-2	2-5
Test statistic		-2.378
P value		0.016*

Mann Whitney U test; $p \leq 0.05$ considered statistically significant

Table 2: Distribution and comparison of bleeding severity between groups

Bleeding Severity	Test group		Control group		Chi-Square value	P value
	n	%	n	%		
None-0	1	20	0	0	10.000	0.019*
Mild-1	4	80	0	0		
Moderate -2	0	0	4	80		
Severe -3	0	0	1	20		

Table 3: Mean comparison of No. of analgesics between groups

Pain	Test group	Control group
Mean	4.00	4.40
SD	5.04975	1.14018
Median	2	4
Range	1-3	3-6
Test statistic		-1.591
P value		0.151

Mann Whitney U test; $p \leq 0.05$ considered statistically significant

4. Discussion

Abnormalities in the size and position of the frenum can contribute to midline diastema, gingival recession, and speech difficulties. Addressing these conditions often necessitates the complete removal of the frenum attachment to the underlying alveolar process. Surgical scalpel techniques are commonly employed for frenectomy procedures.

Patients undergoing conventional frenectomy procedures with a scalpel frequently encounter postsurgical pain and discomfort, especially exacerbated by sutures coming into contact with food. A viable alternative is laser surgery, offering several advantages, including relatively bloodless surgery, wound sterilization, often eliminating the need for sutures, reduced surgical time, absence of periodontal dressing, and decreased postoperative pain and discomfort, leading to improved patient acceptance.⁸

The purpose of this study was to compare the laser and scalpel techniques for frenectomy procedures in terms of intraoperative bleeding, postoperative pain, and the number of analgesics used. These clinical parameters were chosen and compared because they are indicative of the procedural ease and patient acceptance of the technique.

Lasers such as Nd: YAG, Co2, and erbium: YAG had been used for frenectomy procedures. Among these, Co2 laser was the most frequently used one. In this study, a diode laser was utilized, which typically incorporates a combination of gallium, arsenide, and other elements such as aluminum and indium. The wavelength of this laser is feebly absorbed in water, but extremely absorbed in hemoglobin and other pigments. As diode laser is considered as an excellent soft tissue laser as it doesn't interact with dental hard tissues. Smaller size of units and lower financial costs are few other advantages.⁹

Abundant evidence confirms significantly reduced bleeding, especially in highly vascular oral tissues, with laser surgery. The laser technique offers some advantages, such as a relatively bloodless surgical and postsurgical event; the ability to precisely coagulate, vaporize, or cut tissue; sterilization of the wound site; minimal swelling and scarring; no suturing in most cases; little mechanical trauma; reduction of surgical time; decreased postsurgical pain; and high patient acceptance.^{10–12} In the present study, subjects treated with the DIODE laser had significantly relatively less bleeding and was easy to perform than conventional scalpel surgery

Kara et al,¹³ compared Nd: YAG laser to conventional scalpel surgery and reported that patients treated with laser reported higher levels of satisfaction, less postsurgical pain and discomfort. Haytac and Ozcelik¹⁴ compared 20 frenectomy procedures performed with Co2 laser to an equal number performed with conventional scalpel surgery and reported that patients treated with laser experienced less pain after 1st day and 7th day. In this study, it was observed that patients treated with the diode laser experienced less pain and discomfort when compared with those treated with scalpel. It has also been observed that the reduction in pain and discomfort levels from the 1st to 7th day is much more significant for the laser group. The increased pain perception associated with the scalpel frenectomy might be attributed to the fact that it is a more intrusive surgical procedure involving blood loss, wide surgical wound and suturing. Sutures can indeed contribute to postoperative discomfort as they can interfere with regular functions such as speech and eating. Conversely, the reduced pain and discomfort observed in the laser group may be attributed to the protein coagulum formed over the wound, which acts as a biological dressing and helps seal the ends of sensory nerves.^{15,16} Absence of any sutures post the laser procedure might have contributed to lesser discomfort levels.

Prior studies have consistently supported the notion that lasers result in reduced bleeding, minimal scarring, less postoperative pain, and fewer cases requiring suturing, along with quicker wound healing.^{17–20} Although the decision to use an analgesic was left to the patient's discretion, an observational study was done to analyze the use of analgesics in both the groups. The study revealed that laser group patients took less number of analgesics.

5. Conclusion

This clinical study suggests that diode lasers offer patients a better perception due to reduced operative time, pain, and bleeding compared to the scalpel method. Despite some drawbacks, the diode laser remains a reliable alternative as it is efficient, safe, and satisfactory for soft tissue surgeries like frenectomy. However, it is important to note potential drawbacks such as lateral heat damage, delayed wound healing, dependence on operator skill, and

higher cost. Further long-term studies with larger sample sizes are necessary to establish the superior efficacy of laser techniques over conventional scalpel methods for frenectomy procedures.

6. Source of Funding

None.

7. Conflict of Interest

None.

References

1. Takei HH, Azzi RA. Periodontal plastic and esthetic surgery. In: Newman M, Carranza F, editors. Carranza's Clinical Periodontology. London: W.B. Saunders; 2002. p. 870–1.
2. Whinston GJ. Frenectomy and mucobuccal fold resection used in periodontal therapy. *NY Dent J*. 1956;22:495.
3. Huang WJ, Creath CJ. The midline diastema: A review of its etiology and treatment. *Pediatr Dent*. 1995;17(3):171–9.
4. Devishree SK, Gujjari SK, Shubhashini PV. Frenectomy: A review with the reports of surgical techniques. *J Clin Diagn Res*. 2012;6(9):1587–92.
5. Butchibabu K, Koppolu P, Mishra A, Pandey R, Swapna LA, Uppada UK, et al. Evaluation of patient perceptions after labial frenectomy procedure: A comparison of diode laser and scalpel techniques. *Eur J Gen Dent*. 2014;3(2):129–33.
6. Kaur P, Dev YP, Kaushal S, Bhatia A, Vaid R, Sharma R, et al. Management of the upper labial frenum: A comparison of conventional surgical and lasers on the basis of visual analogue scale on patients perception. *J Periodontal Med Clin Pract*. 2014;1(1):38–46.
7. Kishore A, Kathariya R, Deshmukh V, Vaze S, Khalia N, Dandgaval R, et al. Effectiveness of Er: YAG and CO2 lasers in the management of gingival melanin hyperpigmentation. *Oral Health Dent Manag*. 2014;13(2):486–91.
8. Epstein SR. The frenectomy: a comparison of classic versus laser technique. *Pract Periodontics Aesthet Dent*. 1991;3(5):27–30.
9. Desiate A, Cantore S, Tullo D, Profeta G, Grassi FR, Ballini A, et al. 980 nm diode lasers in oral and facial practice: Current state of the science and art. *Int J Med Sci*. 2009;6(6):358–64.
10. Frame JW. Removal of oral soft tissue pathology with the CO2 laser. *J Oral Maxillofac Surg*. 1985;43(11):850–5.
11. Buell BR, Schuller DE. Comparison of tensile strength in CO2 laser and scalpel skin incisions. *Arch Otolaryngol*. 1983;109(7):465–7.
12. Kaur P, Dev YP, Kaushal S, Bhatia A, Vaid R, Sharma R, et al. Management of the upper labial frenum: A comparison of conventional surgical and lasers on the basis of visual analogue scale on patients perception. *J Periodontal Med Clin Pract*. 2014;1:38–46.
13. Kara C. Evaluation of patient perceptions of frenectomy: A comparison of Nd: YAG laser and conventional techniques. *Photomed Laser Surg*. 2008;26:147–52.
14. Haytac MC, Ozcelik O. Evaluation of patient perceptions after frenectomy operations: A comparison of carbon dioxide laser and scalpel techniques. *J Periodontol*. 2006;77(11):1815–9.
15. Fisher SE, Frame JW, Browne RM, Tranter RM. A comparative histological study of wound healing following CO2 laser and conventional surgical excision of canine buccal mucosa. *Arch Oral Biol*. 1983;28(4):287–91.
16. Fenner J, Martin W, Moseley H, Wheatley DJ. Shear strength of tissue bonds as a function of bonding temperature: a proposed mechanism for laser-assisted tissue welding. *Laser Med Sci*. 1992;7:39–43.
17. Schuller DE. Use of the laser in the oral cavity. *Otolaryngol Clin North Am*. 1990;23(1):31–42.


18. Pick RM, Pecaro BC. Use of the CO2 laser in soft tissue dental surgery. *Lasers Surg Med.* 1987;7(2):207–13.
19. Wigdor HA, Walsh JT, Featherstone JD, Visuri SR, Fried D, Waldvogel JL, et al. Lasers in dentistry. *Lasers Surg Med.* 1995;16(2):103–33.
20. Bader HI. Use of lasers in periodontics. *Dent Clin North Am.* 2000;44(4):779–91.

Arpita Paul, Professor and HOD

Amula Vinay Sagar, Post Graduate Trainee

Mandem Harshini Sai, Post Graduate Trainee

Author biography

Mutthineni Ramesh Babu, Professor  <https://orcid.org/0000-0001-6904-8385>

Cite this article: Babu MR, Paul A, Sagar AV, Sai MH. Evaluation of patient perception and intraoperative bleeding in labial frenectomy: A comparison of diode laser and conventional scalpel techniques. *IP Int J Periodontol Implantol* 2024;9(2):85-90.