



Original Research Article

Radiographic evaluation of hard tissue changes in open flap technique versus flapless technique for implant placement

Priyanka Kumari^{1*}, Manish Khatri¹, Mansi Bansal¹, MD. Rehan¹, Amit Prakash²

¹Dept. of Periodontology, Institute of Dental Studies & Technologies, Modinagar, Ghaziabad, Uttar Pradesh, India

²Dept. of Oral Pathology, Institute of Dental Studies & Technologies, Modinagar, Ghaziabad, Uttar Pradesh, India



ARTICLE INFO

Article history:

Received 10-02-2024

Accepted 11-03-2024

Available online 01-05-2024

Keywords:

Flapless implant

Open flap technique

CBCT

Crestal bone loss

ABSTRACT

Introduction: Open flap technique allows the clinician to directly visualize the alveolar bone and assess bone morphology of the ridge. However, this technique is relatively invasive and causes patient discomfort and marginal bone loss due to decreased supraperiosteal blood supply whereas the Flapless technique is one of the latest minimally invasive surgical methods of implant placement without the need to raise a mucoperiosteal flap to overcome the bone resorption process.

Aim: The present study was designed to evaluate the hard tissue changes in open flap technique versus flapless technique for implant placement at the different time interval.

Materials and Methods: Minimum thirty edentulous sites from Out Patient Department, Department of Periodontology (IDST) were randomly allocated to the following two groups by the flip of coin: Group I - Implant with open flap technique (fifteen sites) and Group II - Implant with flapless technique (fifteen sites). Patients were evaluated radiographically for crestal bone loss (mesial and distal) at Baseline (Immediately after implant placement), At the time of prosthetic loading and 3 months after prosthetic loading in both the groups.

Result: The result of the present study revealed that Sites where implants were placed with flapless technique showed lesser mean crestal bone loss scores as compared to sites where implants were placed with open flap technique, although the difference was insignificant.

Conclusion: It can be concluded that flapless procedure may be considered as a better treatment option as compared to implant placed with open flap technique in terms of minimal pain, inflammation and less crestal bone loss associated with flapless technique than open flap technique.

This is an Open Access (OA) journal, and articles are distributed under the terms of the [Creative Commons Attribution-NonCommercial-ShareAlike 4.0 License](https://creativecommons.org/licenses/by-nc-sa/4.0/), which allows others to remix, tweak, and build upon the work non-commercially, as long as appropriate credit is given and the new creations are licensed under the identical terms.

For reprints contact: reprint@ipinnovative.com

1. Introduction

Traditionally, access for implant placement has been by elevation of full thickness mucoperiosteal flap approach.¹ This approach allows the clinician to directly visualize the alveolar bone and assess bone morphology of the ridge.² However, this technique is relatively invasive and causes patient discomfort and marginal bone loss due to decreased supraperiosteal blood supply.³ When flaps are reflected for

the placement of implants, blood circulation from the soft tissue to the bone is disrupted, which results in poorly vascularized bone, thus promoting bone resorption during the initial healing phase almost at crestal region.⁴

To overcome the limitations of elevation of mucoperiosteal flap which may lead to postoperative peri-implant tissue loss and to overcome the challenge of the soft tissue management during or after surgery, the concept of flapless implant surgery was introduced for patients with sufficient bone volume in implant recipient site.⁵ In recent years, it has been noted that flapless

* Corresponding author.

E-mail address: priyankabds12@hotmail.com (P. Kumari).

implant surgical procedure is a predictable procedure with a high success rate if patients are properly selected and an appropriate width of bone is available for implant placement, as well as if sufficient quantity of keratinized gingiva is also present.⁶

2. Aim and Objectives

To evaluate radiographically various hard tissue changes at different time intervals around implants

1. With open flap technique
2. With flapless technique
3. Comparison between the two

3. Materials and Methods

A randomized, split mouth, radiograph study was conducted to evaluate the hard tissue changes in open flap technique versus flapless technique around implants at the different time interval. Screening of partially edentulous patients with at least two missing teeth was done in patients who visited the Outpatient Department, Department of Periodontics, Institute of Dental Studies & Technologies Modinagar, Uttar Pradesh.

3.1. Inclusion criteria

1. Good oral hygiene
2. Systemically healthy patients
3. Minimum two or even multiple number of missing teeth with adequate inter occlusal distance for implant prosthesis
4. Adequate bone height and width

3.2. Exclusion criteria

1. Smokers
2. Para functional habit
3. Uncontrolled diabetes
4. Blood disorders

3.3. Methodology

Pre-surgical CBCT imaging was done to assess the width and height of the implant to be placed at all the thirty edentulous sites in fourteen patients. Also the quality of bone was assessed using this CBCT scan. (Figure 1 A, B and Figure 2)

4. Result

4.1. Crestal bone level (Mesial)

4.1.1. Intragroup comparison

4.1.1.1. Group I (Open flap technique). The mean Crestal Bone Level (mesial) for the implants placed in Group I was 11.20 ± 1.66 at Baseline (BL_R) i.e. at the time of implant

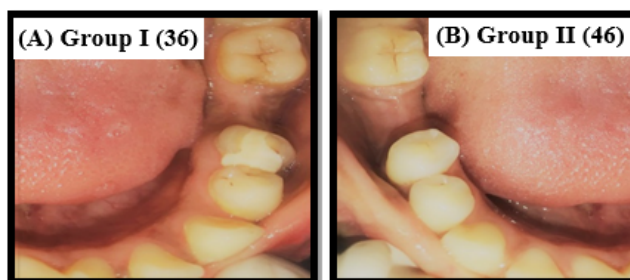


Figure 1: Preoperative site for implant placement

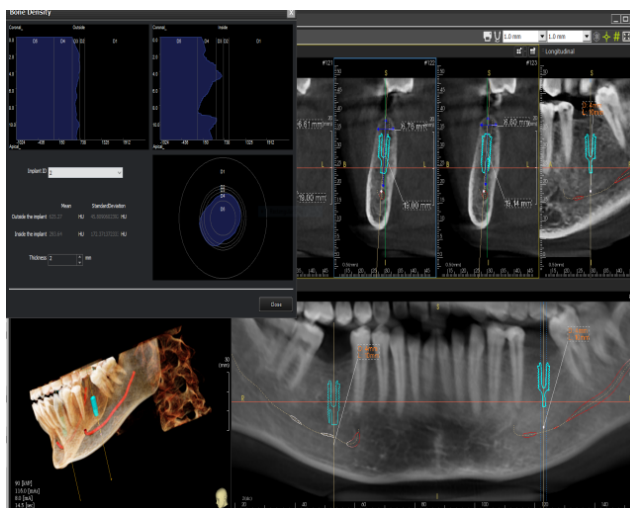


Figure 2: Preoperative CBCT (before implant placement)

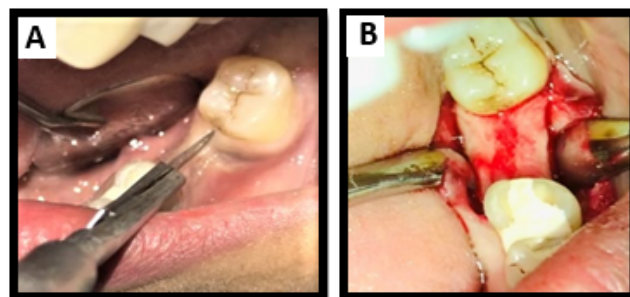


Figure 3: Incision and full thickness flap elevation

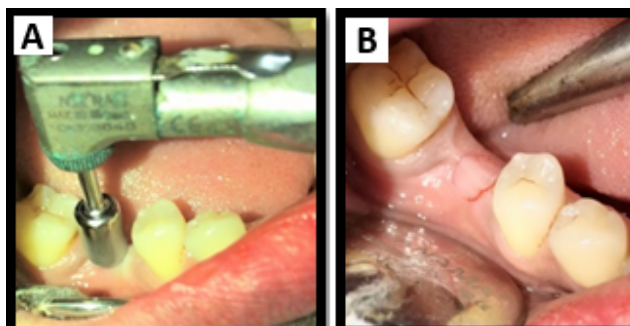


Figure 4: Marking implant site with soft tissue punch

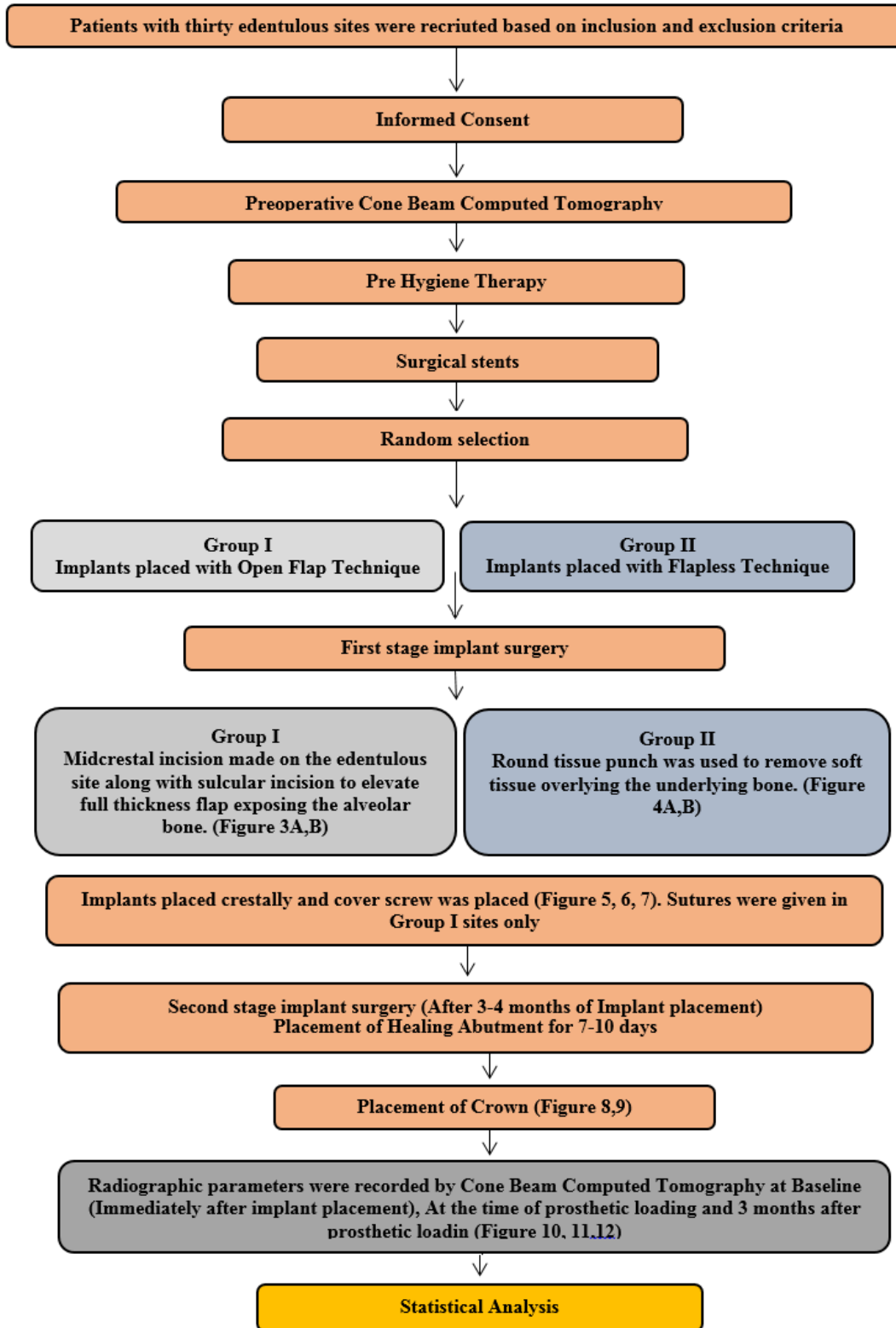


Chart 1: Flow chart of the study protocol

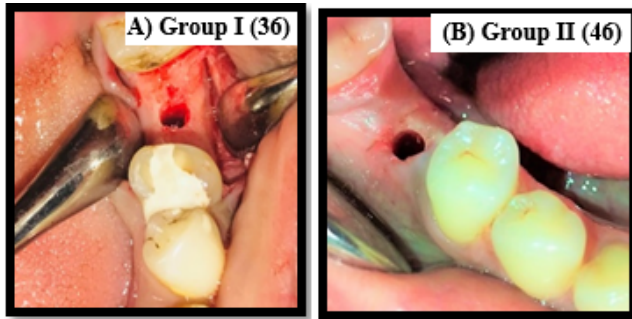


Figure 5: Osteotomy site preparation

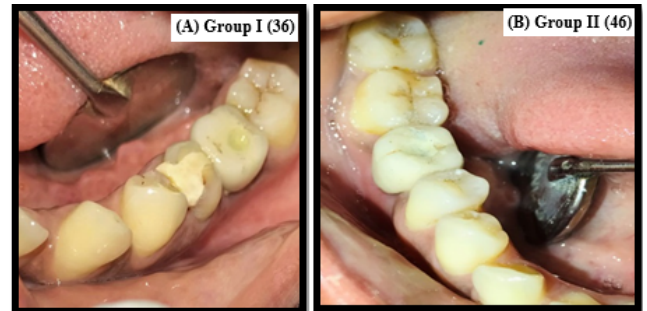


Figure 8: Placement of prosthesis

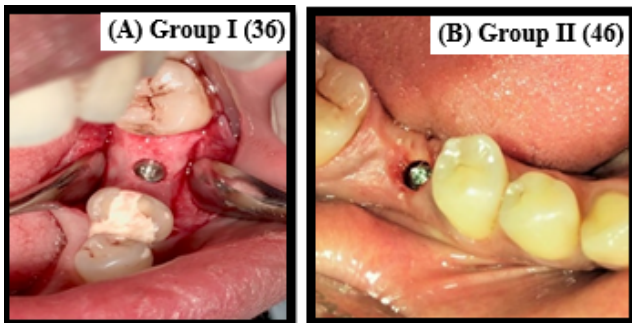


Figure 6: Site after implant placement

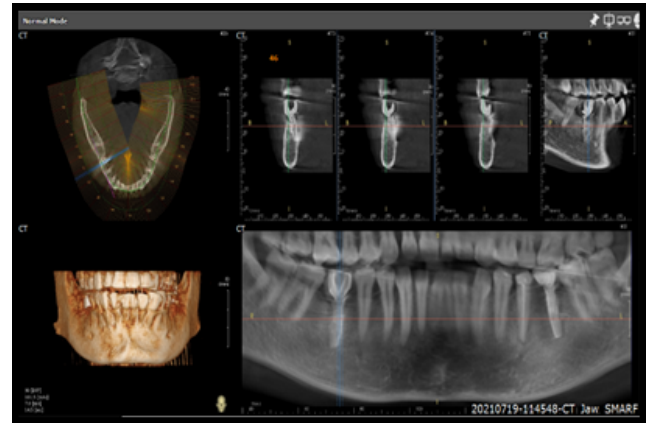


Figure 9: CBCT with Prosthesis in place

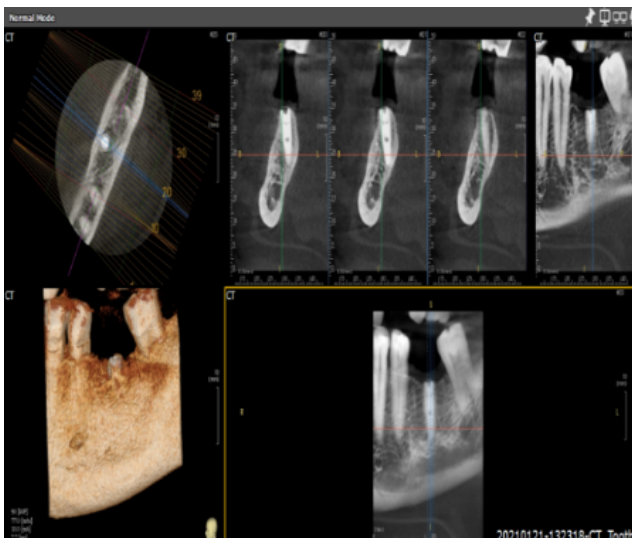


Figure 7: Post-operative CBCT (immediately after implant placement)

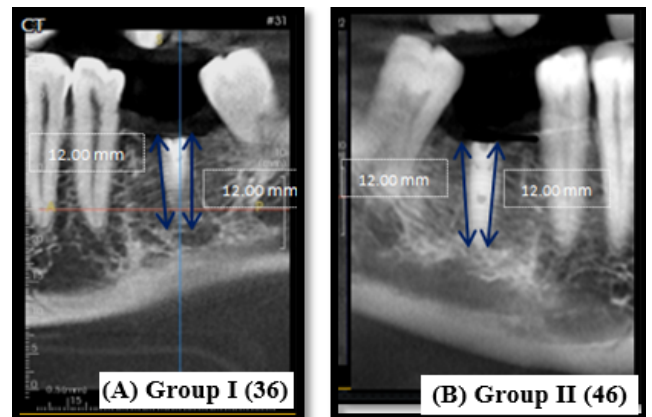


Figure 10: Baseline (immediately after implant placement)

placement, which decreased to 10.93 ± 1.62 at the time of prosthetic loading and further decreased to 10.69 ± 1.61 at 3 months after prosthetic loading. (Table 1, Graph 1)

The inter-interval comparison of Crestal Bone Loss (mesial) was done using Student t- test. The Crestal Bone Loss (mesial) increased significantly from baseline till the time of prosthetic loading (0.27 ± 0.11 , p-value 0.001) and from the time of prosthetic loading to 3 months after prosthetic loading (0.24 ± 0.11 , p-value 0.001). (Table 1,

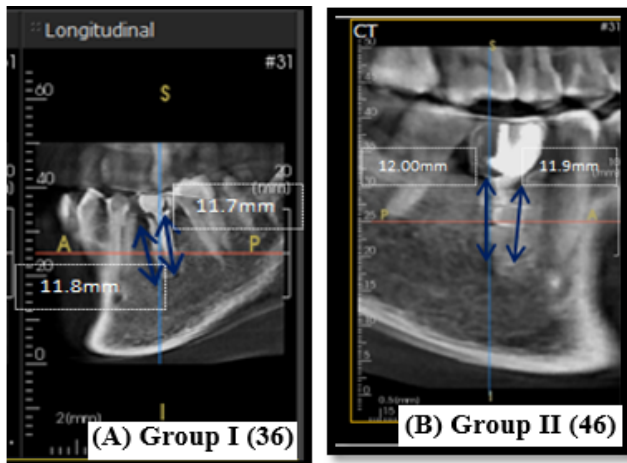


Figure 11: At the time of prosthetic loading

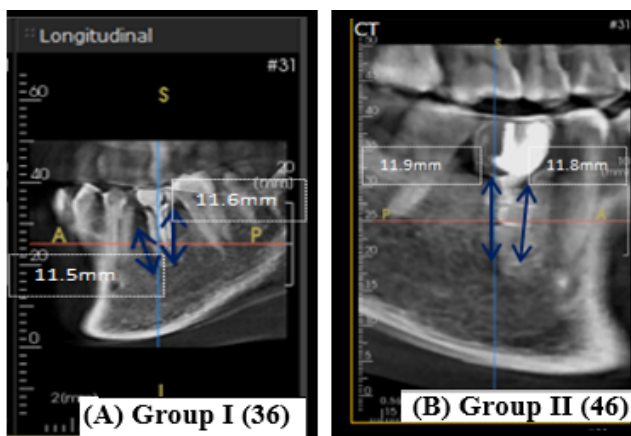
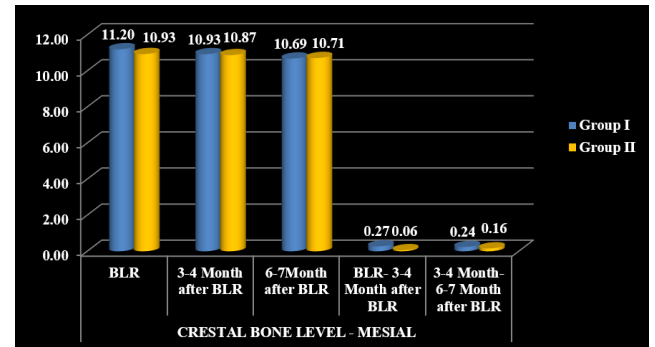
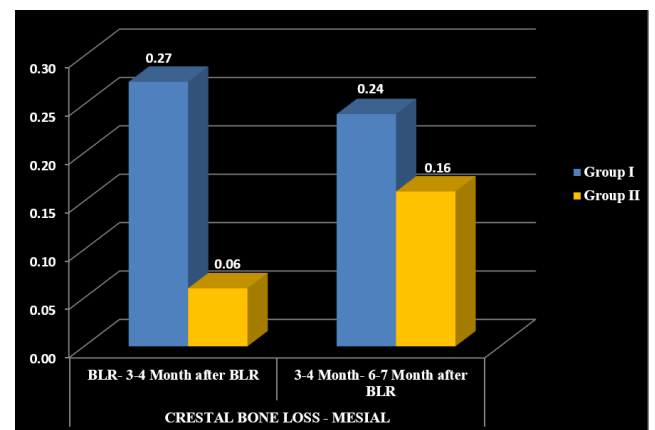


Figure 12: Three months after prosthetic loading

Group I and Group II was done using unpaired t-test. There was significant difference in mean Crestal Bone Level (Mesial) at baseline (at the time of implant placement) (0.27, t-test 0.529, p-value 0.601), at the time of prosthetic loading (0.05, t-test 0.105, p-value 0.917) and 3 months after prosthetic loading (-0.03, t-test -0.052, p-value 0.959) between Group I and Group II. (Table 1, Graph 1) there was significance difference in Crestal Bone Loss (mesial) from the time of implant placement till of prosthetic loading (0.21, t value=3.083, p value= 0.005) and from the time of prosthetic loading till 3 months from prosthetic loading. (0.08, t value=2.518, p value=0.018) (Table 1 Graph 2)



Graph 1: Intragroup and intergroup changes in crestal bone levels (mesial) at different time intervals



Graph 2: Intragroup and intergroup changes in crestal bone loss (mesial) at different time intervals

Graph 2)

4.1.1.2. Group II (Flapless technique). The mean Crestal Bone Level (mesial) for the implants placed in Group II was 10.93 ± 1.03 at baseline i.e. at the time of implant placement, decreased to 10.87 ± 1.12 at the time of prosthetic loading and further decreased to 10.71 ± 1.14 at 3 months after prosthetic loading. (Table 1, Graph 1)

The inter-interval comparison of Crestal Bone Loss (mesial) was done using Student t- test. The Crestal Bone Loss (mesial) increased significantly from baseline till the time of prosthetic loading (0.06 ± 0.24 , p-value 0.108) and from the time of prosthetic loading to 3 months after prosthetic loading (0.16 ± 0.06 , p-value 0.001). (Table 1, Graph 2)

4.1.2. Intergroup comparison

The mean Crestal Bone Level (Mesial) at baseline i.e. at the time of implant placement, at the time of prosthetic loading and from 3 months after prosthetic loading between

4.2. Crestal bone level (Distal)

4.2.1. Intragroup comparison

4.2.1.1. Group I (Open flap technique). The mean Crestal Bone Level (distal) was 11.20 ± 1.66 at baseline i.e. at the time of implant placement, decreased to 10.85 ± 1.63 at the time of prosthetic loading and further decreased to 10.59 ± 1.64 at 3 months after prosthetic loading. (Table 2, Graph 2)

Table 1: Intragroup and intergroup changes in crestal bone levels (mesial) at different time intervals

Time interval	Group I		Group II		Intergroup comparison		
	Mean	Std. Deviation	Mean	Std. Deviation	Mean Difference	t-test value	p-value
BL _R	11.20	1.66	10.93	1.03	0.27	0.529	0.601
3-4 Month after BL _R	10.93	1.62	10.87	1.12	0.05	0.105	0.917
6-7 Month after BL _R	10.69	1.61	10.71	1.14	-0.03	-0.052	0.959
BL _R -3-4 Month after BL _R	0.27	0.11	0.06	0.24	0.21	3.083	0.005*
3-4 Month after BL _R - 6-7 Month after BL _R	0.24	0.11	0.16	0.06	0.08	2.518	0.018*

Paired t-test and Student t-test applied, *p-value significant at <0.05, # non-significant

The Crestal Bone Loss (distal) increased significantly from baseline till the time of prosthetic loading (0.35 ± 0.14 , p-value 0.001) and from the time of prosthetic loading to 3 months after prosthetic loading (0.25 ± 0.15 , p-value 0.001). (Table 2, Graph 4)

4.2.1.2. Group II (Flapless technique). The mean Crestal Bone Level (distal) was 10.93 ± 1.03 at baseline (at the time of implant placement) which decreased to 10.81 ± 1.18 at the time of prosthetic loading and further decreased to 10.66 ± 1.15 at 3 months after prosthetic loading. (Table 2, Graph 3)

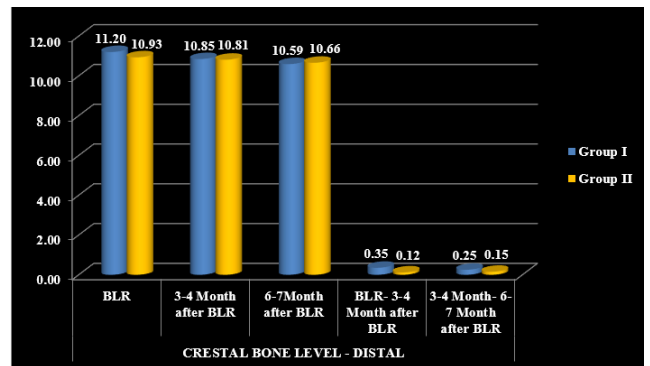
The Crestal Bone Loss (distal) increased significantly from baseline till the time of prosthetic loading (0.12 ± 0.29 , p-value 0.001) and from the time of prosthetic loading to 3 months after prosthetic loading (0.15 ± 0.09 , p-value 0.001). (Table 2, Graph 4)

4.2.2. Intergroup comparison

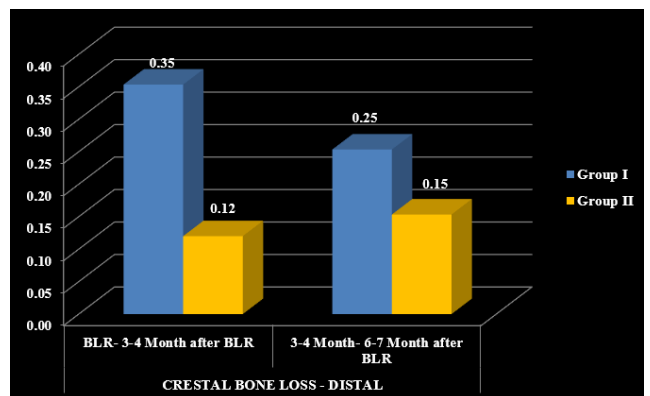
There was significant difference in mean Crestal Bone Level (distal) at baseline (at the time of implant placement) (0.27 , t-test 0.529 , p-value 0.601), at the time of prosthetic loading (0.03 , t-test -0.064 , p-value 0.949) and 3 months after prosthetic loading (-0.07 , t-test -0.129 , p-value 0.898) between Group I and Group II. There was significant difference in Crestal Bone Loss (distal) from the time of implant placement till the time of prosthetic loading (0.23 , t value= 2.797 , pvalue= 0.009) and from the time of prosthetic loading to 3 months after prosthetic loading (0.10 ; t value= 2.250 ; pvalue= 0.032) (Table 2, Graph 4)

5. Discussion

In our study, in both the groups, the mean crestal bone loss (mesial and distal) from the time of implant placement till the time of prosthetic loading was less as compared to the crestal bone loss from the time of prosthetic loading till the time of 3 months post prosthetic loading indicating that physiologic remodelling does take place during first 3 months of implant placement and thereafter functional loading may lead to increase crestal bone



Graph 3: Intragroup and intergroup changes in crestal bone levels (distal) at different time intervals



Graph 4: Intragroup and intergroup changes in crestal bone loss (distal) at different time interval

loss. According to Hermann JS et al⁷ many procedural and biomechanical factors like implant design, micro movement and second stage surgery may lead to disruption of junctional epithelium leading to more crestal bone resorption after loading.

In intergroup comparison, there was no significant difference in mean crestal bone loss (mesial) and (distal) at from the time of implant placement till the time of prosthetic

Table 2: Intragroup and intergroup changes in crestal bone levels (distal) at different time intervals

Time interval	Group I		Group II		Intergroup comparison		
	Mean	Std. Deviation	Mean	Std. Deviation	Mean Difference	t-test value	p-value
BL _R	11.20	1.66	10.93	1.03	0.27	0.529	0.601
3-4 Month after BL _R	10.85	1.63	10.81	1.18	0.03	0.064	0.949
6-7 Month after BL _R	10.59	1.64	10.66	1.15	-0.07	-0.129	0.898
BL _R -3-4 Month after BL _R	0.35	0.14	0.12	0.29	0.23	2.797	0.009*
BL _R	p-value = 0.001*		p-value = 0.406				
3-4 Month after BL _R -	0.25	0.15	0.15	0.09	0.10	2.250	0.032*
6-7 Month after BL _R	p-value = 0.001*		p-value = 0.001*				

Paired t-test and Student t-test applied, *p-value significant at <0.05, # non-significant

loading and from the time of prosthetic loading to 3 months after prosthetic loading. These results were in accordance with the previous research by Sunitha and Sapthagiri⁸ who observed that the mean bone loss was greater with the open flap group as compared with the flapless group.

Shibu et al⁹ noted that flapless implant surgery has improved crestal bone levels and osseointegration compared with the conventional technique. A study by Abdul-Saheb et al¹⁰ concluded that with flapless implant placement there is less bone level reduction when compared with the flap technique.¹¹ The findings of the present study demonstrate that the mean bone loss was less after flapless implant surgery and that no implants failed to osseointegrate.¹² The lower rate of crestal bone loss in the present study may be due to use of a tissue punch that was narrower than the implant itself.¹³ Another explanation for the high success rate may be that when flaps are not reflected, the periosteum is preserved, which may help to optimize the healing of the periimplant tissue.¹⁴ Therefore, the flapless technique can be considered as a better treatment approach for the placement of implants.¹⁵

6. Conclusion

It can be concluded that flapless procedure may be considered as a better treatment option as compared to implant placed with open flap technique in terms of minimal pain, inflammation and less crestal bone loss associated with flapless technique than open flap technique.¹⁶ Proper evaluation of bone type, height and width of the residual ridge, amount of available keratinized tissue and clinical acumen of the clinician determines the success of flapless procedure.¹⁷

7. Source of Funding

None.

8. Conflict of Interest

None.

References

- Asadollahi R, Khan M, Yahyazadehfard N, Kaouhestani, Tehrani Z. Dental implant placement with flapless and flapped technique: A systemic review. *J Oral Res.* 2018;7(7):324–35.
- Al-Juboori MJ. Flap procedures for implant related surgical procedures: A review. *Implant Dent.* 2016;25(6):845–54.
- Gupta R, Luthra RP, Kukreja S. To compare and evaluate the difference in crestal bone loss after implant placement by conventional flap and flapless technique followed by early loading of implants: An in vivo study. *Int J Appl Dent Sci.* 2018;4(1):213–8.
- Job S, Bhat V. An insight into flapless implant placement technique. *J Indian Prosthodont Soc.* 2008;8(3):140–3.
- Wadhwa B, Jain V, Bhutia O, Bhalla AS, Pruthi G. Flapless versus open flap techniques of implant placement: A 15-month followup study. *Indian J Dent Res.* 2015;26:372–379.
- Parithimarkalaiganan S, Padmanabhan TV. Osseointegration: an update. *J Indian Prosthodont Soc.* 2013;13:2–6.
- Rana S, Verma A, Palwankar P, Dhalla N, Tyagi E. Affect of flap and flapless implant placement on crestal bone level and implant stability. *Int Journal of Dentistry.* 2017;4:9–14.
- Rousseau P. Flapless and Traditional Dental Implantation. *J Oral Maxillofac Surg.* 2010;68:2299–306.
- Nickenig HJ, Wichmann M, Schlegel KA, Nkenke E, Eitner S. Radiographic evaluation of marginal bone levels during healing period, adjacent to parallel-screw cylinder implants inserted in the posterior zone of the jaws, placed with flapless surgery. *Clin Oral Impl Res.* 2010;21(12):1386–93.
- Ravindran DM, Sudhakar U, Ramakrishnan T, Ambalavanan N. The efficacy of flapless implant surgery on soft-tissue profile comparing immediate loading implants to delayed loading implants: A comparative clinical study. *J Indian Soc Periodontol.* 2010;14(4):245–51.
- Lindeboom JA, Van Wijk A. A comparison of two implant techniques on patient-based outcome measures: a report of flapless vs. conventional flapped implant placement. *Clin Oral Implants Re.* 2010;21(4):366–70.
- Jeong SM, Choi BH, Kim J, Xuan F, Lee DH, Mo DY, et al. A 1-year prospective clinical study of soft tissue conditions and marginal bone changes around dental implants after flapless implant surgery. *Oral Surg Oral Med Oral Pathol Oral Radiol Endod.* 2011;111(1):41–6.
- Jeong S, Choi B, Xuan F, Kim H. Flapless Implant Surgery Using a MiniIncision. *Clin Implant Dent Relat Res.* 2012;14(1):74–9.
- Tsoukaki M, Kalpidis C, Sakellari D, Tsalikis L, Mikroggiorgis G, Konstantinidis A, et al. Clinical, radiographic, microbiological and immunological outcomes of flapped vs. flapless dental implants: a prospective randomized controlled clinical trial. *Clin Oral Impl Res.* 2012;5:1–8.
- Job S, Bhat V, Naidu EM. In vivo evaluation of crestal bone heights following implant placement with flapless and with flap techniques in sites of immediately loaded implants. *Indian J Dent*

Res. 2019;19(4):320–5.

16. Brodala N. Flapless surgery and its effect on dental implant outcomes. *Int J Oral Maxillofac Implants*. 2009;24:118–25.
17. Sclar AG. Guidelines for flapless surgery. *J Oral Maxillofac Surg*. 2007;65(7 Suppl 1):20–32.

Mansi Bansal, Professor

MD. Rehan, Reader

Amit Prakash, Senior Lecturer

Author biography

Priyanka Kumari, Consultant Periodontist

Manish Khatri, Professor and HOD

Cite this article: Kumari P, Khatri M, Bansal M, Rehan MD, Prakash A. Radiographic evaluation of hard tissue changes in open flap technique versus flapless technique for implant placement. *IP Int J Periodontol Implantol* 2024;9(1):38-45.