

Content available at: <https://www.ipinnovative.com/open-access-journals>

IP International Journal of Periodontology and Implantology

Journal homepage: <https://www.ijpi.in/>

## Original Research Article

# Efficacy of autologous platelet rich fibrin (PRF) and hydroxyapatite bioactive glass (HABG) in the management of intra bony defects -A randomized controlled trial

Rekha P Radhakrishnan<sup>1\*</sup>, Presanthila Janam<sup>2</sup>, Bindu Radhakrishnan Nayar<sup>3</sup>,  
Lekshmi A Jayasree<sup>4</sup>

<sup>1</sup>Dept. of Periodontology, Government Dental College, Kottayam, Kerala, India

<sup>2</sup>Dept. of Periodontology, PMS College of Dental science, Vattappara, Thiruvananthapuram, Kerala, India

<sup>3</sup>Dept. of Periodontology, Government Dental College, Alappuzha, Kerala, India

<sup>4</sup>Dept. of Periodontology, Mar Baselios Dental College, Kothamangalam, Ernakulam, Kerala, India



## ARTICLE INFO

## Article history:

Received 25-10-2023

Accepted 23-11-2023

Available online 02-12-2023

## Keywords:

Periodontitis

Regeneration

Intra bony defects

Platelets

Platelet rich fibrin

## ABSTRACT

**Background:** The ultimate aim of periodontal therapy is regeneration. Traditionally, many techniques and agents were used. The therapeutic outcome in treatment of intra bony defects can be augmented with the use of growth factors alongside bone grafts. The present clinical trial was designed to assess the efficacy of an alloplastic composite graft and the combination of autologous platelet rich fibrin with the graft in the management of intra bony defects.

**Materials and Methods:** A total of 45 systemically healthy patients with intra bony defects indicated for flap surgery were selected from the outpatient department of periodontics. The patients were divided into three groups with the help of a computer generated random number table. Age, sex, and periodontal parameters (probing pocket depth, clinical attachment level, gingival marginal level, plaque index, modified sulcus bleeding index) and presence of intra bony defects were recorded. The defects in group I patients were treated with autologous PRF along with the graft, group II with graft, and group III with open flap debridement alone. All the patients were recalled at 3, 6, 9 months after surgery, and the periodontal parameters were recorded in each recall.

**Results:** The baseline parameters were compared with 9 month post op periodontal parameters by non parametric test for ANOVA (Kruskal Wallis). Maximum pocket depth reduction ( $5.86 \pm 1.03$ ) maximum gain in attachment ( $4.64 \pm 1.08$ ), reduction in modified sulcus bleeding index were seen in group I, which is statistically significant between the groups. Though change in gingival marginal level is minimum for group I ( $1.21 \pm 0.42$ ), it was not statistically significant. Group I showed the maximum percentage of sites with bone fill (92.9%) which was also statistically significant when analyzed by the chi-square test.

**Conclusion:** The Combination of autologous PRF with the hydroxy apatite bioglass graft in the management of intra bony defects showed improved clinical and radiographic outcome.

This is an Open Access (OA) journal, and articles are distributed under the terms of the [Creative Commons Attribution-NonCommercial-ShareAlike 4.0 License](https://creativecommons.org/licenses/by-nc-sa/4.0/), which allows others to remix, tweak, and build upon the work non-commercially, as long as appropriate credit is given and the new creations are licensed under the identical terms.

For reprints contact: [reprint@ipinnovative.com](mailto:reprint@ipinnovative.com)

## 1. Introduction

Periodontal regeneration is considered as the most ideal outcome of periodontal therapy. This accomplishes the restoration of lost periodontium which may increase the

attachment of teeth to the periodontium and induce bone formation. Moreover it maintains a stable functional trouble free dentition with satisfactory esthetic appearance.<sup>1-3</sup> Periodontal wound healing and regeneration are complex processes which involve a sequence of interaction between cells, matrix and vascular compartments of the periodontium. A variety of materials and techniques have

\* Corresponding author.

E-mail address: [rekhanbr@gmail.com](mailto:rekhanbr@gmail.com) (R. P. Radhakrishnan).

been tried for regeneration. Use of bone replacement grafts has been tried extensively in the past with varying success rates. Autologous bone grafts are considered as the “Gold standard” since they possess the unique property of osteogenesis in addition to osteoinduction and osteoconduction.<sup>4,5</sup> Difficulty in procuring adequate graft material, the need for the second surgical site, and postoperative patient discomfort are the potential causes which limit the use of autologous bone.<sup>6</sup> Alloplastic bone substitutes are natural or synthetic materials that contain some important chemical components of natural bones like Calcium and Phosphates. They are available with the standardized product quality and zero percentage of risk of transmission of infectious diseases.<sup>7</sup> However, to date, use of any of the alloplastic bone substitutes has not resulted in histological evidence of new attachment. In order to improve the regenerative potential of the alloplastic bone substitute growth factors, biologics and/or membranes have tried and some of them showed significant improvements in clinical outcomes and consistent results over a long period of time.<sup>8</sup>

The use of autologous platelet concentrates is an economical and convenient method of these biologic mediators. The platelets released from blood vessels are very important in fibrin clot formation. Platelet rich fibrin (PRF) is a second generation platelet concentrate first developed in France by Choukran et al.<sup>9</sup> PRF is basically a biomaterial consisting of fibrin matrix with trapped platelets and leukocytes, where platelets and leukocyte cytokines are crucial in determining the therapeutic potential.<sup>10</sup> PRF is prepared from patient's own blood without addition of any anticoagulants and it does not involve any other biochemical modifications.<sup>11</sup> It was demonstrated that platelets in PRF released growth factors; [Platelet derived growth factor (PDGF), Vascular endothelial growth factor (VEGF), Transforming growth factor(TGF), Insulin like growth factor (IGF), epidermal growth factor (EGF) and FGF (fibroblast growth factor)] in about the same concentration for about 7 day duration.<sup>12</sup> These polypeptide growth factors present in granules of platelets and cytokines have been shown to modulate the wound healing events of periodontal hard and soft tissues.<sup>13</sup> The matrix molecules like fibronectin and vitronectin are also secreted by platelets and these helps with adhesion of molecules and cell migration.<sup>10,14</sup> PRF has been used with various graft materials and the results were promising.<sup>15,16</sup>

Keeping the above facts in mind, the present clinical trial was carried out to know whether the addition of autologous PRF with an alloplastic composite graft material is more effective in the management of intra bony defects compared to the open flap debridement.

## 2. Aim and Objectives

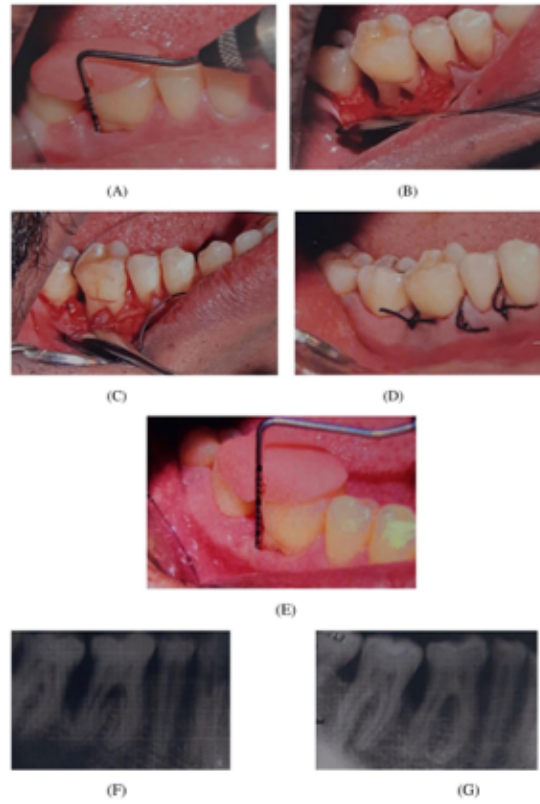
The aim of the present study was to find the efficacy of a alloplastic composite graft (*Biograft®-HABG active*), and a combination of autologous platelet rich fibrin with the same graft (*Biograft® -HABG active*) in the management of intra bony defects as compared with open flap debridement alone as measured by clinical and radiographic parameters.

1. Change in probing pocket depth (PPD)
2. Change in clinical attachment level (CAL)
3. Change in gingival marginal level (GML) measured in millimeters by using University of North Carolina Number 15 (UNC 15) Periodontal Probe.
4. Bone defect fill –assessed with intraoral periapical radiographs taken with paralleling technique with grids.

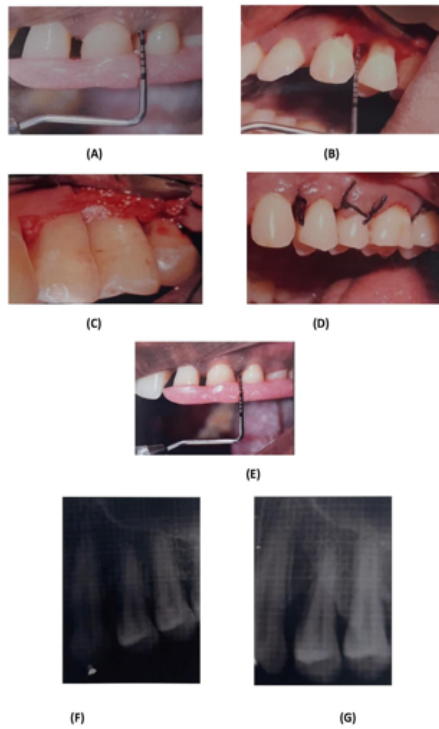
## 3. Materials and Methods

The study was conducted in the Department of Periodontics, Govt. Dental College, Thiruvananthapuram. The study protocol was approved by the Institutional Ethics Committee. Patients reported to the Department were carefully examined clinically to assess the extent and severity of periodontitis. Proper oral hygiene instructions were given and nonsurgical periodontal therapy was done in two appointments. Study subjects were selected from them based on inclusion criteria, which included systemically healthy individuals between 18 to 65 years who have more than 5 mm probing pocket depths after nonsurgical periodontal therapy with intra bony defects. Patients with uncontrolled systemic diseases or any other infectious diseases, the habit of smoking or pan chewing, with a previous history of periodontal treatment were excluded. They were clearly informed about the study procedure and purpose. Those patients who are willing to participate in the study were recruited for it, and written informed consent obtained. Study casts for all the patients were prepared. Customized acrylic stents were prepared for them in the areas of interest. Stents were grooved with a straight fissure bur in apico-coronal direction where probing depth was maximum to ensure a reproducible placement of the University of North Carolina No. 15 Periodontal Probe (UNC-15 Probe). Study sites were decided, and following clinical parameters were assessed: Probing pocket depth (PPD), Gingival marginal level (GML), and Clinical attachment level (CAL). Intra oral periapical radiographs of the study sites were taken with long cone paralleling technique with grids to know the alveolar bone levels of the study sites at baseline.

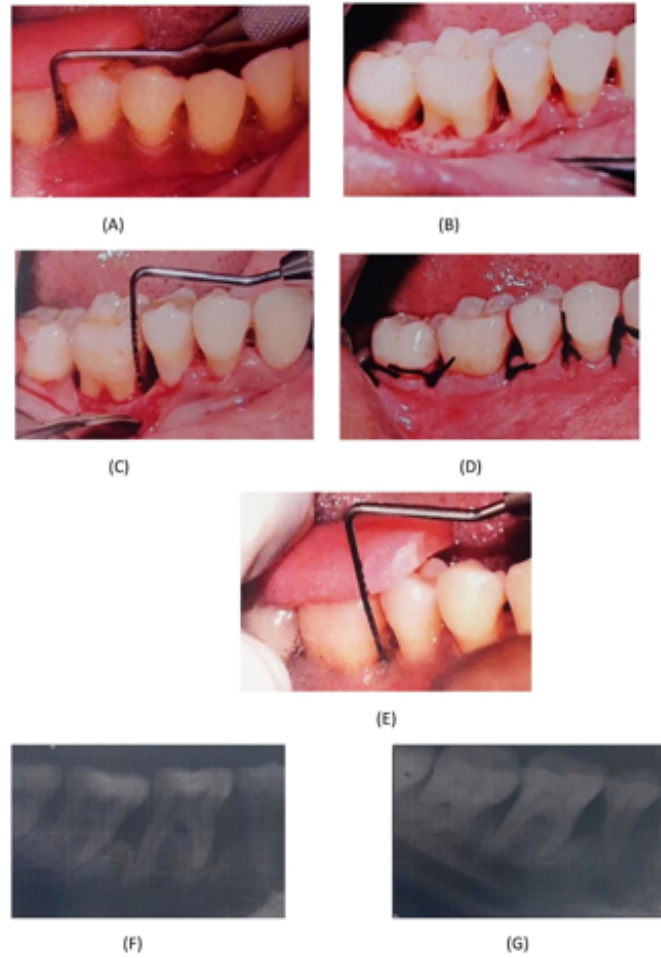
The study was conducted as a single blind randomized clinical trial. The study was registered in Clinical trials registry of India (CTRI). From the reference population those met the inclusion criteria and willing to participate



**Figure 1:** Surgical procedure group I (A) PRE operative probing depth (B) Flap reflected (C) PRF and graft mixture placed in the defect (D) Sutures placed (E) Postoperative probing depth. (F) PRE operative radiograph (G) Post operative radiograph



**Figure 2:** Surgical procedure group II (A) Pre operative probing depth (B) Osseous defect (C) Graft placed in the defect (D) Sutures placed (E) Postoperative probing depth. (F) Pre operative radiograph (G) Post operative radiograph



**Figure 3:** Surgical procedure for group III (A) Pre-operative probing depth (B & C) Flap reflected and the defect (D) Suture placed (E) Post-operative probing depth. (F) Pre-operative radiograph (G) Post-operative radiograph.

**Table 1:** Comparison of baseline parameters of the three groups

Groups	No.of subjects	Sex	Age (In yrs)	PPD (in mms)	GML (in mms)	CAL (In mms)	PI	MSBI
Group I (PRF+graftgroup)	14	Male-5 Female-9	36.85± 5.18	9.50±1.40	1.14± 1.03	10.64± 1.69	0.38 ± 0.29	1.48 ±0.29
Group II (graft group)	13	Male-5 Female-8	36.23± 7.14	8.54±1.76	1.38± 1.26	9.92± 2.72	0.44 ± 0.21	1.40 ± 0.60
Group III (open flap debridement)	13	Males-3 Females-10	33.30± 9.42	8.23±1.16	0.77± 0.83	9.00± 1.53	0.35 ± 0.28	1.04 ±0.38
Test statistics		0.80	0.868	4.91	1.78	4.33	0.74	7.92
P value		0.669#	0.428**	0.086*	0.411*	0.115*	0.690*	0.019*

# chisquare test \*kruskal wallis test \*\*anova test

**Table 2:** Comparison of baseline, 3month, 6month & 9month periodontal parameters for the three groups

Groups	Periodontal parameter	Baseline	3 month	6 month	9 month
Group I (graft + PRF group)	PPD (in mms)	9.50 ±1.40	4.00±1.18	3.78±0.97	3.64±1.01
	GML(in mms)	1.14 ±1.03	2.21 ± 1.12	2.21± 1.12	2.36±1.15
	CAL (in mms)	10.64 ±1.69	6.21± 1.88	6.00±1.80	6.00±1.80
	Modified sulcus bleeding index	1.48 ±0.29	0.23± 0.18	0.19±0.14	0.14±0.13
Group II (graft group)	PPD (in mms)	8.54±1.76	4.15 ±1.21	3.77 ±0.72	3.92±0.95
	GML (in mms)	1.38±1.26	2.62± 1.56	2.85 ± 1.46	2.92±1.50
	CAL (in mms)	9.92±2.72	6.77±2.38	6.62 ±1.94	6.85±2.23
	Modified sulcus bleeding index	1.40±0.60	0.29±0.20	0.14 ±0.13	0.17±0.19
Group III ( open flap debridement)	PPD (in mms)	8.23±1.17	4.00±1.08	3.85±0.89	3.92±0.95
	GML (in mms)	0.77±0.83	2.00± 1.00	2.38±1.12	2.38±1.12
	CAL (in mms)	9.00±1.53	5.92±1.55	6.15± 1.57	6.31±1.70
	Modified sulcus bleeding index	1.04 ±0.38	0.23±0.16	0.15±0.13	0.15±0.19

**Table 3:** Comparison of clinical parameter change between three groups at baseline & up. 9 month follow

Parameter Change	Group I (Graft+ PRF group)	Group II (Graft group)	Group III (Open flap debridement group)	Test statistics	P value
Mean probing depth reduction	5.86±1.03	4.62± 1.04	4.31± 0.63	14.43	0.001 *
Mean gingival marginal level change	1.21± 0.42	1.62± 0.77	1.62 ± 0.51	4.88	0.087 **
Mean clinical attachment gain	4.64± 1.08	3.08± 0.95	2.69± 0.86	17.82	0.000 *
mSBI difference	1.33± 0.29	1.23± 0.57	0.88± 0.33	8.59	0.014**

\* Kruskal wallis test shows a statistically significant reduction in mean probing depth reduction and clinical attachment gain and modified sulcus bleeding index between the groups.

\*\* But the gingival marginal level change among the group is not statistically significant.

**Table 4:** Percentage of post operative defect fill in the three groups

	No. of.subjects treated	No. of subjects with defect fill	Percentage	No. of. subjects with no defect fill	Percentage	Pearson chi square value	P value
Group I (PRF+ Graft group)	14	13	92.9	1	7.1	16.53	0.000 *
Group II (Graft Group)	13	6	46.2	7	53.8		
Group III (Open flap debridement group)	13	2	15.4	11	84.6		

\* Pearson chi-square test shows the p value 0.000

were randomly divided into the following three groups with the help of a computer assisted random number table generator.

1. *Group I*-Patients with intra bony defects treated with autologous platelet rich fibrin (PRF) along with the Biograft –HABG active
2. *Group II*-Patients with intra bony defects treated with Biograft –HABG active
3. *Group III*- Patients with intra bony defects treated with conventional open flap debridement alone

The sample size was calculated based on a previous study, and it was 15 in each group.<sup>17</sup>

### 3.1. Surgical protocol

On the day of periodontal surgery Intraoral antiseptics was performed with 0.2% chlorhexidine gluconate rinse. Patients in all the three groups were planned for the modified flap operation with crevicular incision (Kirkland flap). Following administration of local anesthesia (Lignocaine 2% with 1: 200000 adrenaline), crevicular and interdental incisions made with No.11 surgical blade and mucoperiosteal flaps were reflected. Care was taken to preserve as much healthy inter proximal soft tissues as possible. Meticulous defect debridement and root planning were carried out using area specific curettes and ultrasonic instruments. The roots were conditioned with doxycycline. Biograft HABG active and autologous PRF were mixed in a sterile dappen dish, and the mixture was used to fill the intra bony defects in group I. Biograft HABG active were mixed with saline in a sterile dappen dish and packed to the level of the surrounding bony walls in group II. In group III patients the intra bony defect were thoroughly debrided and no PRF or grafts were used to fill the defects.

Care was taken not to overfill the defects. The mucoperiosteal flaps were repositioned and secured in place using 3-0 non absorbable silk suture. The surgical area was protected and covered with a periodontal dressing (COE PACK) for 7 days.

### 3.2. PRF preparation

The PRF was prepared following the protocol developed by Choukroun et al in 2002. The centrifuge used for the purpose is Remi table top centrifuge R-303 model. The blood samples were collected intra operatively. After thorough debridement of the periodontal defect, 10 ml of patient's blood was collected from ante-cubital vein. It was immediately transferred to a sterile glass tube and centrifuged in Remi table top centrifuge at 3000 rpm (approximately 400 g) for 10 minutes without anticoagulant. This resulted in the separation of 3 basic fractions because of differential densities.

1. Red corpuscles at the bottom

2. Structured fibrin clot in the middle
3. Acellular plasma or platelet poor plasma [PPP] at the top

PRF was easily separated from the red corpuscles base (preserving a small red blood cell layer using scissors) It was cut into small pieces and mixed with bone graft and condensed into the intra bony defect in the group I patients.

### 4. Post Operative Care and Recall

The antibiotics and analgesics (Amoxicillin 500mg 3 times/ day for 5 days and Ibuprofen 400 mg 2 times/ day for 3 days) were prescribed along with chlorhexidine digluconate rinse 0.2% twice daily for two weeks. Subjects were recalled 7 days. Healing and postoperative discomfort were assessed. Periodontal dressing and sutures were removed seven days postoperatively. Subjects were instructed for gentle brushing with a soft tooth brush. Each patient was instructed for proper oral hygiene postoperatively and re-examined one month after surgery. All patients were recalled for post-surgical measurements at 3 months, 6 months, 9 months after the surgical therapy. PPD, GML, CAL were measured in the follow up visits in the same manner as described for the recording of baseline parameters. Radiographs with paralleling angle technique with grids were taken at the end of 9 months. Defect fill present or absent was recorded.

### 5. Results

Out of these 45 subjects, 40 subjects completed the study. 5 subjects were lost in the follow up period, one from group I and two each from group II and group III. Out of the 40 patients 27 were females and 13 were males.

Table 1 shows the baseline parameters of the three groups tested in this clinical trial. All three groups were comparable in all parameters including age, gender, baseline periodontal parameters like probing pocket depth, gingival marginal level, and clinical attachment level and plaque index. These groups were not comparable in baseline modified sulcus bleeding index

Table 2 shows the clinical parameters recorded in recall visit at 3, 6, and 9 months for Group I, II and III. There is statistically significant reduction between baseline and each follow up for all groups.

Table 3 shows mean clinical parameter change in each group at baseline and 9 months post operatively. Mean clinical parameter changes among the three groups were analysed using Kruskal- Wallis test. In this analysis mean probing depth reduction and clinical attachment gain and changes in modified sulcus bleeding index among the groups were statistically significant (The P value is 0.001, 0.000, and 0.014 respectively) and there was no statistically significant change in gingival marginal level between the groups during the follow up period. (P value-0.087). Better outcomes in all parameters were observed in Group I.

## 6. Discussion

Periodontitis is one of the common major public health problem affecting mankind. This multifactorial disease is primarily initiated by the presence of dysbiotic biofilm, and modified by the host inflammatory response. So the treatment of periodontitis is focussed to control or eliminate the local factors. Periodontal therapy is directed at disease prevention, slowing or arresting disease progression, regeneration of lost periodontal tissues, and maintaining the achieved therapeutic objectives. Regenerative periodontal surgery using 'In situ tissue regeneration' is modified continuously to modulate regenerative processes, though they may have varying success rate and efficacy in human jaw bones.

Prichard observed that even a properly diagnosed and treated three wall intra bony defects do have the potential for predictable repair.<sup>18</sup> Bone replacement graft supports soft tissue walls of the defect and results in gain in clinical attachment level thereby facilitating regeneration of periodontal structures lost during the disease process. The fundamental biological properties of bone graft materials; osteogenesis, osteoinduction, and osteoconduction, are paramount important in performing this role effectively. Although autogenous bone grafts are considered to be the gold standard, the procurement of autogenous bone often requires a second surgical site and those donor sites reported to have increased morbidity. Allografts are also carrying the risk of transmission of diseases. Alloplastic bone grafts are natural or synthetic, inorganic, biocompatible bone graft substitutes, which have the property of osteo-conduction. The traditional alloplastic bone grafts were bio inert, whereas the new alloplastic materials are bio active.

The graft material used in this clinical trial was a composite alloplastic graft which is indigenously prepared based on the technology developed from Sree Chithira Thirunal Institute of Medical Science and Technology (SCTIMST), and marketed by IFGL bioceramics Ltd, in the commercial name Biograft-HABG active. It contains hydroxy apatite and bioglass. Synthetic HA is a biocompatible, nontoxic, osteoconductive, osteophillic material and has close structural and chemical resemblance to bone mineral, but not identical.<sup>19</sup> Hydroxy apatite (HA) is a slow resorbing graft material which leaves residual particles in the defect and causes long term inhibition of periodontal tissue ingrowth. But electrically polarized HA demonstrates enhanced osteo conductivity.<sup>4</sup> Newer synthetic alloplastic materials like bioactive glass have exhibited osteopromotive property. The excellent bioactivity of Bioglass, owing to high SiO<sub>2</sub> content, enables it to bond with surrounding tissues and promote the formation of hydroxyapatite.<sup>20</sup> Bioactive glass can develop a chemical bond with living hard tissues through the development of a surface layer of carbonated hydroxyapatite. When BG is exposed to tissue fluid, it is covered by silica rich gel on

the top of which calcium phosphate rich layer is formed that promotes absorption and concentration of osteoblast cells to form an extracellular matrix and mineralization.<sup>21</sup> The presence of hydroxyapatite in the composite graft accelerates the dissolution of bioactive glass. An added advantage of BG-HA composite bone graft materials was assumed that HA particles within the composite bone graft materials acted as a scaffold, encircling which osteoid could be deposited that resulted in an early increase in strength of newly forming bone.

In this clinical trial the composite graft treated sites (group II) showed better results than open flap debridement (group I) at 9 month post-operative evaluation. The superior properties of the composite graft may be due to the better biologic properties of bioglass. The components of bioglass induce angiogenesis and osteogenesis, and in addition they have anti-inflammatory and anti-bacterial properties.<sup>22</sup> The reason for the improvement of clinical parameters with the use of graft can be due to the above reasons. The results of this clinical trial is comparable to the results of the following studies.

A meta analysis on bioglass in 2012 by Sohrabi K et al also showed treatment of intra bony defects with BG imparts a significant improvement in both PD and CAL compared to both active controls and OFD.<sup>23</sup> It may be hypothesized that combining different alloplastic materials may provide additional benefits. In a study by Mistry S et al in 2012, in which the effect of open flap debridement, hydroxy apatite (HA), bioglass (BG) and hydroxy apatite-bioglass composite (BG-HA) were compared. In their study Bioglass treated sites and hydroxy apatite- bioglass treated sites have better results than hydroxy apatite and unimplanted sites (OFD).<sup>24</sup> The clinical study conducted by Debnath et al, also showed a similar result in which the efficacy of hydroxyapatite-bioactive glass (HA:BG) composite granules was more effective than hydroxyl apatite alone and open flap debridement in the management of periodontal defects.<sup>25</sup>

Ideal alloplastic bone substitutes demonstrate behaviour similar to the autologous bone with respect to osteo-induction and osteogenesis. Therefore, efforts to enhance the effectiveness of graft materials have focused on the use of growth factors, cell transplantation by biomimetic engineering and use of biologic agents. Autologous particulate bone and growth factors have been tried along with graft materials to improve their properties. In a study by Abhay Bhide et al, the addition of autologous cortical bone particulate (ACBP) with composite grafts showed only marginal benefits and they suggested use the use of ACBP to improve the inferior properties of grafts and should be considered in cases where adjacent bone re contouring is needed.<sup>26</sup> Human platelet concentrates have been tried along with graft materials. Addition of first generation platelet concentrates, platelet rich plasma (PRP) with graft

materials improved the clinical outcomes.<sup>27–29</sup>

The second generation platelet concentrate, platelet rich fibrin (PRF) used in the management of osseous defects showed promising results.<sup>17,30</sup> In this clinical trial efficacy of autologous PRF in addition to a composite bone graft was tried and the group I in which both used showed greater reduction in probing pocket depth, more gain in CAL and less change in gingival margin. As in this trial, the adjuvant use of PRF along with graft material was beneficial when compared with graft material alone in the studies by Dr.A.R Pradeep in 2017 and Lekovic et al in 2012.<sup>15,16</sup> In a randomized controlled clinical trial conducted by Patel et al, the efficacy of PRF was compared with Open flap debridement alone and the results showed the adjunctive use of PRF is a potential approach to improve the clinical outcome and wound healing.<sup>31</sup> In another clinical trial where the efficacy of PRF and demineralized freeze dried allograft was compared, both showed comparable improvement in clinical outcome.<sup>32</sup> In a clinical trial where BG used in combination with PRF, the combination was found to be more effective in attaining regeneration as evidenced by a gain in CAL, reduction in PPD and achieving greater bone fill as compared with treatment with BG alone in periodontal intra bony defects.<sup>33</sup>

A recent systematic review by Miron et al concluded that the use of PRF significantly improved clinical outcomes in intrabony defects when compared to OFD alone.<sup>34</sup> A network meta analysis of platelet-rich fibrin in periodontal intra bony defects by Lianmei Ye concluded platelet-rich fibrin with/without biomaterials were more effective than open flap debridement. Although allograft +collagen membrane and platelet-rich fibrin +hydroxyapatite ranked the best in terms of probing pocket depth reduction and bone gain respectively, the difference between different regenerative therapies remains insignificant.<sup>35</sup>

The improved clinical outcome in this clinical trial may be due to the known advantage of PRF. It has been found that PRF consists of a fibrin matrix polymerized in a tetra molecular structure, incorporation of platelets, leukocytes, and cytokines and circulating stem cells.<sup>36</sup> Slow fibrin polymerization during PRF processing leads to the intrinsic incorporation of platelet cytokines and glycanic chains in the fibrin meshes. This implies that PRF, unlike the other platelet concentrates, would be able to progressively release cytokines during fibrin matrix remodelling. Such a mechanism might explain the clinically observed healing properties of PRF. It is also found that PRF organized as a dense fibrin scaffold with a high number of leukocytes concentrated in one part of the clot, with a specific slow release of growth factors such as transforming growth factor  $\beta$ , platelet derived growth factor AB, and vascular endothelial growth factor and glycoproteins such as thrombospondin-1 during more than or equal to 7 days. Leukocytes seem to have a strong influence on growth factor

release, immune regulation, anti-infectious activities, and matrix remodelling during healing. All the above factors can be the reason for the improved clinical outcomes in group I.

Though statistically not significant, the gingival marginal change is less in group I when compared to group II and group III. This is in accordance with study of Thorat M et al in 2011 in which the test group showed less marginal tissue recession compared to control sites, on re-evaluation at 9 months.<sup>37</sup> The better soft tissue response seen with PRF may be because, as a healing bio material, PRF stimulates the gingival connective tissue growth factors. Moreover, the fibrin matrix itself shows mechanical adhesive properties and biologic functions like fibrin glues: it maintains the flap in a high and stable position, enhances neo-angiogenesis, reduces necrosis and shrinkage of the flap and this simple biologic principle should guarantee the remodelling and stabilization of the gingival flap in the highest possible covering position.<sup>38</sup> Immediate use of PRF to minimize the dehydration and the use of multiple layers of PRF clot also suggested for better soft tissue healing.<sup>38</sup>

Number of cases with defect fill was also assessed in this study in which 13 out of 14 cases in group I, 6 out of 13 cases in group II, and 2 out of 13 cases in group III showed evidence of defect fill in 9 month postoperative intra oral periapical radiographs. The reason for the increased percentage of bone fill in group I can be due to the osteopromotive property of PRF along with the hydroxy apatite bioglass graft. Although the percentage of bone fill not assessed in this study, the results were in accordance with the previous studies which showed clinical improvement.

Coming to the limitations of this study, the number of study subjects is less. This study has not assessed the quantity and quality of the bone formed in individual sites. To assess the definite end point outcome of periodontal regenerative therapy; the reduction in mortality of the treated teeth; the results of the treated sites should be evaluated longitudinally. Here the study evaluated the outcome only for a period of 9 months. The quantitative assessment of bone filling was not analysed and more sophisticated methods to detect the radiographic bone fill could have been used.

## 7. Conclusion

Within the limitation of this trial, it is evident that the addition of autologous PRF to the HABG grafts improves the clinical and radiographic outcomes. The platelet rich fibrin is a simple, inexpensive, easy to prepare and use methodology. Use of PRF alone or in addition to bone grafts can be considered for regeneration of intra bony defects and furcations. But the fact should be keep in mind that the precise efficacy of PRF may vary depending upon the nature of specific defect, patient factors and the surgical technique used.



## 8. Source of Funding

This research received no external funding.


## 9. Conflict of Interest


The authors declare no conflict of interest.


## References

- Kwon T, Lamster IB, Levin L. Current Concepts in the Management of Periodontitis. *Int Dent J*. 2021;71(6):462–76.
- Villar CC, Cochran DL. Regeneration of Periodontal Tissues: Guided Tissue Regeneration. *Dent Clin North Am*. 2010;54(1):73–92.
- Stavropoulos A, Bertl K, Sculean A, Kantarci A. Regenerative Periodontal Therapy in Intra-bony Defects and Long-Term Tooth Prognosis. *Dent Clin North Am*. 2022;66(1):103–9.
- Fukuba S, Okada M, Nohara K, Iwata T. Alloplastic Bone Substitutes for Periodontal and Bone Regeneration in Dentistry: Current Status and Prospects. *Materials*. 2021;14(5):1096. doi:10.3390/ma14051096.
- De Grado G, Keller L, Idoux-Gillet Y, Wagner Q, Musset AM, Jessel NB. Bone substitutes: a review of their characteristics, clinical use, and perspectives for large bone defects management. *J Tissue Eng*. 2018;9:2041731418776819. doi:10.1177/2041731418776819.
- Damien CJ, Parsons JR. Bone graft and bone graft substitutes: A review of current technology and applications. *J Appl Biomater*. 1991;2(3):187–208.
- Haugen HJ, Lyngstadaas SP, Rossi F, Perale G. Bone grafts: which is the ideal biomaterial? *J Clin Periodontol*. 2019;46(2):92–102.
- Reynolds MA, Kao RT, Camargo PM, Caton JG, Clem DS, Fiorellini JP. Periodontal Regeneration - Intra-bony Defects: A Consensus Report From the AAP Regeneration Workshop. *J Periodontol*. 2015;86(2):105–12.
- Ehrenfest DD, Rasmusson L, Albrektsson T. Classification of platelet concentrates: from pure platelet-rich plasma (P-PRP) to leucocyte- and platelet-rich fibrin (L-PRF). *Trends Biotechnol*. 2009;27:158–67.
- Dohan DM, Choukroun J, Diss A, Dohan SL, Dohan A, Mouhyi J. Platelet-rich fibrin (PRF): a second-generation platelet concentrate. Part I: technological concepts and evolution. *Oral Surg Oral Med Oral Pathol Oral Radiol Endod*. 2006;101(3):37–44.
- Dohan DM, Choukroun J, Diss A, Dohan SL, Dohan AJ, Mouhyi J. Platelet-rich fibrin (PRF): a second-generation platelet concentrate. Part III: leucocyte activation: a new feature for platelet concentrates? *Oral Surg Oral Med Oral Pathol Oral Radiol Endodontology*. 2006;101(3):51–6.
- Pavlovic V, Ciric M, Jovanovic V, Trandafilovic M, Stojanovic P. Platelet-rich fibrin: Basics of biological actions and protocol modifications. *Open Med*. 2021;16(1):446–54.
- Giannobile WV. Periodontal tissue engineering by growth factors. *Bone*. 1996;19(1):23–37.
- Mohan SP, Jaishangar N, Devy S, Narayanan A, Cherian D, Madhavan SS. Platelet-Rich Plasma and Platelet-Rich Fibrin in Periodontal Regeneration: A Review. *J Pharm Bioallied Sci*. 2019;11(2):126–56.
- Pradeep AR, Bajaj P, Rao NS, Agarwal E, Naik SB. Platelet-Rich Fibrin Combined With a Porous Hydroxyapatite Graft for the Treatment of 3-Wall Intra-bony Defects in Chronic Periodontitis: A Randomized Controlled Clinical Trial. *J Periodontol*. 2017;88(12):1288–96.
- Lekovic V, Milinkovic I, Aleksic Z, Jankovic S, Stankovic P, Kenney EB. Platelet-rich fibrin and bovine porous bone mineral vs. platelet-rich fibrin in the treatment of intra-bony periodontal defects. *J Periodontol Res*. 2012;47(4):409–26.
- Sharma A, Pradeep A. Autologous Platelet-Rich Fibrin in the Treatment of Mandibular Degree II Furcation Defects: A Randomized Clinical Trial. *J Periodontol*. 2011;82(10):1396–403.
- Prichard JF. The diagnosis and management of vertical bony defects. *J Periodontol*. 1983;54(1):29–35.
- Hench LL. Bioceramics: From Concept to Clinic. *J Am Ceram Soc*. 1991;74(7):1487–510.
- Rahaman MN, Day DE, Bal BS, Fu Q, Jung SB, Bonewald LF. Bioactive glass in tissue engineering. *Acta Biomater*. 2011;7(6):2355–73.
- Anderegge CR, Alexander DC, Freidman M. A bioactive glass particulate in the treatment of molar furcation invasions. *J Periodontol*. 1999;70(4):384–91.
- Al-Harbi N, Mohammed H, Al-Hadeethi Y, Bakry AS, Umar A, Hussein MA. Silica-Based Bioactive Glasses and Their Applications in Hard Tissue Regeneration: A Review. *Pharm Basel Switz*. 2021;14(2):75. doi:10.3390/ph14020075.
- Sohrabi K, Saraiya V, Laage TA, Harris M, Blieden M, Karimbux N. An Evaluation of Bioactive Glass in the Treatment of Periodontal Defects: A Meta-Analysis of Randomized Controlled Clinical Trials. *J Periodontol*. 2012;83(4):453–64.
- Mistry S, Kundu D, Datta S, Basu D. Effects of bioactive glass, hydroxyapatite and bioactive glass - Hydroxyapatite composite graft particles in the treatment of intra-bony defects. *J Indian Soc Periodontol*. 2012;16:241–7.
- Debnath T, Chakraborty A, Pal TK. A clinical study on the efficacy of hydroxyapatite - Bioactive glass composite granules in the management of periodontal bony defects. *J Indian Soc Periodontol*. 2014;18(5):593–600.
- Bhide A, Pratibha PK, Bhat GS. Evaluation of Autogenous Cortical Bone Particulate with Bioactive Glass-Synthetic Hydroxyapatite in Treatment of Periodontal Bone Defects. *Int J Biosci Biochem Bioinforma*. 2012;p. 36–45.
- Lekovic V, Camargo PM, Weinlaender M, Vasilic N, Kenney EB. Comparison of platelet-rich plasma, bovine porous bone mineral, and guidea ad tissue regeneration versus platelet-rich plasma and bovine porous bone mineral in the treatment of intra-bony defects: a reentry study. *J Periodontol*. 2002;73(2):198–205.
- Camargo PM, Lekovic V, Weinlaender M, Vasilic N, Madzarevic M, Kenney EB, et al. Platelet-rich plasma and bovine porous bone mineral combined with guided tissue regeneration in the treatment of intra-bony defects in humans. *J Periodontol Res*. 2002;37(4):300–6.
- Lekovic V, Camargo PM, Weinlaender M, Vasilic N, Aleksic Z, Kenney EB. Effectiveness of a combination of platelet-rich plasma, bovine porous bone mineral and guided tissue regeneration in the treatment of mandibular grade II molar furcations in humans. *J Clin Periodontol*. 2003;30(8):746–51.
- Sharma A, Pradeep AR. Treatment of 3-wall intra-bony defects in patients with chronic periodontitis with autologous platelet-rich fibrin: a randomized controlled clinical trial. *J Periodontol*. 2011;82(12):1705–17.
- Patel GK, Gaekwad SS, Gujjari SK, Vek SC. Platelet-Rich Fibrin in Regeneration of Intra-bony Defects: A Randomized Controlled Trial. *J Periodontol*. 2017;88(11):1192–201.
- Shah M, Patel J, Dave D, Shah S. Comparative evaluation of platelet-rich fibrin with demineralized freeze-dried bone allograft in periodontal intra-bony defects: A randomized controlled clinical study. *J Indian Soc Periodontol*. 2015;19(1):56–60.
- Bodhare GH, Kolte AP, Kolte RA, Shirke PY. Clinical and radiographic evaluation and comparison of bioactive bone alloplast morsels when used alone and in combination with platelet-rich fibrin in the treatment of periodontal intra-bony defects-A randomized controlled trial. *J Periodontol*. 2019;90(6):584–94.
- Miron RJ, Moraschini V, Kobayashi MF, Zhang Y, Kawase T, Cosgarea R. Use of platelet-rich fibrin for the treatment of periodontal intra-bony defects: a systematic review and meta-analysis. *Clin Oral Investig*. 2021;25(5):2461–78.
- Ye L, Mashrah MA, Ge L, Fang Y, Guo X, Ge Q. Network meta-analysis of platelet-rich fibrin in periodontal intra-bony defects. *J Oral Pathol Med*. 2023;52(3):206–21.
- Choukroun J, Diss A, Simonpieri A, Girard MO, Schoeffler C, Dohan SL. Platelet-rich fibrin (PRF): a second-generation platelet concentrate. Part IV: clinical effects on tissue healing. *Oral Surg Oral Med Oral Pathol Oral Radiol Endod*. 2006;101(3):56–60.


37. Thorat M, Pradeep AR, Pallavi B. Clinical effect of autologous platelet-rich fibrin in the treatment of intra-bony defects: a controlled clinical trial. *J Clin Periodontol.* 2011;38(10):925–57.
38. Corso D, Sammartino M, Re DM, Ehrenfest D. Clinical evaluation of a modified coronally advanced flap alone or in combination with a platelet-rich fibrin membrane for the treatment of adjacent multiple gingival recessions: a 6-month study. *J Periodontol.* 2009;80(2):1697–9.

**Presanthila Janam**, Professor  <https://orcid.org/0000-0003-4381-7910>

**Bindu Radhakrishnan Nayar**, Professor and Head  <https://orcid.org/0000-0002-4000-2655>

**Lekshmi A Jayasree**, Senior Lecturer  <https://orcid.org/0000-0003-0515-9603>

## Author biography

**Rekha P Radhakrishnan**, Assistant Professor  <https://orcid.org/0000-0001-9858-4814>

**Cite this article:** Radhakrishnan RP, Janam P, Nayar BR, Jayasree LA. Efficacy of autologous platelet rich fibrin (PRF) and hydroxyapatite bioactive glass (HABG) in the management of intra bony defects -A randomized controlled trial. *IP Int J Periodontol Implantol* 2023;8(4):212-221.