



Case Report

Regenerative approach for root coverage with platelet-rich fibrin: A case report

Tulika Rani Roy^{1,*}, Nimisha Kumari¹, Raziya Perween¹, Roopanshi Mehrotra²,
Anamika Singh¹

¹Dept. of Periodontology, Inderprastha Dental College & Hospital, Ghaziabad, Uttar Pradesh, India

²Dept. of Periodontology, Career Post Graduate Institute of Dental Sciences and Hospital, Lucknow, Uttar Pradesh, India



ARTICLE INFO

Article history:

Received 26-08-2023

Accepted 14-09-2023

Available online 22-09-2023

Keywords:

Gingival Recession (GR)

Periodontal defect

Coronally advanced Flap (CAF)

Platelet rich fibrin (PRF)

Miller's class II recession

ABSTRACT

Gingival recession (GR) exposes the root surface and causes sensitivity, if left untreated it will lead to the root exposure with the bone loss around the teeth and eventually more complex periodontal defect. There are numerous surgical interventions are present in literature for treating gingival recession, the Coronally advanced flap (CAF) surgery is one of the most common procedures for the treatment. The Predictability of the treatment outcome can be increased by combining with other regenerative procedures. The platelet rich fibrin (PRF) is preferred to combine with CAF. PRF is prepared as the fibrin membrane that contains constituents of blood and favours healing at the surgical site. In this case report we are presenting treatment of Miller's class II recession with CAF combining PRF.

This is an Open Access (OA) journal, and articles are distributed under the terms of the [Creative Commons Attribution-NonCommercial-ShareAlike 4.0 License](https://creativecommons.org/licenses/by-nc-sa/4.0/), which allows others to remix, tweak, and build upon the work non-commercially, as long as appropriate credit is given and the new creations are licensed under the identical terms.

For reprints contact: reprint@ipinnovative.com

1. Introduction

Gingival recession is common aesthetic problem which leads to apical migration of gingiva beyond the cemento-enamel junction (CEJ). It can be considered as the gateway for further destruction of periodontium if left untreated with impaired aesthetics, exposure of root surface bone resorption and eventually tooth loss.¹ In periodontal surgery our elucive goal is to attain the maximum attachment level as well as regeneration of the lost periodontal tissue.

There are several treatment protocols has been suggested for the treatment of gingival recession such as subepithelial connective tissue grafting (SCTG) procedures,² the free gingival grafting procedures,³ laterally positioned flap, Coronally advanced flap, tissue regeneration with different membranes, enamel matrix derivatives (EMD),⁴ platelet rich fibrin with CAF,⁵ SCTG with CAF is considered as gold

standard for the root coverage procedures, however this technique gives excellent result but the requirement of secondary surgical site is the major disadvantage. Post operative pain and delayed healing in palatal area is most common complications.

To overcome this, the use of PRF as autologous graft material has been used with CAF. PRF is second generation platelet concentrate and autologous leukocyte concentrate⁶ and prepared as a single fibrin membrane, it contains different constituents of blood and releases growth factors such as transforming growth factor β , platelet-derived growth factor and vascular endothelial growth factor which leads to healing and regeneration.⁷

PRF is a manipulative fibrin membrane which can be easily adapted and sutured. In periodontal surgeries PRF used in the infrabony defects, furcation defects, sinus floor elevation and gingival recession procedures. In this case report we are presenting treatment of Millers class II gingival recession with CAF and PRF.

* Corresponding author.

E-mail address: tulikaroy162@gmail.com (T. R. Roy).

2. Case Report

A 24 years old female patient reported at the outpatient department of Periodontology with the chief complain of sensitivity in lower front teeth region. On examination Miller class II gingival recession was diagnosed in mandibular anteriors irt 31 and 41. For the management of gingival recession root coverage procedure was planned for the management gingival recession CAF along with PRF membrane was planned.

2.1. Pre-surgical procedure

The procedure was explained and written informed consent was obtained from the patient. Patient's medical history was evaluated and was non contributory. Preparation of the surgical site was done by scaling and root planning and then surgery was planned. Pre-operative measurements were taken using "university of North carolina Probe-15".

2.2. Preparation of platelet rich fibrin

The protocol developed by choukroun et al.⁸ was used for the preparation of PRF. 10 ml blood volume was drawn from median cubital vein in sterile tube and immediately centrifugation was done at 2700 revolution per minute (rpm) for 12 minutes. After the centrifugation three layers can be distinguished, the topmost layer was containing acellular plasma, in the second layer fibrin clot was present and third layer contains RBCs (red blood cells). The separation of fibrin clot was done with the help of sterile tweezers. The fibrin clot was slightly squeezed between the gauge pieces to obtain a thin fibrin membrane.

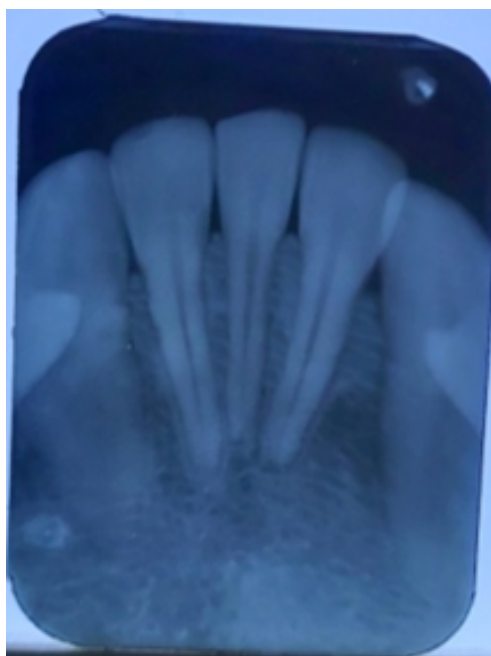


Fig. 2: IOPAR

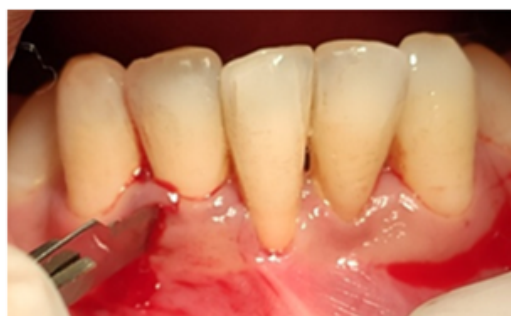

Fig. 3: Incision

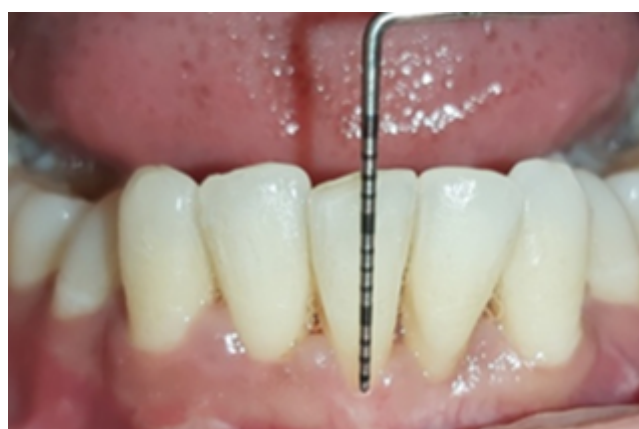

Fig. 1: ClassII Recession irt 31,41

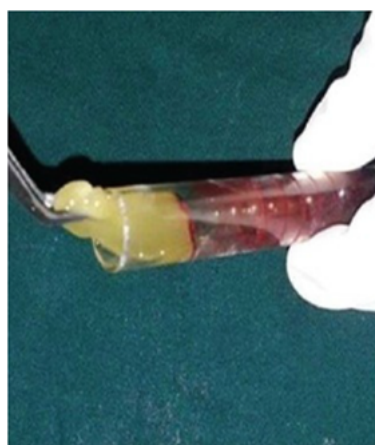


Fig. 4: Prepared PRF

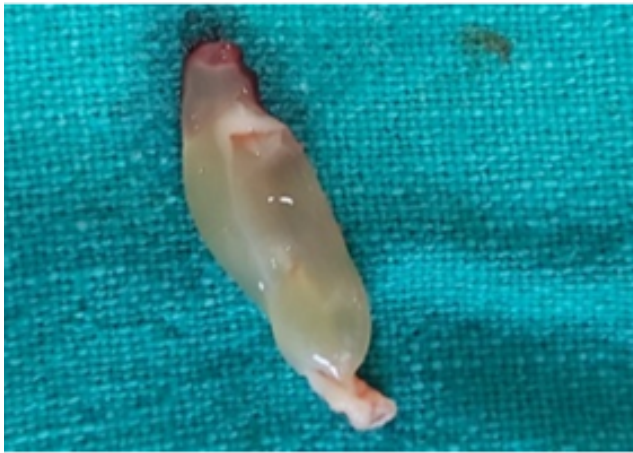

Fig. 5: Placement of PRF

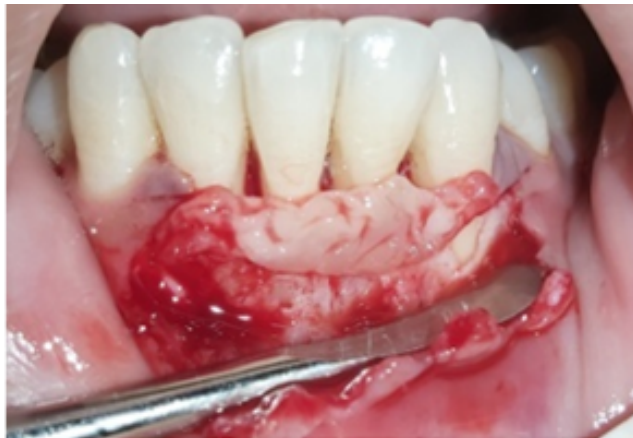

Fig. 6: PRF membrane

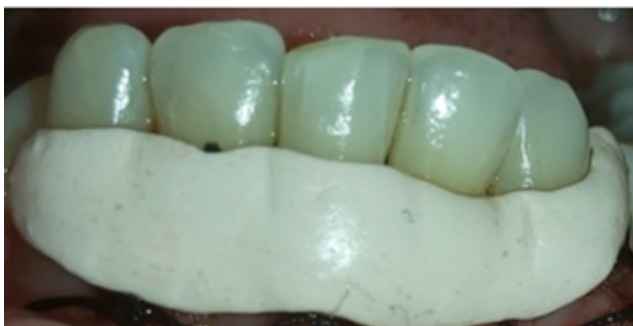

Fig. 7: Periodontaldressing placed after suturing

3. Discussion

For the management of gingival recession CAF is simple procedure but when it is combined with PRF it gives excellent result. The goal of periodontal plastic surgery is to achieve the aesthetics as well as the regeneration of lost periodontal tissues.⁹ When it comes to restoring tissue the treatment of gingival recession becomes more challenging to provide the aesthetic and functional well being of the patient. In such cases root coverage not only corrects the aesthetics but it also relieves the hypersensitivity of the tooth.¹⁰ Treatment with PRF continuously supplies the growth factors in the required area and enhances the proliferation of fibroblasts¹¹ and ultimately leads regeneration. It is non-toxic and non immunereactive as it is prepared from patients own blood. There are many studies which suggests that CAF with PRF for recession coverage procedures presents excellent result.^{12–14}

During healing phase the alpha granules of platelets, that are rich with various growth factors and cytokines, are released continuously for 7 days which leads to cell proliferation, collagen synthesis and formation of osteoid.

In present case report significant root coverage was gained, within the limits PRF provides a living scaffold of tissue that can treat the gingival recession with more stable results. Keeping in mind that the PRF gives advantage as a membrane in root coverage procedures, it should be always placed 1mm coronally to the cemento enamel junction (CEJ) and left exposed to the oral cavity. In this case the healing was unevenful and there was no signs of infections. Many studies such as studies by *Dohan et al.*¹⁵ and *Thamaraiselvan et al.*¹⁶ shown significant results with CAF and PRF whereas studies done by *Moraschini et al.*¹⁷ and *castro et al.*¹⁸ shows there was no any benefit of PRF on periodontal regeneration. Recent studies demonstrated use of PRF and advanced PRF (A-PRF) presents excellent treatment results for gingival recession abnormalities.^{19–21} Although there are more studies required to evaluate the effectiveness of the PRF for the regenerative procedures.

4. Conclusion

This article presents the regenerative approach for root coverage with coronally advanced flap with platelet rich fibrin. Gingival recession causes aesthetic and functional problem, the regenerative capability of platelet rich fibrin makes the treatment more promising and satisfactory.

5. Source of Funding

None.

6. Conflict of Interest

None.

References

- Zucchelli G, Testori T, Sanctis D, M. Clinical and anatomical factors limiting treatment outcomes of gingival recession: A new method to predetermine the line of root coverage. *J Periodontol.* 2006;77:714–35.
- Langer B, Langer L. Subepithelial connective tissue graft technique for root coverage. *J Periodontol.* 1985;56(12):715–20.
- Sullivan HC, Atkins JH. Free autogenous gingival grafts. 3. Utilization of grafts in the treatment of gingival recession. *Periodontics.* 1968;6(4):152–60.
- Moses O, Artzi Z, Sculean A. Comparative study of two root coverage procedures: A 24-month follow-up multicenter study. *J Periodontol.* 2006;77(2):195–202.
- Aroca S, Keglevich T, Barbieri B, Gera I, Etienne D. Clinical evaluation of a modified coronally advanced flap alone or in combination with a platelet-rich fibrin membrane for the treatment of adjacent multiple gingival recessions: A 6-month study. *J Periodontol.* 2009;80(11):244–52.
- Dohan DM, Choukroun J, Diss A. Platelet-rich fibrin (PRF): A second-generation platelet concentrate. Part I: Technological concepts and evolution. *Oral Surg Oral Med Oral Pathol Oral Radiol Endod.* 2006;101(3):37–44.
- Zucchelli G. Advanced flaps with and without vertical releasing incisions for the treatment of multiple gingival recessions: A comparative controlled mixed clinical trial. *J Periodontol.* 2000;80:1083–94.
- Choukroun J, Diss A, Simonpieri A, Girard MO, Schoeffler C, Dohan SL. Platelet-rich fibrin (PRF): A second-generation platelet concentrate. Part IV: Clinical effects on tissue healing. *Oral Surg Oral Med Oral Pathol Oral Radiol Endod.* 2006;101(3):56–60.
- Sanz M, Simion M. Working Group 3 of the European Workshop on Periodontology. Surgical techniques on periodontal plastic surgery and soft tissue regeneration: Consensus report of Group 3 of the 10th european workshop on periodontology. *J Clin Periodontol.* 2014;41(15):92–7.
- Chambrone L, Pannuti CM, Tu YK, Chambrone LA. Evidence-based periodontal plastic surgery II. A individual data meta-analysis for evaluating factors in achieving complete root coverage. *J Periodontol.* 2012;83:477–90.
- Anitua E, Sánchez M, Zalduendo MM, Fuente MDL, Prado R, Orive G. Fibroblastic response to treatment with different preparations rich in growth factors. *Cell Prolif.* 2009;42(2):162–70.
- Corso D, Sammartino M. Clinical evaluation of a modified coronally advanced flap alone or in combination with a platelet-rich fibrin membrane for the treatment of adjacent multiple gingival recessions: A 6-month study. *J Periodontol.* 2009;80:1694–701.
- Aroca S, Keglevich T, Barbieri B, Gera I, Etienne D. Clinical evaluation of a modified coronally advanced flap alone or in combination with a platelet-rich fibrin membrane for the treatment of adjacent multiple gingival recessions: A 6-month study. *J Periodontol.* 2009;80(2):244–52.
- Santamaria MP. Connective tissue graft plus resin-modified glass ionomer restoration for the treatment of gingival recession associated with non-carious cervical lesion: A randomized-controlled clinical trial. *J Clin Periodontol.* 2009;36(9):791–9.
- Dohan DM, Corso D, Diss M. Three-dimensional architecture and cell composition of a Choukroun's platelet-rich fibrin clot and membrane. *J Periodontol.* 2010;81:546–55.
- Thamaraiselvan M, Elavarasu S, Thangakumaran S. Comparative clinical evaluation of coronally advanced flap with or without platelet rich fibrin membrane in the treatment of isolated gingival recession. *J Indian Soc Periodontol.* 2015;19:66–71.
- Moraschini V, Barboza ED. Use of platelet-rich fibrin membrane in the treatment of gingival recession: A systematic review and meta-analysis. *J Periodontol.* 2016;87(3):281–90.
- Castro AB, Meschi N, Temmerman A. Regenerative potential of leucocyte and platelet rich fibrin. Part A: Intra-bony defects, furcation defects and periodontal plastic surgery: A systematic review and meta-analysis. *J Clin Periodontol.* 2017;44:67–82.
- Parihar AS, Narang S, Dwivedi S, Narang A, Soni S. Platelet-rich fibrin for root coverage: A plausible approach in periodontal plastic and esthetic surgery. *Ann Afr Med.* 2021;20(3):241–4.
- Rich P. Fibrin in Single and Multiple Coronally Advanced Flap for Type I Recession: An Updated Systematic Review and Meta Analysis. *Medicina.* 2021;57(2):144. doi:10.3390/medicina57020144.
- Advanced Platelet-Rich Fibrin and Connective Tissue Graft for Treating Marginal Tissue Recessions: A Randomized, Controlled Split-Mouth Study. *Cureus.* 2023;15(3):35761–35761.

Author biography

Tulika Rani Roy, Senior Lecturer  <https://orcid.org/0009-0008-9524-3051>

Nimisha Kumari, Reader

Raziya Perween, Senior Lecturer

Roopanshi Mehrotra, Post Graduate Student

Anamika Singh, Senior Lecturer

Cite this article: Roy TR, Kumari N, Perween R, Mehrotra R, Singh A. Regenerative approach for root coverage with platelet-rich fibrin: A case report. *IP Int J Periodontol Implantol* 2023;8(3):166-169.