

Content available at: <https://www.ipinnovative.com/open-access-journals>

IP International Journal of Periodontology and Implantology

Journal homepage: <https://www.ijpi.in/>

Case Series

Multifaceted presentation of peripheral ossifying fibroma: Case series spanning three age groups

Ambili Gopalakrishnan^{1,*}, Baiju Radhamoni Madhavanpillai²,
Binitta Paul Kannappillil¹, Jithin Balan³

¹Dept. of Periodontics, Government Dental College Thiruvananthapuram, Thiruvananthapuram, Kerala, India

²Dept. of Periodontics, Govt. Dental College, Kottayam, Kerala, India

³Dept. of Periodontics, General Hospital, Kalpetta, Kerala, India



ARTICLE INFO

Article history:

Received 07-08-2022

Accepted 18-08-2022

Available online 17-09-2022

Keywords:

Peripheral ossifying fibroma

Localized gingival growth

Parakeratinised stratified squamous epithelium

Gingivectomy

ABSTRACT

A benign focal non-reactive lesion that has been reported in the literature under a variety of names, Calcifying Fibroblastic Granuloma or Peripheral Ossifying Fibroma (POF) can occur usually in a younger age group with a female predilection. POF can be perplexing to a clinician as the clinical similarity with pyogenic granuloma or fibroma is astounding. It can cause erosion of bone and underlying structures with a recurrence rate ranging from 16% - 20%. So, the lesion must be identified by histological investigation. In this paper, we describe about three individuals in their 2nd, 5th, and 9th decades of life who were all diagnosed with POF.

Key Messages: POF can be perplexing to a clinician as the clinical similarity with pyogenic granuloma or fibroma is astounding. The lesion has a predilection for females of younger age group. Only 0.5% cases of POF have been reported in the third decade of life which makes the third case a unique one. The three cases presented here were managed using three different surgical approaches.

This is an Open Access (OA) journal, and articles are distributed under the terms of the [Creative Commons Attribution-NonCommercial-ShareAlike 4.0 License](https://creativecommons.org/licenses/by-nc-sa/4.0/), which allows others to remix, tweak, and build upon the work non-commercially, as long as appropriate credit is given and the new creations are licensed under the identical terms.

For reprints contact: reprint@ipinnovative.com

1. Introduction

One of the most common lesions in the oral cavity is localized gingival growths, and Peripheral Ossifying Fibroma (POF) also known as calcifying fibroblastic granuloma, is one of them. POF comprises of 9.6% of all oral cancers and 3.1% of all oral malignancies.¹ The 2017 AAP classification saw the reintroduction of 'Epulides', a non-specific term that is often applied to exophytic processes originating from gingiva. An epulide, also known as POF / Ossifying fibroid epulis, is a soft tissue growth that often originates only from the gingiva and is localized, reactive, and tumor-like in appearance. It can be pedunculated or sessile, may be red to pink in color, and may

result in the separation of adjoining teeth or alveolar bone resorption. Clinically and radiographically, it can mimic squamous cell carcinoma or other metastatic lesions.² With a high rate of recurrence and its clinical similarity with other malignant neoplasms, it is important to identify the lesion early using biopsy. A possible origin from cells of the periodontal ligament has been proposed, despite the fact that the etiopathogenesis is unclear.³ Here we discuss 3 cases that were encountered in different age groups. All three patients presented with exophytic mass in the gingiva which varied in color from pink to red and experienced difficulties with phonation and function due to the swelling.

* Corresponding author.

E-mail address: ambili.gk85@gmail.com (A. Gopalakrishnan).

2. Case Description

2.1. Case 1. Peripheral ossifying fibroma presenting in a child

2.1.1. Clinical presentation

Having a slow-growing, painless growth in the lower gums, an 11-year-old boy visited the clinic in February 2020. It was first noticed 3 months back and the patient used to bite on it. Occasionally, bleeding occurred while brushing. Intra oral examination revealed an oval reddish-pink swelling of about 1×0.5 cm in relation to buccal and interdental gingiva of 45 predominantly. [Figure 1 (a), (b)] Swelling was non-tender and sessile with a rubbery consistency. There was no bleeding on probing, tenderness, or exudation on the involved gingiva. Lesion reached the occlusal plane and also showed indentations left by the maxillary premolar that was occluding. There were no caries or tenderness on the involved teeth. The prior dental and medical histories of the patient were not relevant. The overall state of oral hygiene was good, with a modest amount of calculus and plaque but no evidence of tooth decay.

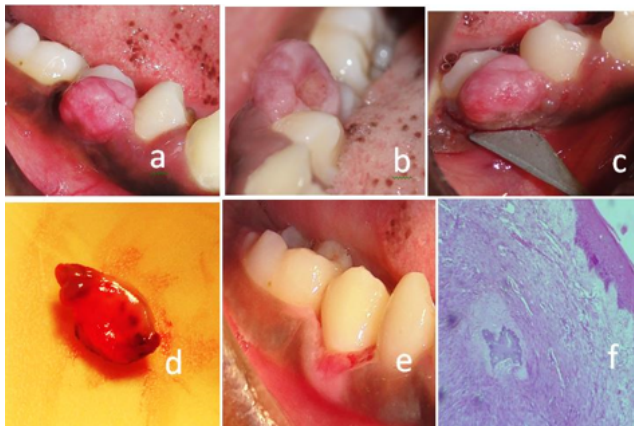


Fig. 1: (a) photograph showing gingival overgrowth in relation to 45. Buccal view (b) photograph showing gingival overgrowth in relation to 45. Occlusal view (c) photograph showing excision of growth with gingivectomy knife (d) photograph showing excised tissue (e) photograph showing post operative view at 1 week (f) photograph showing histopathological picture of lesion in relation to 45 at 40x magnification.

Intraoral periapical radiographic examination showed no widening of periodontal ligament space, radiolucency, or crestal bone loss in relation to 45. The results of routine blood tests were perfectly normal. Prior to surgery, informed consent was obtained.

2.1.2. Diagnosis & management

Fibroma, Pyogenic granuloma (PG), and Peripheral giant cell granuloma (PGCG) were all on the list of possible diagnosis. After professional mechanical plaque removal and oral hygiene instructions, the patient was reevaluated at

6 weeks. At re-evaluation, there was a marked improvement in oral hygiene, but the swelling persisted. Under adequate local anesthesia, an excision biopsy was performed with an external bevel gingivectomy using a Kirkland knife. [Figure 1 (c)] Entire mass along with 1mm of adjacent tissue was removed. [Figure 1 (d)]. The remaining local irritants were removed from adjacent teeth by scaling the teeth. Hemostasis was attained. The periodontal dressing Coe pack was applied. Antibiotics, as well as analgesics, were prescribed. Wound healing was satisfactory at 1 week [Figure 1 (e)].

2.1.3. Histopathology

Microscopic examination revealed hyperplastic parakeratinised stratified squamous epithelium which is atrophic in many areas. Engorged blood vessels and forming blood vessels are seen. The massive proliferation of fibroblasts was noted. Few areas of ossification are also seen in the connective tissue stroma. Connective tissue is densely infiltrated with a moderate proliferation of chronic inflammatory cells chiefly plasma cells and lymphocytes. A diagnosis of POF was confirmed based on the histopathological findings. [Figure 1 (f)].

2.2. Case 2. Peripheral Ossifying Fibroma Presenting in An Adult

2.2.1. Clinical presentation

A 46-year-old woman visited the clinic in December 2019 with a complaint of enlarged gums on the right side of her lower jaw. The enlargement was noticed two years back and was not increasing in size. There was no prior history of the area being painful or bleeding. There was no contributory medical history or drug history. She had not undergone any dental treatment for the said complaint. Calculus and plaque were found during the intraoral examination as a result of the patient's inadequate oral hygiene. A sessile, pebbled, pale pink oval enlargement of size 1×0.75 cm was present on the labial interdental gingiva between 43 and 44 extending to the marginal gingiva up to the mesial surface of 45. [Figure 2 (a)] There was no exudation from the enlargement when it was palpated. It was non-tender and firm. No palpable lymph nodes were seen.

Intra oral periapical radiographic assessment exhibited no widening of periodontal ligament space, radiolucency, or crestal bone loss in relation to the 43, 44 regions. [Figure 2 (b)] The results of routine blood tests were normal. Consent for the procedure was obtained.

2.2.2. Diagnosis and management

The differential diagnosis includes fibrous hyperplasia, pyogenic granuloma, and PGCG.

The patient was referred for surgical excision six weeks after professional mechanical plaque removal and dental hygiene recommendations because the swelling had

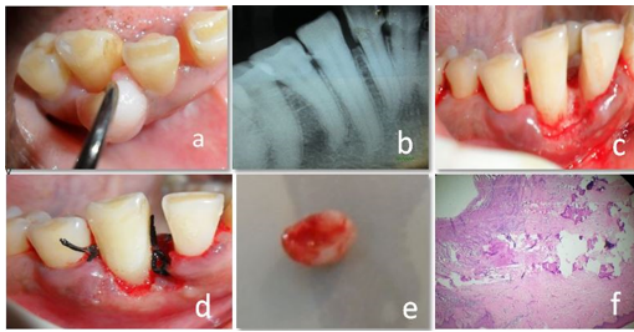


Fig. 2: (a) photograph showing gingival overgrowth in the interdental papilla between 43 and 44, buccal view (b) Intraoral radiographic picture of the lesion in relation to 43, 44 (c) photograph showing the site 43, 44 after excision of the lesion (d) photograph showing sutures in place (e) photograph showing excised tissue (f) photograph showing histopathological picture of lesion in relation to 43, 44 at 40x magnification.

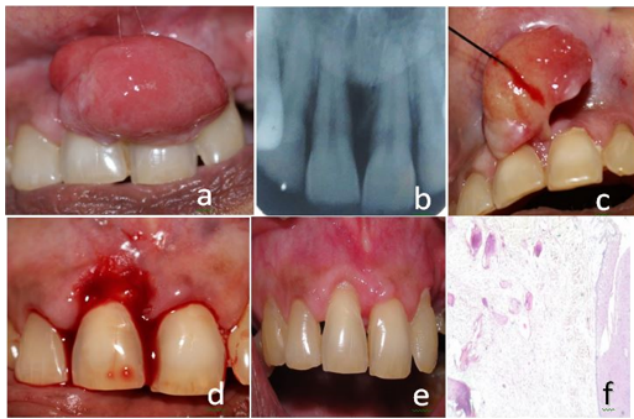


Fig. 3: (a) photograph showing gingival overgrowth in relation to 11 and 21, buccal view (b) Intra oral radiographic picture of the lesion in relation to 11 with moderate bone loss (c) photograph showing the lesion being lifted with the help of stay suture (d) photograph showing the site 11,21 after excision of the lesion (e) photograph showing postoperative view at 1 week (f) photograph showing histopathological picture of lesion in relation to 11,21 at 40x magnification.

persisted. Internal bevel gingivectomy was planned for the surgery. As far as possible apical to the growth was where the first scalloped internal bevel incision was performed under local anesthetic. After making the initial internal bevel incision, a second crevicular incision was performed until it reached the base of the pseudo-pocket. It was decided to remove the excision by making a third interdental incision in the adjacent interproximal area. [Figure 2 (c)] Removal of local irritants from adjacent teeth was done by scaling them. The flap was examined for any tissue tags, then sutured using non-resorbable 3-0 silk sutures. [figure 2 (d)] Both labial and lingual applications of non-eugenol Coe-pack was given. Suture removal was scheduled for one

week after the procedure, and post-operative instructions were provided. The tissue was sent for histopathological examination. [Figure 2 (e)] At 1-week wound healing was satisfactory.

2.2.3. Histopathology

An inspection under a microscope showed tissue coated in the stratified squamous epithelium that was parakeratinized. Underlying connective tissue is densely collagenous with focal inflammatory cell infiltrate. POF was diagnosed based on the presence of calcified masses in the connective tissue. [Figure 2 (f)]

2.3. Case 3. Peripheral ossifying fibroma presenting in old age

An 85-year-old woman who complained of recurring swelling in the upper anterior area visited the clinic in July 2019. She had noticed a similar swelling in the same region a year back which interfered with regular oral hygiene measures and underwent excision for the same. The lesion reappeared around six months back at the same site. Since then it had been increasing in size. Her medical history revealed she had mild hypertension for which she was not taking any medications. There was no other relevant medical or drug history in the patient's past. The extraoral lesion had resulted in obliteration of the philtrum and a swollen appearance of the left upper lip. Intra oral examination revealed a reddish-pink pedunculated mass of about 2.5cm x 2cm x 1.8cm originating from the interdental papilla between 11 and 21 which extends to the attached gingiva of 11 [Figure 3 (a)]. It covered the cervical aspect of 11 and 21 up to its middle third and extended apically obliterating the vestibule covering the labial frenum. The swelling was non-tender, rubbery in consistency and there was no ulceration, pus discharge, or bleeding. Her oral hygiene was poor with multiple missing teeth and root stumps and a moderate amount of plaque and calculus deposits. There was no involvement of lymph nodes.

Radiographic examination revealed widening of periodontal ligament cells and moderate bone loss around 11 [Figure 3 (b)]. Lab investigation revealed a normal hematological profile. Consent was obtained from the physician considering the age and hypertensive status of the patient regarding the fitness for the procedure. There was no contraindication for periodontal therapy. The patient had given their permission for the procedure to proceed.

2.3.1. Diagnosis & management

Pyogenic granuloma was provisionally diagnosed. Fibroma, PGCG, and POF were among the possible diagnoses that may be made. After professional mechanical plaque removal and oral hygiene instructions, the patient was reevaluated at 6 weeks. Excision biopsy using the ledge and wedge technique was planned. Under local anaesthesia, the

lesion was lifted with the help of a stay suture to expose the stalk and base [Figure 3 (c)]. The lesion was excised in total from the base. Using internal bevel, crevicular and horizontal incisions flap was raised and adjacent tooth and tissue were curetted [Figure 3 (d)]. The tissue was sent for histopathological examination. At 1 week wound healing was satisfactory [Figure 3 (e)].

2.3.2. Histopathology

Microscopy of serial sections revealed stratified squamous epithelium, hyperplastic in some areas, and atrophic in other areas. Connective tissue stroma showed calcifications in the form of trabecular bone inter dispersed within the hypercellular stroma. The stroma is mainly composed of proliferating, plump fibroblasts and endothelial cells. Occasionally hyalinized areas were noted adjacent to the epithelium-connective tissue interface. Vascularity was moderate. [Figure 3 (f)] The findings were consistent with that of POF.

3. Discussion

9.6% of all gingival lesions are caused by POF, which is a reactive lesion.⁴ Eversole & Rovin⁵ stated that PG, POF, and PGCG share many clinical and histologic features and irritation may elicit a variety of histologic reactions. Additionally, it is suggested that POF is not a pyogenic granuloma in transition but rather a distinct clinical entity.

The etiology of POF is unclear. There are 2 main schools of thought:

1. The fibrous maturation and calcification of PG may develop as POF
2. It could be brought on by periosteum or periodontal ligament cell inflammatory hyperplasia.⁶

The inflammatory reaction is brought on by the triggering causes, which include calculus, subgingival plaque, poor dental restorations, dental appliances, bacteria, and food lodgment.⁷ In all the three cases presented here, oral hygiene was poor with heavy deposits of plaque and calculus. POF may be influenced by hormonal factors as well. The lesion usually presents in a younger age group with a predilection for females. Only 0.5% of cases of POF have been reported in the third decade of life which makes the third case a unique one.⁸ Hence we must always be cautious to avoid misdiagnosis of the lesion which has a multifaceted presentation. Although the majority of the cases of alveolar bone involvement are not severe, it is possible to identify signs of alveolar bone erosion, calcification, widening of the periodontal ligament gap,⁶ thicker lamina dura, and tooth migration with interdental bone loss.⁹

Pyogenic granuloma, PGCG, and POF are among the differential diagnosis. To describe the appearance of the

ulcerated, smooth, or lobulated, sessile or sessile mass that is red to pink, the term "pyogenic granuloma/vascular epulis" is most appropriate. Although PGCG and POF have comparable clinical characteristics, POF lacks PGCG's purple or sometimes blue to brownish color.² It may be seen under a microscope as scattered large cells inside a fibrous stroma. An extensive odontogenic epithelium and sometimes dysplastic dentin or cementum-like calcifications may be seen in peripheral odontogenic fibroma, a benign odontogenic tumor of fibroblastic origin.¹⁰

The recommended course of action is surgery, which entails curettage of the osseous floor and excision of the lesion. To fully remove any irritant, it is important to thoroughly remove the lesion down to the periosteum and clean the teeth adjacent to it of any deposits.¹¹ The 3 cases described here were done using 3 different techniques. The first case presented with sufficient attached gingiva width and was suitable for the external bevel gingivectomy procedure. The attached gingiva width was less in the second case which mandated the use of internal bevel gingivectomy. The ledge and wedge technique was used in the third case as it allows for primary incision placement as opposed to the traditional flap and permits access to the underlying structures.¹² Laser excision can be a good alternative but the evidence base is weak and long-term studies have to come up due to the chances of recurrence.¹³

Due to the propensity for incompletely excised lesions to come back and the 16–20% recurrence rate noted by Cundiff & Eversole, close postoperative follow-up is necessary.¹⁴ All three cases have been closely followed up for 2 years and no recurrence is detected till now.

4. Conclusion

Histopathological confirmation is required since POF is a benign, slowly progressing lesion with modest development that is challenging to detect clinically. The chosen course of therapy is complete surgical excision down to the periosteum, and because of the high risk of recurrence, thorough post-operative monitoring is necessary.

5. Source of Funding

None.

6. Conflict of Interest


None.

References

1. Mishra MB, Bhishen KA, Mishra S. Peripheral ossifying fibroma. *J Oral Maxillofac Pathol.* 2011;15(1):65–73.
2. Holmstrup P, Plemons J, Meyle J. Non plaque-induced gingival diseases. *J Clin Periodontol.* 2018;89(1):28–43.
3. Kumar SK, Ram S, Jorgensen MG, Shuler CF, Sedghizadeh PP. Multicentric Peripheral Ossifying fibroma. *J Oral Sci.* 2006;48(4):239–82.

4. Layfield LL, Shopper TP, Weir JC. A diagnostic survey of biopsied gingival lesions. *J Dent Hyg.* 1995;69(4):175–9.
5. Eversole LR, Rovin S. Reactive lesions of the gingiva. *J Oral Pathol.* 1972;5(1):30–8.
6. Satish BN, Kumar P. Peripheral ossifying fibroma of the hard palate: A case report. *Int J Dent Clin.* 2010;2(1):30–4.
7. Chatterjee A, Ajmera N, Singh A. Peripheral cemento-ossifying fibroma of maxilla. *J Indian Soc Periodontol India.* 2010;14(3):186–95.
8. Reddy GV, Reddy J, Ramlal G, Ambati M. Peripheral Ossifying fibroma: Report of two unusual cases. *Indian J Stomatol.* 2011;2(2):130–3.
9. Sharma S, Anamika S, Ramachandra SS. Peripheral ossifying fibroma: A clinical report. *Compend Contin Educ Dent.* 2011;32(1):86–90.
10. Baiju CS, Rohatgi S. Peripheral Odontogenic fibroma: A case report and review. *J Indian Soc Periodontol.* 2011;15(3):273–5.
11. Neville BW, Damm DD, Allen CM, Bouquot JE. Oral and Maxillofacial Pathology. The Netherlands: Elsevier; 2004. p. 176.
12. McDonnell HT, Mills MP. Principles and practice of periodontal surgery. *Periodontol Med Surg Implants.* 2004;124(2):188–204.
13. Iyer V, Sarkar S, Kailasam S. Use of the ER, CR; YSGG laser in the treatment of peripheral ossifying fibroma. *Int J Laser Dent.* 2012;2(2):51–6.
14. Rajendran R, Sivapathasundharam B. Shafer's textbook of oral pathology. New Delhi: Elsevier; 2016. p. 182.

Author biography

Ambili Gopalakrishnan, Assistant Professor in Periodontics
 <https://orcid.org/0000-0002-8591-5132>

Baiju Radhamoni Madhavanpillai, Professor of Periodontics

Binitta Paul Kannappillil, Assistant Professor in Periodontics

Jithin Balan, Junior Consultant

Cite this article: Gopalakrishnan A, Madhavanpillai BR, Kannappillil BP, Balan J. Multifaceted presentation of peripheral ossifying fibroma: Case series spanning three age groups. *IP Int J Periodontol Implantol* 2022;7(3):136-140.