



Case Report

Diode laser therapy for peripheral ossifying fibroma: A 2 years follow up

V. V. Alekhya Burli¹, B. Adishesamma¹, M. Gayathri¹, M. Ramesh Babu^{1,*}, R. Arpita¹

¹Dept. of Periodontics, Mamata Dental College, Khammam, Telangana, India



ARTICLE INFO

Article history:

Received 13-05-2022

Accepted 20-05-2022

Available online 10-06-2022

Keywords:

Diode laser

Peripheral Ossifying Fibroma

Cone Beam Computed Tomography

ABSTRACT

In daily practice we can come across many growths in oral cavity, mostly reactive rather than neoplastic, which are difficult to differentiate from one another posing a challenge to dentist. Peripheral ossifying fibroma (POF) is a single benign fibro osseous origin growth of gingiva which occurs due to long standing irritation by plaque, calculus, trauma, restorations, and orthodontic appliances, however the precise etiopathogenesis of POF is unclear. The standard treatment protocol involves surgical excision followed by the biopsy of the lesion. Proper follow up of the lesion is necessary due to its high recurrence. The present case report managed with diode laser excision did not showed any signs of recurrence during the follow up period of 2 years. Minimum bleeding, less postoperative pain, ease of operation and absence of recurrence makes diode laser assisted excision is the better treatment option over conventional scalpel surgery.

This is an Open Access (OA) journal, and articles are distributed under the terms of the [Creative Commons Attribution-NonCommercial-ShareAlike 4.0 License](https://creativecommons.org/licenses/by-nc-sa/4.0/), which allows others to remix, tweak, and build upon the work non-commercially, as long as appropriate credit is given and the new creations are licensed under the identical terms.

For reprints contact: reprint@ipinnovative.com

1. Introduction

Reactive lesions of gingiva are benign lesions, non - neoplastic swellings which occurs as a response to chronic tissue injury. The common reactive lesions on gingiva are pyogenic granuloma, drug induced gingival enlargement, focal fibrous hyperplasia, peripheral giant cell granuloma and peripheral ossifying fibroma.¹

POF comprises about 9% of all gingival growths.² Incidence occurs at the age from 10 to 19 years; female predilection (2- 4 times) with more in Caucasians (71%) compared to Asians (36%). Clinically, POF is < 1.5 cm in diameter nodular painless mass, pedunculated or sessile, ulcerated or erythematous exhibiting similar colour to the adjacent gingiva. Most commonly seen in maxillary anterior tooth region.^{3,4} Treatment consists of excision of the growth and removal of contributing factors of POF.⁵

Laser offers an advanced surgical management of such reactive lesions. Diode laser has been used in intraoral soft tissue lesion excision.⁶ The energy level is absorbed by pigmentation of the soft tissue which makes diode laser an hemostatic agent.⁷ Thus, the present case report attempts to discuss the application of diode laser in effective and successful management of POF.

2. Case Report

A 13-year-old female patient came to the department of periodontics (Mamata dental college, Khammam, Telangana) with a chief complaint of swelling in upper front teeth region for 9 months. Initially the swelling was small which gradually increased to present size. The swelling was painless but associated with difficulty in eating. There was no history of trauma. Patient was systemically healthy. On intraoral examination, lesion showed well-demarcated, non-tender, non-fluctuant, non-pulsatile, non-compressible, firm in consistency, pedunculated growth measuring around

* Corresponding author.

E-mail address: rameshbabu297@gmail.com (M. Ramesh Babu).

2.2cm × 1.2 cm x 1 cm extending from right lateral incisor to left lateral incisor region palatally. The overgrowth was reddish, pedunculated, with ulcerated overlying mucosa, well-defined margins and bleeding on provocation. The indentation of lower teeth were observed on the occlusal aspect of the growth (Figure 1). The oral hygiene status of the patient was moderate.

Examination of IOPA showed inter papillary crestal horizontal bone loss in between 11 & 21. CBCT was taken to rule out any underlying pathology in the palate, showed no abnormality in all the maxillary cross sections (Figure 1).

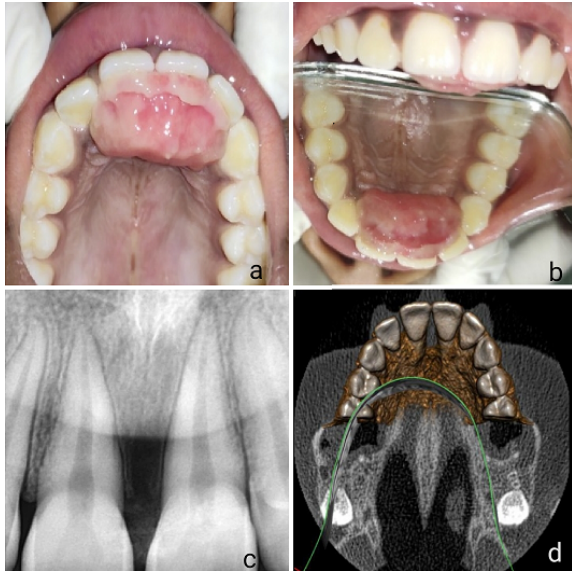


Fig. 1: a: & b:-Pre op view, c:-IOPA, d:-CBCT

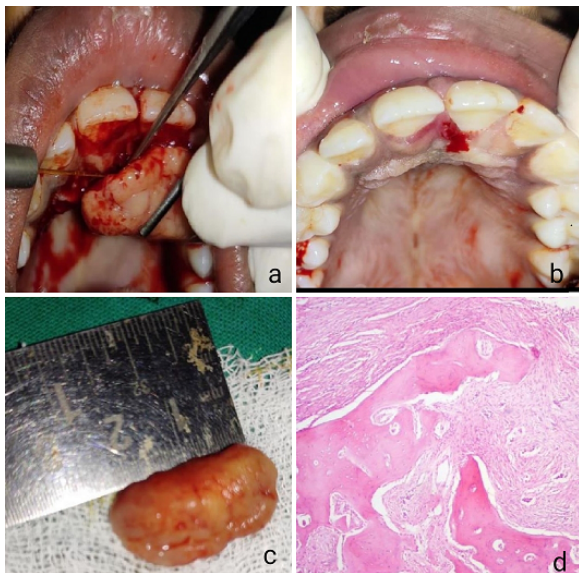


Fig. 2: a:-Excision, b-Immediately after excision, c:- excised tissue, d:- Histology

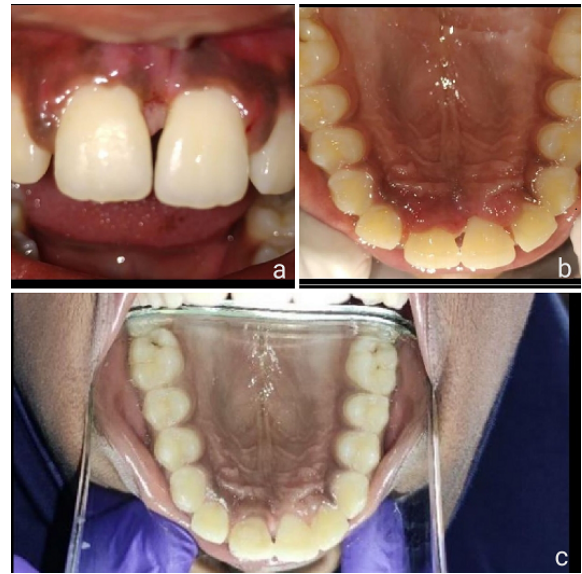


Fig. 3: a: -1 month, b:- 1 year & c:- 2 years

Provisional diagnosis of peripheral giant cell granuloma and differential diagnosis (Table 1) of chronic traumatic fibroma, pyogenic granuloma, and POF were considered based on clinical features.

Oral prophylaxis was done and oral hygiene instructions were given. The patient was recalled for Laser surgery after 2 weeks. After obtaining the patient consent form and required blood investigations, excisional biopsy was done under local anaesthesia using 980nm diode laser (Sirona) using a fiber optic tip of 400 micrometer at 1.2Watts in pulsed mode. The laser tip was applied at the junction of lesion and healthy tissue parallel to the mucosa, and extended in anterioposterior direction, taking care that not to contact with hard tissue. Heamostasis was under control (Figure 2) Sutures were not given. Periodontal pack was placed. Augmentin 625 mg TID was given for 5 days along with hexidine mouth wash. Analgesics were not prescribed as there was no post operative pain. Excised tissue was fixed in 10%formalin and biopsy specimen was sent for histopathological examination.

On histopathological examination, H&E section showed keratinized stratified squamous epithelium with underlying connective tissue. The underlying connective tissue was collagenous with high cellularity and numerous basophilic areas resembling ossifications. In addition, chronic inflammatory cell infiltrate predominantly lymphocytes and engorged blood vessels were also noted. Overall, these histopathological features were suggestive of peripheral ossifying fibroma (Figure 2).

Based on clinical presentation, radiological findings, and histopathological features, a confirmatory diagnosis of POF was made and prognosis was found to be fair.

Table 1: The important differences between peripheral ossifying fibroma, peripheral odontogenic fibroma, counterpart of ossifying fibroma, central odontogenic fibroma, neurofibroma and ameloblastoma.

Peripheral ossifying fibroma (pof)	Peripheral odontogenic fibroma (podf)	Counterpart of ossifying fibroma (cof)	Central odontogenic fibroma (codf)	Neurofibroma (nf)
Classified under benign connective tissue lesion and may arise due to inflammation (reactive).	Classified under odontogenic tumours of ectomesenchyme with or without included epithelium (Neoplasm).	Classified under fibro-osseous lesions and represents an osteogenic tumour (Neoplasm).	Classified under odontogenic tumours of ectomesenchyme with or without included epithelium (Neoplasm).	Classified under benign tumors of nervous tissue origin derived from the cells that constitute the nerve sheath
Common lesion occurring only on gingiva	Rare lesion of gingiva.	Common lesion in long bones, but rare in skull and jaw bones.	Very rare lesion occurring in jaw bones	neurofibromatosis seen either as a solitary lesion or as part of the generalized syndrome of
It does not represent a soft tissue (extraosseus) counterpart of COF.	It is a soft tissue (extraosseous) counterpart of COdF.	Present centrally (intraosseous) a distinct lesion from POF.	Present centrally (intraosseous) - related to POdF	It is a soft tissue lesion Occasional cases of neurofibroma located centrally within the jaw are seen.
No further types of subclassifications	Histologically same as WHO type of COdF in gingiva.	It is of two types: i. Psammomatoid, ii. Juvenile type	It is of two types: i. Simple type (with no mineralization), ii. WHO type (with bone/cementum).	Recently, two subsets have been defined: neurofibromatosis type 1 (NF1), neurofibromatosis type 2 (NF2),

Follow up 1 week after the surgery, a superficial thin layer of denatured collagen was present without any adverse events, and in 1 month, the wound was completely healed. The postoperative healing was uneventful. The patient was recalled at 1 year and 2 year follow up (Figure 3) the outcome of the diode laser surgery was found to be successful with no recurrence. The patient was fully satisfied with the procedure as there was no pain, no recurrence, and no scarring.

3. Discussion

POF is a hyperplastic inflammatory lesion of the gingiva which is fibro osseous in origin and non- neoplastic in nature. In 1872, Menzel first described ossifying fibroma.⁷ There are two types of ossifying fibromas which occurs mostly in craniofacial bones, central and peripheral. The central type arises from the endosteum or periodontal ligament, whereas peripheral type arises from the soft tissue covering the alveolar process.⁵ Local etiology of POF can be attributed to trauma or local irritants such as plaque, calculus, poor quality restorations and ill-fitting dentures.⁸ This case report presents a teenage female patient who is at her puberty and thus the role of hormones can be attributed to its systemic aetiology and locally due to constant trauma from lower incisor.

Most of the cases are not associated with destruction of bone, some are associated with bone involvement.^{4,5} The

IOPA of present case revealed only interdental bone loss in between 11 & 21. CBCT advantaged the patient to rule out any underlying pathology and the extension of lesions but no bony involvement was noted.

The differentiation of the lesions is done by histological examination. Histological origin is thought to come from two sources; one is from the periodontal ligament and other is in the form of pyogenic granuloma initially which gradually enters into the matured fibrous form with calcification.⁸ The basic microscopic pattern of POF is one of a fibrous proliferations associated with the formation of mineralized product. Sometimes the epithelium is ulcerated with the surface covered by fibrinopurulent membrane subjacent to the zone of granulation tissue.⁹ Treatment of POF includes excision by scalpel other methods include electrocautery and lasers. In the present case diode laser was used to minimize post-operative infection, pain, bleeding with uneventful healing. Advantage includes relatively bloodless surgical field, reduce bacteremia, minimal swelling, minimal scarring and wound contraction accelerating recovery and postoperative function. It requires minimal or no suturing, reduction in surgical time with minimal or no anaesthesia and minimal or no post-surgical pain.^{6,7} Diode laser is technique sensitive thus experienced practitioner can only operate with precision. Specific unit is required in a separate sterile operating area which might be costly. An incidence of POF recurrence is 8.9–20%. The reasons for recurrence are incomplete removal of lesion,

failure to removal local irritants, and difficulty in access during surgical manipulation. In a case series by Cundiff and by Eversole & Rovin, 16% and 20% of cases recurred respectively.⁴ This case report stressed the importance of complete excision to the entire depth with the use of diode laser for prevention of recurrence.

The present case report is in accordance with Kranthi et al.⁷ follow-up for 3 months, Ruchi et al.¹⁰ follow-up of 6 months, Anuradha et al.⁶ follow-up of 1 year, who advocated the excision of POF with diode laser and reported minimal complications. This is the first case report which was followed up for 2 years using diode laser. To conclude further multiple cases with longitudinal studies are required to evaluate the outcome.

4. Conclusion

Reactive lesions which are occurring in the oral cavity have to be diagnosed carefully by clinical features and histological examination. POF shows high recurrence rate which requires deeper excisions. Diode laser is one of the choice of treatment for POF. Due to high recurrence rate it has to be carefully followed for longer periods.

5. Source of Funding

None.

6. Conflict of Interest

None.

References

1. Reddy S, Prasad D, Pandit HR. Peripheral ossifying fibroma: A case report and review. *Int J Appl Dent Sci.* 2017;3(2):98–100.
2. Bhaskar SN, Jacoway JR. Peripheral fibroma and peripheral fibroma with calcification: report of 376 cases. *J Am Dent Assoc.* 1966;73(6):1312–32. doi:10.14219/jada.archive.1966.0375.
3. Junior JM, Keim FS, Kreibich MS. Peripheral ossifying fibroma of the maxilla: case report. *Int Arch Otorhino-laryngol.* 2008;12(2):295–304.
4. Jain A, Kadakampally D. Recurrence of peripheral ossifying fibroma: A case report. *People's J Sci Res.* 2010;3(1):24–30. doi:10.17219/dmp/80863.
5. Mathur S, Manjunath SM. Peripheral Ossifying Fibroma: A Review. *Int J Dent Med Res.* 2014;1(4):116–24.
6. Anuradha BR, Penumarty S, Charan CR, Swati M. Application of 810-nm diode laser in the management of peripheral ossifying fibroma. *J Indian Soc Periodontol.* 2015;19(2):224–30.
7. Kranti K, Ashwini S, Pramod N. Excision of Peripheral Ossifying Fibroma Using Diode Laser: A Case Report. *J Dent Orofac Res.* 2017;13(2):66–75.
8. Sultan N, Jafri Z, Sawai M, Daing A. Clinical and histopathological study of four diverse cases of peripheral ossifying fibroma: A case series. *J Interdiscip Dent.* 2019;9(2):89–94. doi:10.4103/jid.jid_18_18.
9. Sairam V, Padmaja K, Praveen KB, Naresh G, Vikas RG. Peripheral Ossifying Fibroma: A Case Report. *Adv Dent & Oral Health.* 2016;1(3):555–65.
10. Ruchi G, Shaleen K, Madhu SR, Mishthu S. Management of massive peripheral ossifying fibroma using diode laser. *J Indian Soc Periodontol.* 2019;23(2):177–80.

Author biography

V. V. Alekhya Burli, Senior Lecturer

B. Adishesamma, Post Graduate Trainee

M. Gayathri, Reader

M. Ramesh Babu, Professor

R. Arpita, Professor and HOD

Cite this article: Alekhya Burli VV, Adishesamma B, Gayathri M, Ramesh Babu M, Arpita R. Diode laser therapy for peripheral ossifying fibroma: A 2 years follow up. *IP Int J Periodontol Implantol* 2022;7(2):83–86.