



## Original Research Article

## Comparison of labial frenectomy procedure with conventional surgical technique and diode laser

Qalbi Fatima<sup>1</sup>, Aaysha Tabinda Nabi<sup>1,\*</sup>, Md. Tarique Naseem<sup>2</sup>, Kumar Anand<sup>3</sup>,  
Abhishek Verma<sup>1</sup>, Anindita Banerjee<sup>1</sup>

<sup>1</sup>Dept. of Periodontology, Buddha Institute of Dental Sciences and Hospital, Patna, Bihar, India

<sup>2</sup>Dept. of Conservative Dentistry and Endodontics, Patna Dental College and Hospital, Patna, Bihar, India

<sup>3</sup>Dept. of Oral Medicine and Radiology, Buddha Institute of Dental Sciences and Hospital, Patna, Bihar, India



## ARTICLE INFO

## Article history:

Received 23-04-2020

Accepted 06-07-2020

Available online 20-10-2020

## Keywords:

Frenectomy

Surgical Scalpel

Diode Laser

## ABSTRACT

**Background :** High frenum is very common in function and esthetics. It is managed by procedure such as frenectomy and frenotomy. Most common is the conventional frenectomy which is done by the use of scalpel, now a day's laser is widely spread and can be used to perform surgeries.

**Aim of the study:** To compare the degree of postoperative pain experienced by patients during frenectomy procedure with surgical scalpel and diode laser technique.

**Materials and Methods:** A total of 20 patients with the age range from 16-40 years old had participated in this study, they were all Systemically healthy, nonsmoker and who required labial frenectomy. That were divided into two groups. Group I includes 10 patients in which frenectomy was done using the diode laser. Group II with 10 patients in which scalpel had been used to perform conventional frenectomy. Parameters such as pain is evaluated at intervals of 1 week, & 1 month.

**Results:** Intergroup comparison of the mean VAS scores for discomfort and pain for both the groups showed significant difference between the groups. Patients treated with the diode laser had less postoperative pain and required fewer analgesics as compared to patients treated with the conventional scalpel technique.

**Conclusion:** Based on this study outcome, the diode laser is a dependable alternative as it is an efficient and satisfactory option for procedures like frenectomy.

© 2020 Published by Innovative Publication. This is an open access article under the CC BY-NC license (<https://creativecommons.org/licenses/by-nc/4.0/>)

### 1. Introduction

Frenectomy or frenulectomy or frenulectomy: Surgical procedure to eliminate the retraction or the movement of marginal gingiva or the interdental papilla by the action of the frenum by excising it. While frenotomy is the incision and the relocation of the frenal attachment.<sup>1</sup>

Plack et al described a morphologic functional classification of labial frenum attachment as follows.

1. Mucosal
2. Gingival
3. Papillary

### 4. Papillapenetrating attachment

Aberrant or high frenum is a problem of inadequate attached gingiva, and mandibular frenum is of no clinical significance if an adequate zone of attached gingiva is present coronal to frenum but maxillary frenum may present asthenic problems or compromised orthodontic results. Two methods to check abnormal frenum attachment are as follows:

1. Tension test: Lip is moved outward, upwards for the upper, and downwards for the lower and also moved sideways. If the marginal and oblique or interdental papilla moves away from the tooth surface, then the tension test is said to be positive

\* Corresponding author.

E-mail address: [draayesha345@gmail.com](mailto:draayesha345@gmail.com) (A. T. Nabi).

2. Blanch test: It is performed to diagnose a fleshy labial frenum. It is done by pulling the upper Lip outwards. Presence of thick and fleshy frenum is confirmed by the blanching of the incisive papilla region.

### 1.1. Associate problems

1. Abnormal labial frenum can cause midline diastema
2. Tension on the frenum may tend to open the sulcus
3. Frenum that encroaches the margin of the gingiva may interfere with plaque removal

### 1.2. Indications

1. In case of high frenul attachment
2. To prevent midline diastema
3. To prevent pocket formation
4. To prevent the injury while brushing
5. To prevent accumulation of irritants
6. To prevent its interference with post-treatment healing
7. To prevent recession

### 1.3. Procedures

1. Simple excision of frenum
2. Z-Plasty
3. Localized vestibuloplasty with secondary epithelization is done when frenul attachment has a wide base

Frenectomy can be done by conventional scalpel technique or soft tissue lasers.<sup>2</sup> There are various types of laser that are used in dentistry, including neodymium doped yttrium aluminium garnet (Nd:YAG), diode, carbon dioxide (CO<sub>2</sub>), erbium YAG (Er:YAG) and erbium, chromium:yttrium:scandium gallium-garnet (Er,Cr:YSGG) lasers.<sup>3</sup> Each emits light at a specific wavelength that is determined by the gain medium (solid, liquid or gas).<sup>4</sup> The Nd:YAG laser is a free-running pulsed laser that has a 1064-nm wavelength and is highly absorbed in melanin, less absorbed in haemoglobin, and slightly absorbed in water.<sup>5</sup>

Laser application in periodontics such as frenectomies, excision of gingival enlargement, gingivoplasties, gingival dipigmentation, operculum removal crown lengthening and biopsies of benign lesions are indicated for the laser treatment.<sup>6-9</sup>

Advantage, of the laser during surgery are less pain, minimal bleeding, better visualization, minimal or no anesthesia, less damage to the adjacent tissues, and reduced risk of blood-borne transmission of disease. And advantages after surgery are less scarring, faster healing of the operation, minimum post operative pain and reduced risk of post operative infection.<sup>10</sup>

## 2. Aims & Objectives

The aim of the present study was to compare the degree of postoperative pain experienced by patients in frenectomy procedure with surgical scalpel and diode laser technique.

## 3. Materials and Methods

20 subject with an age range from 16-40 years old had participated in this study, there were all Systemically healthy, nonsmoker, good oral hygiene and who required labial frenulectomy were selected from the Out Patient Department of Periodontics, Buddha Institute of Dental Sciences & Hospital, Patna.

Informed written consent was obtained from the patients. The patients were divided randomly into Group I and II

1. Group I: Comprised of 10 patients selected for conventional scalpel technique
2. Group II : Comprised of 10 patients selected for diode Laser technique.

All the procedures were carried out by a single operator. For the conventional classical technique or scalpel technique proposed by Archer (1961) and as modified by Krugger (1964) was followed. The area was anesthetized with 2% lignocaine with 1:80,000 adrenaline. The frenum was held with a pair of hemostats, and the whole band of tissue together with its alveolar attachment was excised with a#15 blade. After freeing any remaining fibrous adhesions to the underlying periosteum, the wound was closed with 3'0 silk interrupted sutures. For the diode laser technique, the area was anesthetized with 2% lignocaine with 1:80,000 adrenaline. A diode laser 810 nm wavelength at power setting of 0.8 - 1.2 W made of fiber tip of diameter 300 $\mu$ -400  $\mu$  was used in a contact mode and moved, in a paint brush stroke, from the base to the apex of the frenum there by excising it. Any remnant fibers over the periosteum were removed by gently sweeping the laser tip and the ablated remnant tissue was cleaned with gauze soaked in saline. Sutures were not given post the laser treatment. Both groups received postoperative instructions and the use of any analgesic was left to the patient's discretion.

## 4. Method of scoring

The patients were asked to rate the degree of pain during eating or speech, on a 10cm horizontal visual analog scale (VAS) by placing a vertical mark to assess position between the two endpoints. The left end point was nominated as "no pain," and the right end point was nominated as "unbearable pain." A single trained operator was engaged in recording the scores.

On the 7th day swelling, wound healing

1. Complete epithelization,
2. Incomplete epithelialization,

3. Ulcer,
4. Tissue defect or necrosis), and number of analgesics used were assessed. After 1<sup>st</sup>, 3rd and 7th day and after one month re evaluation of post operative pain was performed using same indices<sup>11</sup> for both the groups.

## 5. Results

A total of 20 patients, (10 females and 10 males) completed the study. Comparison of the mean VAS score of the level of pain, for both groups, observed on the 1<sup>st</sup>, 3rd and 7th day of the study is summarized in (Figures 1, 2 and 3). The analysis showed that VAS scores of pain on day 1, 3 and 7 were significantly lower in the laser group compared to the conventional technique. Number of analgesics used by Group I were significantly higher than Group II.

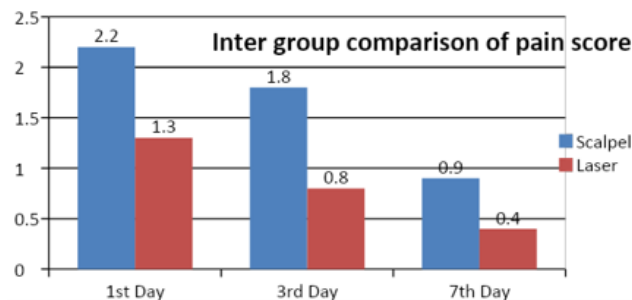


Fig. 1:

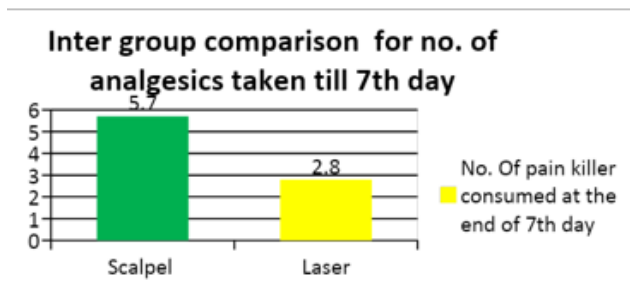


Fig. 2:

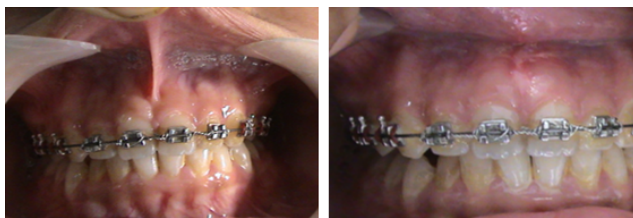

Fig. 3:

## 6. Discussion

Periodontal plastic surgery is more conservative and precise technique that is practiced for the treatment of mucogingival problems. These are being practised to create more functional and aesthetic results. The presence of an aberrant frenum being one of the etiological factors for the persistence of a midline diastema and periodontal problems need greater attention. The aberrant frenum can be treated by frenectomy or by frenotomy procedures.<sup>6,11</sup> The soft tissue laser is now a viable alternative to the scalpel in soft tissue surgery. Lasers such as Nd:YAG, CO<sub>2</sub>, and Er:YAG have been used for frenectomy procedures. Among these, CO<sub>2</sub> laser is the one most frequently used.<sup>6,12</sup> In the present study, diode laser, which characteristically uses a blend of gallium, arsenide, and other elements such as aluminum and indium, was used. The diode laser is now a viable alternative to the scalpel in soft tissue surgery. The wavelength of this laser is feebly absorbed in water, but extremely absorbed in hemoglobin and other pigments. Diode laser is considered as an excellent soft tissue laser as it doesn't interact with dental hard tissues and considering the affinity of the diode laser for wet tissue, it is readily applicable for most intraoral soft tissue surgery, including frenectomies.<sup>13,14</sup> In the present study, patients treated with the diode laser had significantly less postoperative pain both on day 1, day 3 and day 7 as compared to scalpel surgery as well as number of analgesics used were lower in the laser group. These findings are consistent with the other studies by Flaytac et al.<sup>2</sup> Butchibabu et al.<sup>14</sup> and Patel et al.<sup>15</sup> wherein they suggested that soft tissue laser treatment used for frenectomy provides better patient perception in terms of postoperative pain and function than that obtained by the scalpel technique. The laser technique offers some advantages, such as a relatively bloodless surgical and post surgical event, the ability to precisely coagulate, vaporize, or cut tissue; sterilization of the wound site, minimal swelling and scarring, no suturing in most cases, little mechanical trauma, reduction of surgical time, decreased post surgical pain; and high patient acceptance.<sup>16,17</sup> The increased pain perception associated with the scalpel frenectomy might be attributed to the fact that it is a more intrusive surgical procedure involving blood loss, wide surgical wound and suturing. The sutures also contribute to the discomfort postoperatively since they interfere with regular functions such as speech and intake of food. In addition, suture removal from gingival and labial tissues after 1 week can be painful because the sutures may be buried in the mucosa.<sup>11</sup> To overcome these disadvantages, some clinicians use bio absorbable sutures after oral surgery.

## 7. Conclusion

In the present study diode laser frenectomy has presented with less post operative pain and discomfort and poor

healing compared to conventional scalpel frenectomy. The increased pain in patients with scalpel technique could be attributed to the fact that it is a more intrusive procedure, wide surgical wound and suturing. The sutures could also contribute to discomfort.

## 8. Source of Funding

None.

## 9. Conflict of Interest

None.

## References

- Dibart S, Karima M. Labial frenectomy alone or in combination with a free gingival autograft. Practical Periodontal Plastic Surgery. Germany: Blackwell Munksgaard; p. 53.
- Haytac MC, Ozcelik O. Evaluation of Patient Perceptions After Frenectomy Operations: A Comparison of Carbon Dioxide Laser and Scalpel Techniques. *J Periodontol.* 2006;77(11):1815–9.
- Newman MG, Takei H, Klokkevold PR, Carranza FA. Carranza's Clinical Periodontology. Elsevier; 2012.
- Akpınar A. Postoperative discomfort after Nd:YAG laser and conventional frenectomy: comparison of both genders. *Australian Dent J.* 2016;61:71–5.
- Mittal R, Sriram S, Sandhu K. Evaluation of long-pulsed 1064 nm Nd:YAG laser-assisted hair removal vs multiple treatment sessions and different hair types in Indian patients. *J Cutan Aesthet Surg.* 2008;1(2):75–9.
- Pick RM, Colvard MD. Current Status of Lasers in Soft Tissue Dental Surgery. *J Periodontol.* 1993;64(7):589–602.
- Slot DE, Kranendonk AA, Paraskevas S, der Weijden FV. The Effect of a Pulsed Nd:YAG Laser in Non-Surgical Periodontal Therapy. *J Periodontol.* 2009;80(7):1041–56.
- White JM, Goodis HE, Rose CL. Use of the pulsed Nd:YAG laser for intraoral soft tissue surgery. *Lasers Surg Med.* 1991;11(5):455–61.
- Kara C. Evaluation of patient perceptions of frenectomy: a comparison of Nd:YAG laser and conventional techniques. *Photomed Laser Surg.* 2008;26:147–52.
- Gomez C, Costela A, Garcia-Moreno I, Garcia JA. In vitro evaluation of Nd:YAG laser radiation at three different wavelengths (1064, 532 and 355 nm) on calculus removal in comparison with ultrasonic scaling. *Photomed Laser Surg.* 2006;24:366–76.
- Fiorotti RC, Bertolini MM, Nicola JH, Nicola EM. Early lingual frenectomy assisted by CO2 laser helps prevention and treatment of functional alterations caused by ankyloglossia. *Int J Orofacial Myol.* 2004;30:64–71.
- Matthews DC, McCulloch CAG. Evaluating Patient Perceptions as Short-Term Outcomes of Periodontal Treatment: A Comparison of Surgical and Non-Surgical Therapy. *J Periodontol.* 1993;64(10):990–7.
- Esen E, Haytac MC, Öz İA, Erdoğan Ö, Karsli ED. Gingival melanin pigmentation and its treatment with the CO2 laser. *Oral Surg Oral Med Oral Pathol Oral Radiol Endod.* 2004;98:522–7.
- Butchibabu K, Koppolu P, Mishra A, Pandey R, Swapna LA, Uppada UK, et al. Evaluation of patient perceptions after labial frenectomy procedure: A comparison of diode laser and scalpel techniques. *Eur J General Dent.* 2014;3(2):129–33.
- Patel RM, Varma S, Suragimath G, Abbayya K, Zope SA, Kale V, et al. Comparison of labial frenectomy procedure with conventional surgical technique and diode laser. *J Dent Lasers.* 2015;9(2):94–9.
- Lasers in periodontics (position paper). *American Academy of Periodontology.* 2002;73:1231–9.
- Schuller DE. Use of the Laser in the Oral Cavity. *Otolaryngol Clin North Am.* 1990;23(1):31–42.

## Author biography

**Qalbi Fatima** Post Graduate Student

**Aaysha Tabinda Nabi** Reader

**Md. Tarique Naseem** Tutor

**Kumar Anand** Reader

**Abhishek Verma** Professor

**Anindita Banerjee** Professor and Head

**Cite this article:** Fatima Q, Nabi AT, Naseem MT, Anand K, Verma A, Banerjee A. **Comparison of labial frenectomy procedure with conventional surgical technique and diode laser.** *IP Int J Periodontol Implantol* 2020;5(3):120-123.