



Case Report

Management of pyogenic granuloma in pediatric patients using electrocautery– Case reports

Mohammed Ahsan Razi^{1,*}, Surangama Debnath¹, Seema Qamar², Akash Tripathi¹

¹Dept. of Periodontology, Hazaribag College of Dental Sciences and Hospital, Demotand, Hazaribag, Jharkhand, India

²Dept. of Pediatric and Preventive Dentistry, Hazaribag College of Dental Sciences and Hospital, Demotand, Hazaribag, Jharkhand, India



ARTICLE INFO

Article history:

Received 31/10/2019

Accepted 29/11/2019

Available online 07-01-2020

Keywords:

Pyogenic granuloma

Gingival hyperplasia

Hyperactive lesion

ABSTRACT

The oral pyogenic granuloma, a tumor-like growth is a non-specific infection and considered being non-neoplastic in nature with various clinical and histopathological forms. It occurs mainly in the second decade of life in young individuals and rarely causes significant alveolar bone loss. The present article describes the management of pyogenic granuloma by electrosurgery in a 10-year-old male child and an 11-year-old female child.

© 2019 Published by Innovative Publication. This is an open access article under the CC BY-NC-ND license (<https://creativecommons.org/licenses/by/4.0/>)

1. Introduction

First reported by Hüllihen's in 1844,¹ the pyogenic granuloma (*granuloma pediculatum benignum*, pregnancy tumor or benign vascular tumor) is a reactive localized hyperplastic lesion of the soft tissues. In 1904, the term "pyogenic granuloma" was coined by Hartzell.² It is also known by other names viz. Hwmangiomas granuloma (by Angelopoulos AP)³ and Crocker and Hartzell's disease (by Hartzell).² It is the most frequent (75% of the cases) gingival tumor in the oral cavity,⁴ being more common on the maxillary gingiva than the mandibular gingiva.^{5–7} Furthermore, these lesions are comparatively more common on the facial aspect of the gingiva than the lingual aspect.⁶ The word 'pyogenic granuloma' is a misnomer because it lacks pus and is not a granuloma in *sensu stricto*.⁸ Investigators usually consider chronic low-grade irritation,^{6,7} hormonal factors,⁹ and certain drugs¹⁰ as causative factors for pyogenic granuloma.

In the present communication, we report two cases of pyogenic granuloma of the gingiva; one located in maxillary

buccal area in a ten-year-old male child suffering from arteriovenous (AV) malformation of the upper left lip, and another one located in the lingual side of mandibular anteriors in an eleven-year-old female child.

2. Case History

2.1. Case report 1

A 10-year-old male child with a complaint of swelling in the upper front and left back region of the jaw for seven months, which caused discomfort while eating, reported to the Department of Periodontology. After recording the detailed case history of the patient, it was revealed that the lesion was slow-growing and painless, but caused pain while chewing.

On extraoral examination, the swelling was present on the left upper lip region, which was non-pulsatile and was compressible. [Figure 1] On intraoral examination, a solitary lobulated reddish gingival swelling extending on the buccal surface of 22, 23, 24, and 65 teeth were revealed. The lesion was ovoidal in shape, soft in consistency with a smooth surface that measured 17 mm x 8 mm. [Figure 2] The lesion extended beyond the occlusal plane of the teeth

* Corresponding author.

E-mail address: mahsan0708@gmail.com (M. A. Razi).

giving an appearance of missing teeth.[Figure 3] Lymph node involvement was seen in sub-mandibular regions. Radiographically, there was no alveolar bone loss in the area of growth.[Figure 4]

MRI (Magnetic Resonance Imaging) examination of upper lip revealed multiple linear serpiginous flow void structures noted scattered in the pre-maxillary region having derivatives from buccal artery, suggestive of AV malformation. MRI examination of the lesion revealed approximately 17mm x 8 mm sized T2 – hyperintense and T1- isointense lesions noted anterior to the left maxilla. The lesion was precisely located between left lateral incisors and canine and was seen as a focal outpouching into the pre- maxillary space. The lesion did not exhibit flow voids. The lesion showed intense enhancement on the post-contrast study, and no apparent bone erosion was seen.

Based on the clinical presentation of the lesion, the provisional diagnosis of pyogenic granuloma was made. The differential diagnosis included hemangioma, fibroma, peripheral ossifying fibroma, and peripheral giant cell granuloma.

Based on clinical and MRI evidence, surgical excision of the lesion was planned, and the treatment and outcome of the surgery were well explained to the patient and his accompanying father and mother. The subject being minor, the consent for surgery was obtained from his father. Before excision of the lesion, a complete hematological investigation of the patient was done. The bleeding time, clotting time, hemoglobin percentage, and total and differential leukocyte counts were within normal limits.

Full mouth oral prophylaxis was performed. Excisional biopsy was executed using electrocautery, under infiltration of local anesthesia with adrenaline (1:100,000). [Figure 5] The excised specimen[Figure 6] was fixed in 10% formalin and was submitted to the department of oral pathology for histopathological analysis. Follow up examination after a week and six months was done to confirm uneventful healing and any recurrence. [Figures 7 and 8]

The histopathological analysis of the excised lesion showed stratified squamous para keratinized atrophic epithelium with moderate intense infiltration of polymorphonuclear leukocytes, lymphocytes, and plasma cells. Connective tissue comprised of the vast number of endothelium lined vascular spaces and extreme proliferation of fibroblast and also budding endothelial cells. The stroma was typically delicate, although fascicle of collagen fibers are noted coursing through the tissue. These features confirmed that the excised lesion was a pyogenic granuloma. [Figure 9]

2.2. Case report - 2

An 11-year-old female patient reported to the department of Pediatric and preventive dentistry, with a complaint of swelling below the tongue in the lower front teeth region for

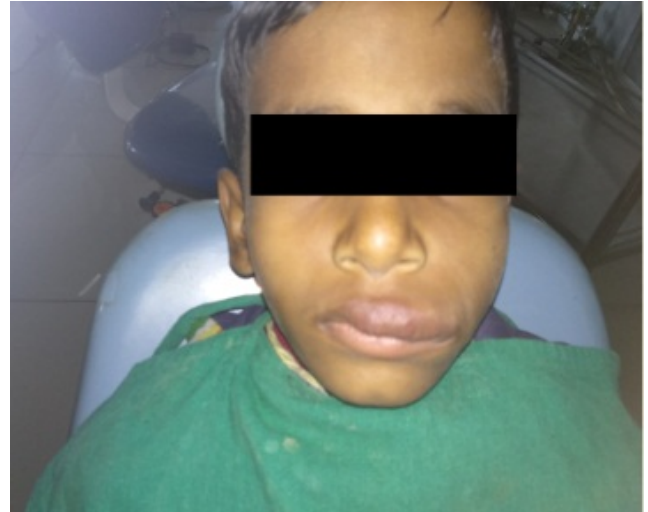

Fig. 1: Extra oral view showing swelling of left lips

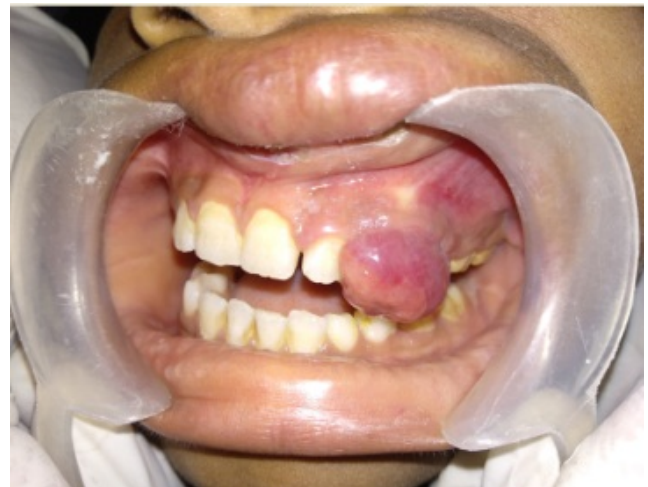

Fig. 2: Intra oral view- lesion on buccal aspect

eight months. After recording the detailed case history of the patient, it was revealed that the lesion was slow growing but had grown rapidly to the present size over a duration of only four weeks.

Intra-oral examination revealed a spherical-shaped, exophytic, solitary, pedunculated, reddish-pink lesion with definite borders [Figure 10]. The lesion was located in the lingual side of the lower anterior teeth and measured approximately 12 mm x 8 mm in size. The lesion was soft and firm in consistency, non-tender, and got blanched when pressure was applied. An intraoral periapical radiograph showed the bone loss in the area of the lesion. [Figure 11]

Based on the clinical presentation of the lesion, the provisional diagnosis of pyogenic granuloma was made. The differential diagnosis was capillary hemangioma, fibroma, and peripheral giant cell granuloma.

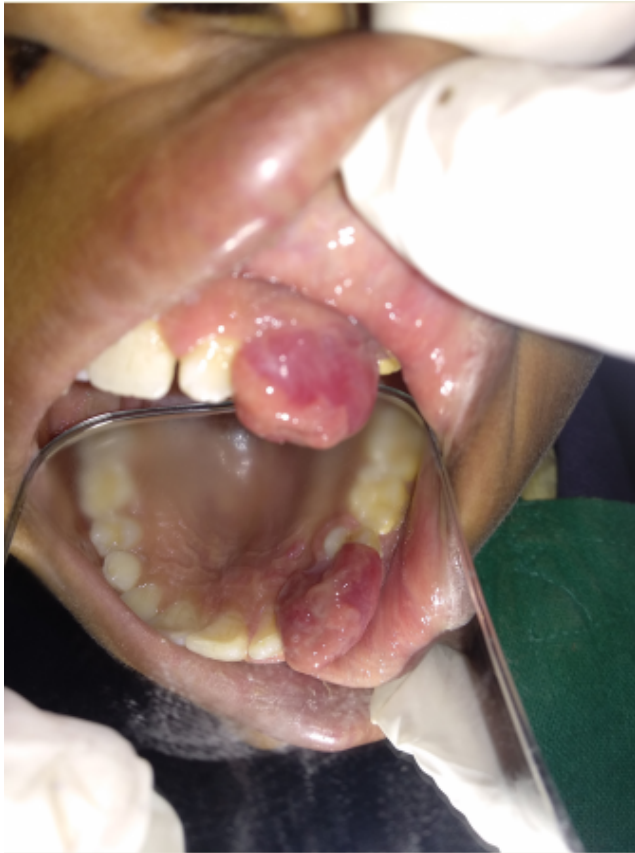

Fig. 3: Intra oral view – showing extension of lesion in occlusal surface

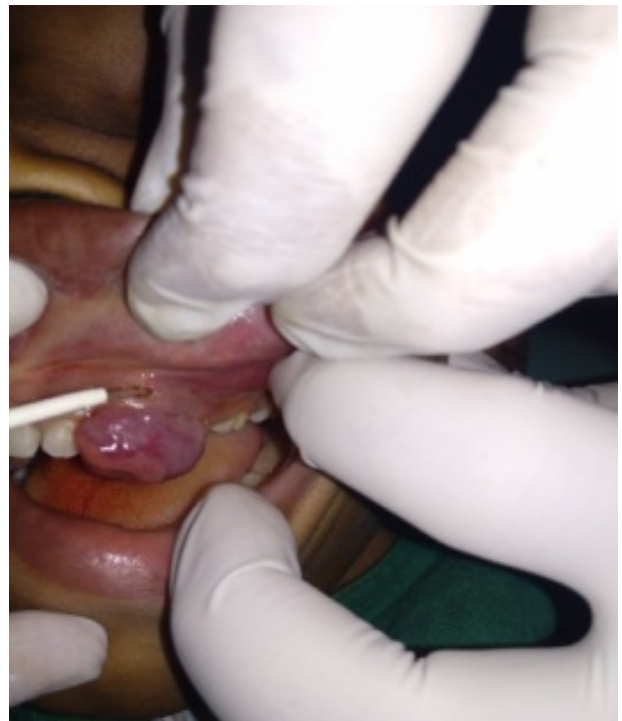

Fig. 5: Intra-operative view

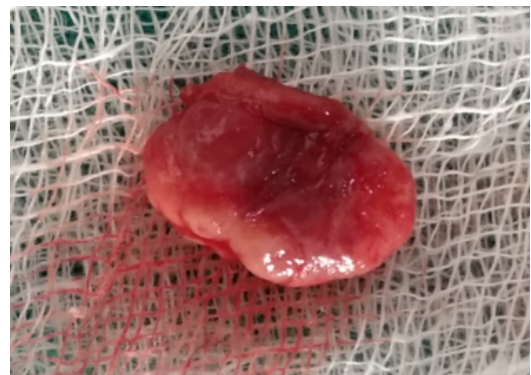


Fig. 6: Excised lesion

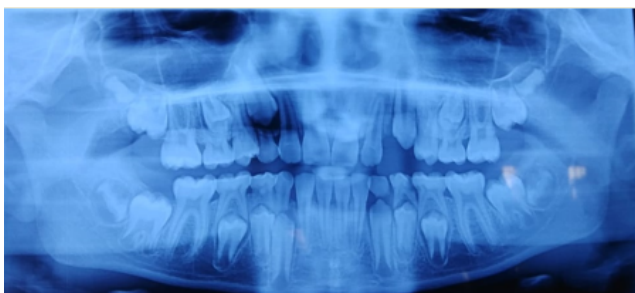


Fig. 4: Orthopantomogram (OPG) showing presence of teeth and no bone loss

Based on clinical evidence, surgical excision of the lesion was planned, and the treatment and outcome of the surgery were well explained to the patient and her accompanying father. The subject being minor, the consent for surgery was obtained from her father. Before excision of the lesion, a complete hematological investigation of the patient was done. The bleeding time, clotting time, hemoglobin percentage, and total and differential leukocyte counts were within normal limits.

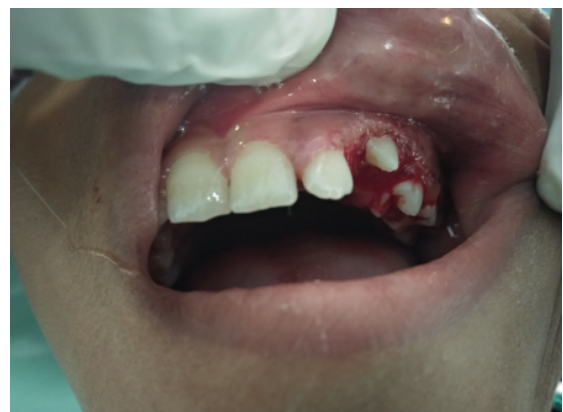

Fig. 7: Immediate post operative view

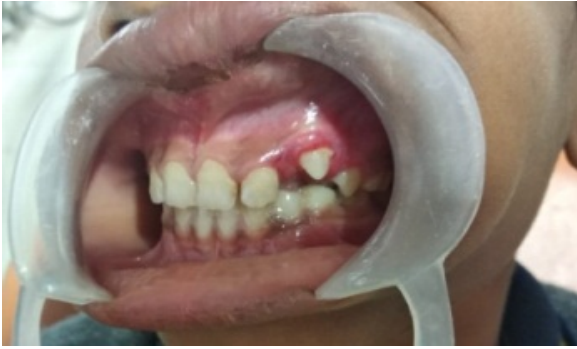

Fig. 8: Post operative view after six months

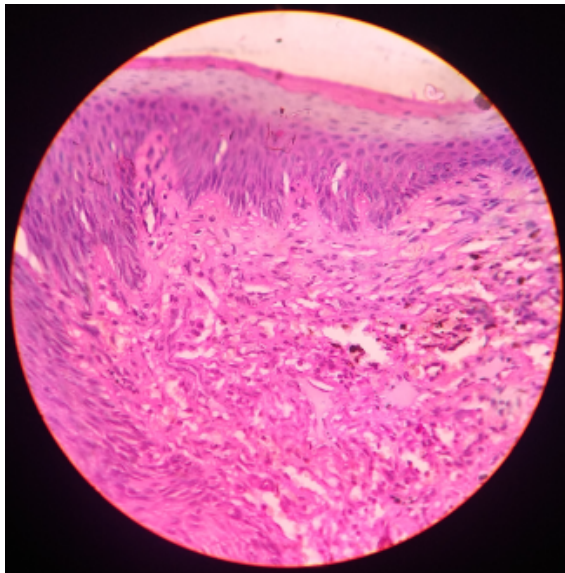


Fig. 9: H & E stained histological section (10X) showing stratified squamous para keratinized atrophic epithelium with moderate intense infiltration of inflammatory cells & extreme proliferation of fibroblast and budding endothelial cells

Oral prophylaxis was done, and excisional biopsy was executed using the electrocautery, under infiltration of local anesthesia with adrenaline (1:100,000). The excised specimen [Figure 12] was fixed in 10% formalin and was submitted to the department of oral pathology for histopathological analysis. Follow up examination after a week and six months was done to confirm uneventful healing and any recurrence. [Figures 13 and 14]

The histopathological analysis of the excised lesion showed stratified squamous para keratinized atrophic epithelium with moderate intense infiltration of inflammatory cells. Connective tissue revealed numerous endothelium lined vascular spaces and extreme proliferation of fibroblast and budding endothelial cells. These histopathological features confirmed that the excised lesion was a pyogenic granuloma. [Figure 15]

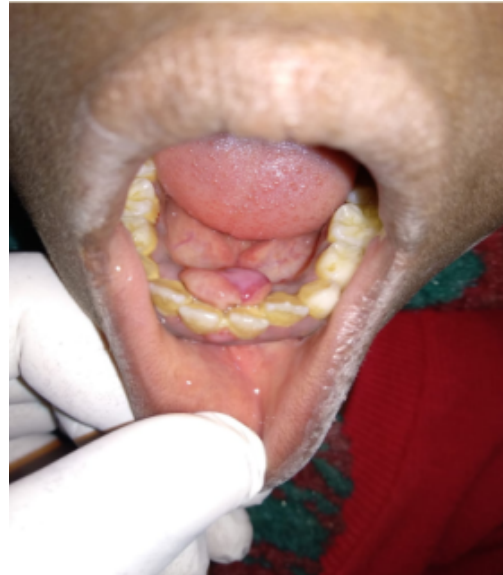

Fig. 10: Intra-oral view – lesion on lingual aspect



Fig. 11: Intraoral periapical (IOPA) radiograph showing bone loss i.r.t. 11 and 12

3. Discussion

The occurrence of oral pyogenic granuloma is reported in persons of all age groups. However, it is regularly encountered in females in their second decade of life mainly due to elevated levels of estrogen and progesterone hormones.¹¹ Regezi *et al.*, suggested that a known irritant or injury such as calculus, overhanging restorations, due to the exuberant proliferation of connective tissue or foreign material within the gingival crevice may also cause pyogenic granuloma.⁷ Aberrant tooth development,¹²

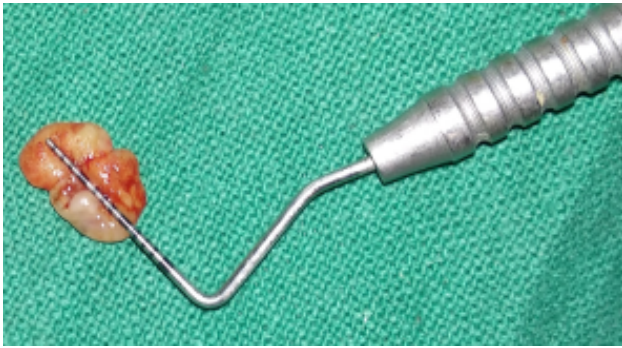


Fig. 12: Excised lesion

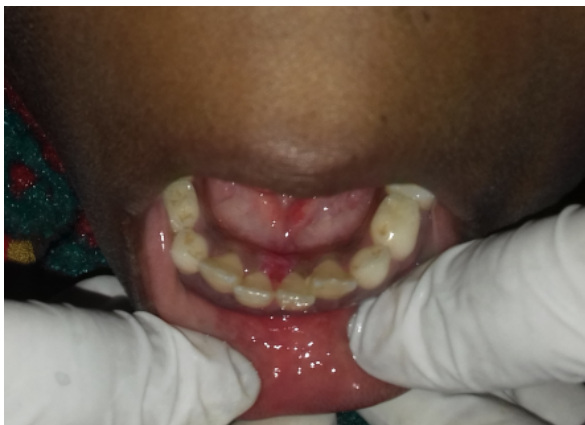

Fig. 13: Immediate post operative view

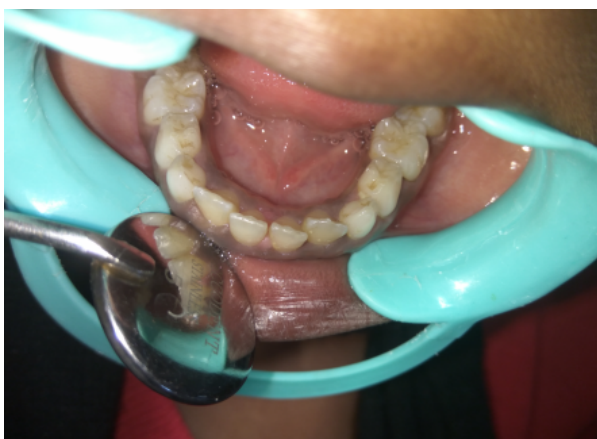

Fig. 14: Post operative view after six months

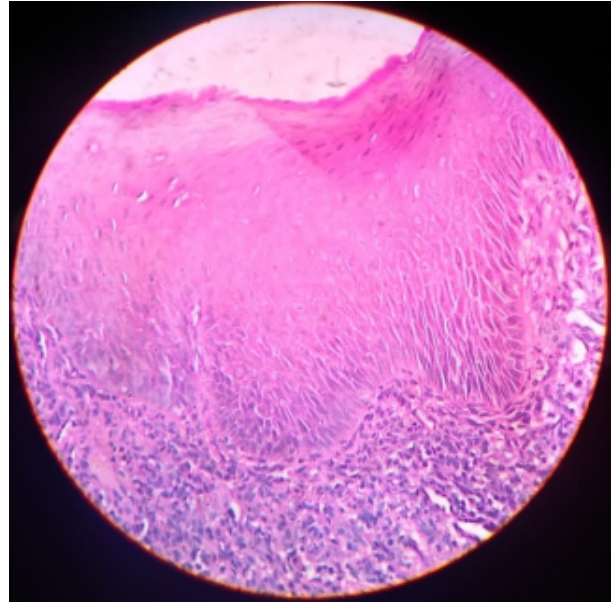


Fig. 15: H & E stained histological section (10X) showing stratified squamous para keratinized atrophic epithelium with moderate intense infiltration of inflammatory cells & extreme proliferation of fibroblast and budding endothelial cells

occlusal interferences,¹³ trauma to deciduous teeth and release of a variety of angiogenic factors and endogenous substances disrupts the vascularity of the affected area,¹⁴ are the other predisposing factors for pyogenic granuloma.

Clinically, pyogenic granuloma generally represents smooth or lobulated exophytic lesion with a sessile or pedunculated base. These lesions may grow rapidly and attain a larger size. It grows from a few millimeters to several centimeters in dimension but seldom surmounts more than 2.5 cm.¹⁵ Commonly radiographic findings are absent,¹⁶ but in the present case report-2, a significant bone loss could be seen. [Figure 11] This substantiates the findings of Angelopoulos who reported that localized alveolar bone resorption occurred in some cases of long-standing gingival pyogenic granulomas.³

In the present cases, full mouth scaling was done to remove all the local irritants, which could have been the primary etiologic factors.⁷ The lesion was surgically excised (with electrocautery in both cases) and was sent for histopathological examination.

Recurrence of these lesions is due to inadequate removal of etiological factors, repeated trauma, or failure to maintain oral hygiene.⁷ Vilmann *et al.*,¹⁷ emphasized that there is a need for followup, especially in pyogenic granuloma of the gingiva due to its higher recurrence rate. The present cases were followed up for a period of 6 months, and no recurrence was observed.

4. Conclusions

Although pyogenic granuloma arises due to a combination of etiological factors and is non-neoplastic in origin, removal of irritants like plaque, calculus, overhanging restorations, and other foreign substance is a must. Surgical excision of the lesion *in toto* is the treatment of choice for pyogenic granuloma. Proper oral hygiene maintenance is utmost essential to avoid any chance of recurrence. We describe here the cases of gingival pyogenic granuloma in a 10-year-old male and in an 11-year-old female patients with clinical features, treatment plan, histopathological features, and follow up for six months. Though the term "pyogenic granuloma" is commonly used, it is not associated with pus or granuloma formation and rather histologically resembles with an angiomatic lesion which shows that the term 'pyogenic granuloma' is a misnomer. This benign lesion is commonly encountered and excised in day to day dental practice. Therefore, it is utmost necessary to recognize these lesion to avoid misdiagnosis, and it is always advocated to get histopathological confirmation, owing to its close clinical resemblance to neoplastic condition.

5. Source of funding

None

6. Conflict of interest

None

References

- Hullihen SP. Case of aneurism by anastomosis of the superior maxillae. *Am J Dent Sci.* 1844;4:160-162.
- Hartzell MB. Granuloma pyogenicum. *J Cutan Dis Syph.* 1904;22:520-525.
- Angelopoulos A. Pyogenic granuloma of the oral cavity: Statistical analysis of its clinical features. *J Oral Surg.* 1971;29:840-847.
- Sternberg SS, Antonioli DA, Carter D, Mills SE, Oberman H. *Diagnostic Surgical Pathology.* vol. 74. Philadelphia: Lippincot Williams and Wilkins ; 1999,. p. 169-174.
- Eversole LR. Clinical Outline of Oral Pathology. In: *Diagnosis and Treatment.* Hamilton: BC Decker ; 2002,. p. 113-114.
- Neville BW, Damm DD, Allen CM, Bouquot JE. *Oral and Maxillofacial Surgery.* Philadelphia: Saunders ; 2002,. p. 447-449.
- Regezi JA, Sciubba JJ, Jordan RC. *Oral Pathology: Clinical Pathological Considerations.* Philadelphia: WB Saunders ; 2003,. p. 115-116.
- Bhaskar SN, Jacoway JR. Pyogenic granuloma - Clinical features, incidence, histology, and result of treatment: Report of 242 cases. *J Oral Surg.* 1966;24:391-398.
- Mussalli NG, Hopps RM, Johnson NW. Oral pyogenic granuloma as a complication of pregnancy and the use of hormonal contraceptives. *Int J Gynaecol Obstet.* 1976;14:187-191.
- Miller RA, Ross JB, Martin J. Multiple granulation tissue lesions occurring in isotretinoin treatment of acne vulgaris- successful response to topical corticosteroid therapy. *J Am Acad Dermatol.* 1985;12:888-889.
- Ojanotko AH, Harri MP, Hurttia MH, Sewon LA. Altered tissue metabolism of progesterone in pregnancy gingivitis and granuloma. *J Clin Periodontol.* 1991;18:262-266.
- Milano M, Flaitz CM, Bennett J. Pyogenic granuloma associated with aberrant tooth development. *Tex Dent J.* 2001;118:166-172.
- Widowati W, Ban T, Shareff A. Epulis and pyogenic granuloma with occlusal interference. *Maj Ked Gigi.* 2005;38:52-55.
- Aguilo L. Pyogenic granuloma subsequent to injury of a primary tooth. A case report. *Int J Paediatr Dent.* 2002;12:438-441.
- Parisi E, Glick P, Glick M. Recurrent intraoral pyogenic granuloma with satellitosis treated with corticosteroids. *Oral Dis.* 2006;12:70-72.
- Kamal R, Dahiya P, Puri A. Oral pyogenic granuloma: Various concepts of etiopathogenesis. *J Oral Maxillofac Pathol.* 2012;16:79-82.
- Vilmann A, Vilmann P, Vilmann H. Pyogenic granuloma: Evaluation of oral conditions. *Br J Oral Maxillofac Surg.* 1986;24:376-382.

Author biography

Mohammed Ahsan Razi Postgraduate Student

Surangama Debnath Professor and Head of Department

Seema Qamar Postgraduate Student

Akash Tripathi Senior Lecturer

Cite this article: Razi MA, Debnath S, Qamar S, Tripathi A. Management of pyogenic granuloma in pediatric patients using electrocautery- Case reports. *Int J Periodontol Implantol* 2019;4(4):141-146.